

# Asymptomatic double aortic arch

Muzaffer Sariaydin<sup>1</sup>  
Serhat Findik<sup>1</sup>  
Atilla Guven Atici<sup>1</sup>  
Sevket Ozkaya<sup>2</sup>  
Aziz Uluisik<sup>1</sup>

<sup>1</sup>Department of Pulmonary Medicine,  
Faculty of Medicine, Ondokuz Mayıs  
University, Samsun, Turkey;

<sup>2</sup>Department of Pulmonary Medicine,  
Faculty of Medicine, Rize University,  
Rize, Turkey

**Abstract:** A 51-year-old male patient with a past history of lung tuberculosis was referred to our clinic for routine control. The patient reported no complaints and chest X-ray was normal. Three-dimensional thoracic computed tomography revealed a balanced-type double aortic arch with no compression of trachea or esophagus.

**Keywords:** double aortic arch, asymptomatic, adult, three dimensional computed tomography

Vascular rings, which constitute less than 1% of the congenital heart diseases, were first identified by Gross in 1945.<sup>1</sup> Double aortic arch (DAA) is the most frequent form of vascular rings. DAA may surround trachea and esophagus and, thus, may cause compression of these structures. If the compression is severe, symptoms such as dyspnea, recurrent pneumonia, stridor, dysphagia, and feeding difficulties may be observed at birth. However, when compression is minimal, DAA can remain undiagnosed until adulthood.<sup>2</sup> We report an asymptomatic case with a DAA in whom anatomical boundaries and branches of DAA were clearly demonstrated using three dimensional computed tomography (CT).

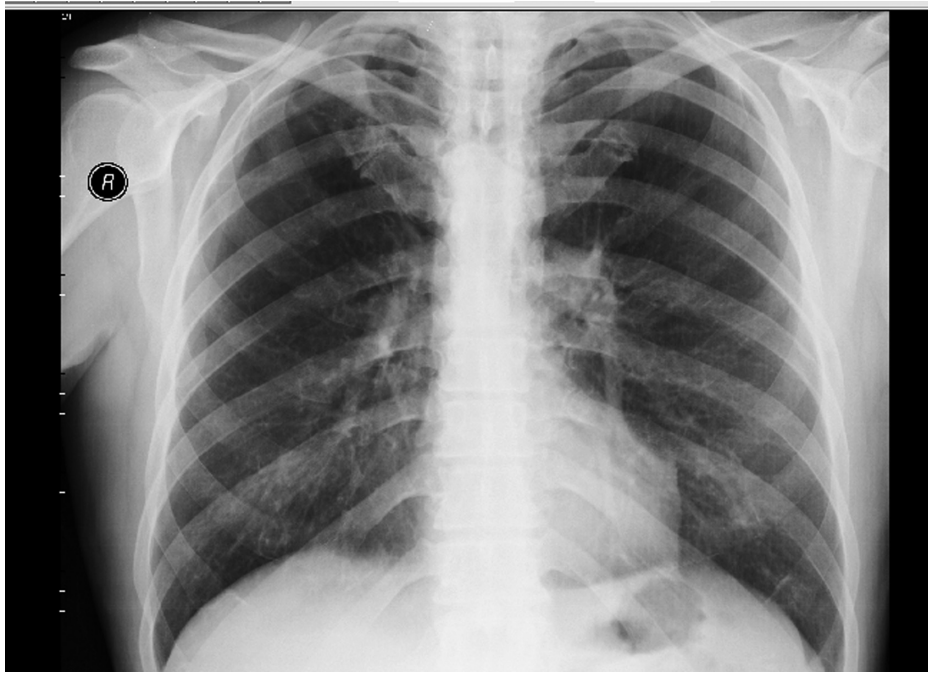## Case report

A 51-year-old male patient with a past history of lung tuberculosis presented for routine control. The patient reported no complaints. He smoked 40 packets of cigarettes per year and had suffered from tuberculosis 20 years ago and had been treated. Physical examination and laboratory findings were within normal limits; chest X-ray showed bilateral hyperlucency (Figure 1). Chest CT revealed DAA surrounding the trachea on both sides. Left and right arches were equal in size although the right arch was located 5 mm higher than the left (Figure 2). A three-dimensional CT scan was taken (1) to obtain better anatomic views and (2) to clearly identify its relation to neighboring structures (Figure 3). These images show clearly that the DAA is a balanced type and there is no compression of either trachea or esophagus. Echocardiography was normal. Bronchoscopy was not performed due to lack of respiratory symptoms.

## Discussion

The embryonic development of vascular ring has been explained in detail in literature.<sup>3</sup> There are six pairs of aortic arches that originate from the ventral aortic root in embryonic arch system. The first, second, and fifth primitive arches regress and form

Correspondence: Serhat Findik  
Department of Pulmonary Medicine,  
Faculty of Medicine, Ondokuz Mayıs  
University, TR-55139 Atakum,  
Samsun, Turkey  
Email serhatfindik@yahoo.com

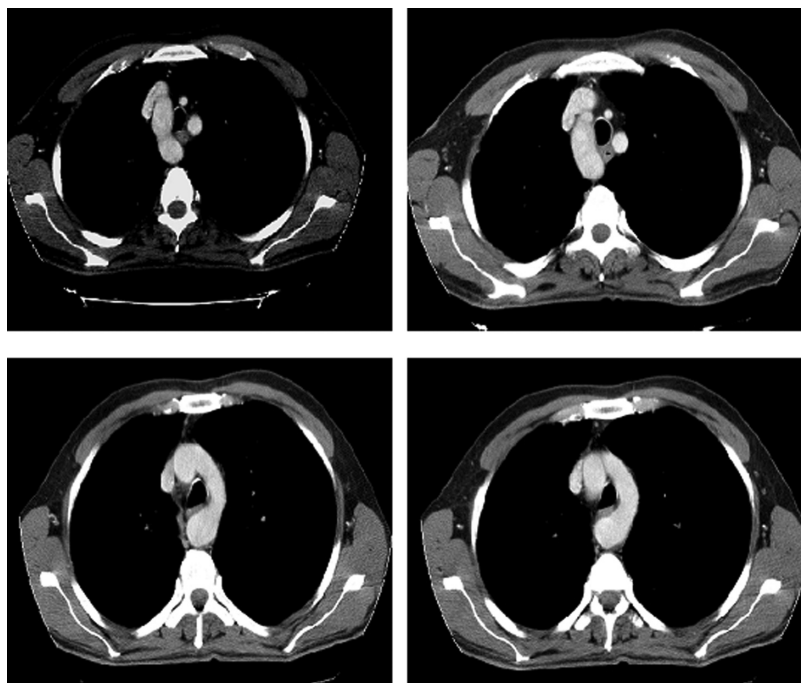


**Figure 1** Bilateral hyperlucency is visible in this X-ray.

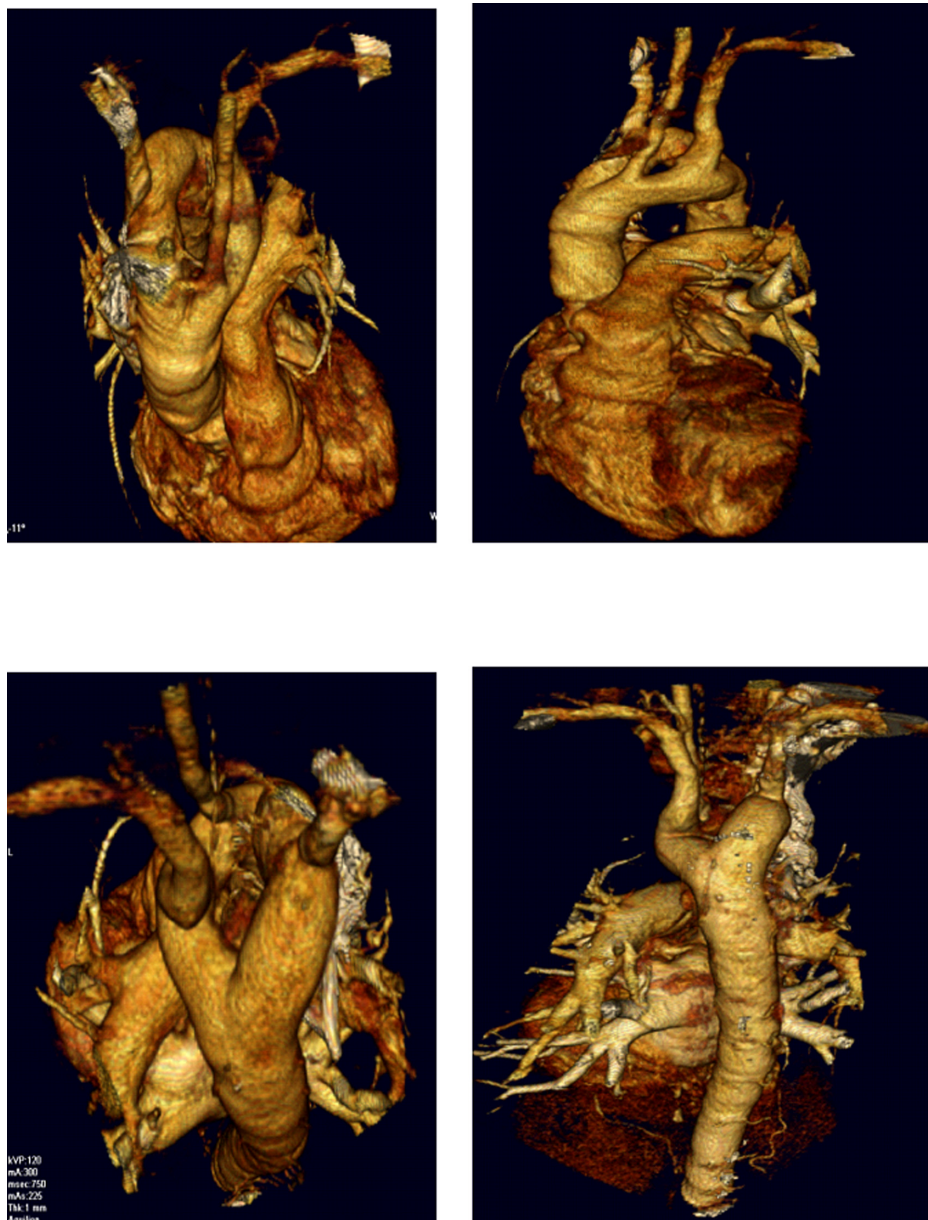
a double aortic arch. Normally, the left fourth arch regresses and forms the aortic arch. If the left fourth arch regresses and the right arch remains, this will result in a right-sided aortic arch.<sup>3,4</sup> Classically, DAA has three types; right dominant aortic arch, left dominant aortic arch, and balanced-type aortic arch. In 75% of the cases, the right arch is dominant and in

approximately 20% of the cases, the left arch is dominant. In 5% of the cases the dominance of both arches is equal.<sup>5</sup>

Our case study patient had a balanced type of aortic arch. DAA can be accompanied by congenital cardiac defects, such as tetralogy of fallot and transposition of the great vessels.<sup>6</sup> Researchers recently reported that 20% of patients in their



**Figure 2** Left and right arches in the trachea are equal in size, but the right arch was 5 mm higher than the left.



**Figure 3** Computed tomography images of the patient's trachea in relation to neighbouring tissues.

study with DAA had an intracardiac defect.<sup>7</sup> 22q11 deletion was reported in 14% of the patients with normal intracardiac anatomy and DAA.<sup>8</sup> Symptoms are caused by compression of the trachea and the esophagus. At birth and in early infancy, symptoms such as respiratory distress, feeding difficulties, recurrent pneumonia, stridor, and dysphagia may occur as a result of tracheal and/or esophageal compression. But partial compression can lead to asymptomatic presentation, as shown in our patient. Adults with asymptomatic DAA are rare in literature. Presence of double cuts in right upper and left lower zones in tracheal air column is a significant finding. Barium esophagography may reveal esophageal compression but since the patient had no difficulty in swallowing we did not carry out

this procedure. Chest X-ray may be normal and the diagnosis may be missed. Various imaging methods may be used to reveal DAA, such as magnetic resonance imaging (MRI), computed tomography scanning, and aortography, in order to determine the best surgical approach for the patients who are surgical candidates.<sup>9</sup> We performed a three-dimensional CT for the purpose of gaining high quality three-dimensional images on a noninvasive basis. As far as we know this case is the first DAA case in which three dimensional CT scans. Echocardiography may be performed to reveal any intracardiac anomalies and may also be used for anatomical description of the vascular system. Bronchoscopy may be performed for the patients with compression of trachea to evaluate pulsatile

tracheal compression. A surgical approach is the only choice for the patients with a symptomatic vascular ring anomaly. Surgical operations have a very high rate of success in infant patients with DAA.<sup>2,7</sup> Some sporadic cases in which surgical treatments were performed in symptomatic adult patients have been reported.<sup>2,5,9,10</sup> Surgical intervention with division of the minor arch is recommended for those adult patients who are symptomatic and can be approached via either left posterolateral thoracotomy or median sternotomy.

A therapeutic dilemma exists when asymptomatic patients undergo surgery for another cardiac condition. To date, there have been five patients with asymptomatic DAA diagnosed in their 6th and 7th decades of life.<sup>2,11–14</sup> Four of these patients were treated conservatively; only one patient underwent surgical intervention.<sup>2</sup> Division of the vascular ring at the time of coronary revascularization due to moderate esophageal compression was performed in this patient.<sup>2</sup> Because our patient was asymptomatic with no compression of trachea or esophagus we did not perform any surgical intervention; however, we informed the patient about potential complications of DAA and encouraged him the patient to make follow-up appointments.

Due to the sporadic nature of this anomaly, there are not enough data on either the long-term prognosis or the standard care of untreated DAA in adulthood. The long-term complications experienced by untreated DAA in patients undergoing surgery are unknown. Recent reports documenting nonoperative management have had good results.<sup>12–14</sup>

In summary, DAA (1) is a very rare congenital anomaly in adulthood, (2) may cause symptoms due to compression of the esophagus and trachea, (3) three dimensional CT for DAA detection is invaluable due to its noninvasive nature and high quality images, and (4) surgical intervention may

be performed in symptomatic cases, otherwise nonoperative follow-up would be suitable.

## Disclosure

The authors report no conflicts of interest in this work.

## References

1. Gross RE. Surgical relief for tracheal obstruction from a vascular ring. *N Engl J Med*. 1945;233:586–590.
2. Kypson AP, Anderson CA, Rodriguez E, Koutlas TC. Double aortic arch in an adult undergoing coronary bypass surgery: a therapeutic dilemma? *Eur Cardiothorac Surg*. 2008;34:920–921.
3. Edwards J. Anomalies of derivatives of the aortic arch system. *Med Clin North Am*. 1948;32:925–949.
4. Edwards JE. Malformation of the aortic arch system manifested as vascular rings. *Lab Invest*. 1953;2:56–75.
5. Rita B, Simone S, Stefano B, Paolo M. Vascular ring due to double aortic arch: a rare cause of dysphagia. *Eur J Radiol*. 2004;52:21–24.
6. Emmel M, Schmidt B, Schickendantz S. Double aortic arch in a patient with Fallot's tetralogy. *Cardiol Young*. 2005;15:52–53.
7. Khalfan A, Rebecca G, Tara K, Williams WG, Crindle BW. Management and outcomes of double aortic arch in 81 patients. *Pediatrics*. 2006;118:e1336–e1341.
8. McElhinney DB, Clark BJ, Weinberg PM, et al. Association of chromosome 22q11 deletion with isolated anomalies of aortic arch laterality and branching. *J Am Coll Cardiol*. 2001;37:2114–2119.
9. Chiaki K, Shin T, Yoichiro M, Koji O, Hideto S, Isao Y. Successful surgical treatment for an adult case of double aortic arch. *Jpn J Thorac Cardiovasc Surg*. 2005;53:223–226.
10. Stoica SC, Lockowandt U, Coulden R, Ward R, Bilton D, Dunning J. Double aortic arch masquerading as asthma for thirty years. *Respiration*. 2002;69:92–95.
11. Ikenochi H, Tabel F, Itoh N, Nozaki A. Silent double aortic arch found in an elderly man. *Circulation*. 2006;114:e360–e361.
12. Yilmaz M, Tok M, Cengiz M. Asymptomatic balanced-type double aortic arch in an elderly patient: a case report. *Heart Surg Forum*. 2007;10:e297–e298.
13. Kajikawa Y, Takemoto S, Suganami Y, Inoue M. Asymptomatic double aortic arch. *Intern Med*. 2005;44:356–357.
14. Kindler H, Bagger JP, Tait P, Camici PG. A vascular ring without compression: double aortic arch presenting as a coincidental finding during cardiac catheterization. *Heart*. 2005;91:773.

### International Medical Case Reports Journal

### Publish your work in this journal

The International Medical Case Reports Journal is an international, peer-reviewed open-access journal publishing original case reports from all medical specialties. Previously unpublished medical posters are also accepted relating to any area of clinical or preclinical science. Submissions should not normally exceed 2,000 words or

Submit your manuscript here: <http://www.dovepress.com/international-medical-case-reports-journal-journal>

4 published pages including figures, diagrams and references. The manuscript management system is completely online and includes a very quick and fair peer-review system, which is all easy to use. Visit <http://www.dovepress.com/testimonials.php> to read real quotes from published authors.

Dovepress