



Contents lists available at ScienceDirect

## International Journal of Surgery Case Reports

journal homepage: [www.casereports.com](http://www.casereports.com)

# Anatomic variation of the relation between the inferior mesenteric artery and the bifurcation point of abdominal aorta during lower anterior resection: A rare case report

Maria Zarokosta<sup>a,\*</sup>, Theodoros Piperos<sup>a,\*</sup>, Dimosthenis Chrysikos<sup>a</sup>, Eythumios Nikou<sup>a</sup>, Ioannis Flessas<sup>a</sup>, George Skarpas<sup>a</sup>, Ioannis Papapanagiotou<sup>a</sup>, Ioannis Tsiaoussis<sup>b</sup>, George Noussios<sup>c</sup>, Theodoros Mariolis-Sapsakos<sup>a</sup>

<sup>a</sup> University Department of Surgery, General and Oncologic Hospital of Kifissia "Agii Anargiri", Athens, Greece & Anatomy and Histology Laboratory, School of Nursing, University of Athens, Greece

<sup>b</sup> Anatomy Laboratory, Faculty of Medicine, University of Crete, Crete, Greece

<sup>c</sup> Department of Physical Education and Sports Sciences, "Aristotles", University of Thessaloniki, Serres, Greece

## ARTICLE INFO

## Article history:

Received 18 July 2018

Received in revised form 28 August 2018

Accepted 5 September 2018

Available online 10 September 2018

## Keywords:

Inferior mesenteric artery variation

Relation with abdominal aorta

Lower anterior resection

## ABSTRACT

**INTRODUCTION:** Identification and ligation of the inferior mesenteric artery (IMA) is a crucial surgical step when performing lower anterior resection (LAR) for rectal cancer. Anatomic variations of the relation between the IMA and the bifurcation point of abdominal aorta (AA) encumber surgical maneuvers and are of great clinical importance.

**PRESENTATION OF CASE:** An unusual anatomic variation of the relation between IMA and the bifurcation point of AA was unexpectedly detected during LAR to a 69-year-old Caucasian female patient. The operation was uneventful. A meticulous review of the recent literature was conducted as well.

**DISCUSSION:** Variations of the mesenteric vascular supply are mainly identified incidentally, during the operation. In particular, variations of IMA are extremely uncommon in the literature. However, such kind of congenital variations, are not as rare as considered and their presence encumbers surgical maneuvers and increases the potentiality of intraoperative injury and hemorrhage.

**CONCLUSION:** Surgeons' deep knowledge and unceasing awareness concerning probable anatomic variations of the relation between the IMA and AA, combined with detailed exposure of the operative field and of the relationship between these adjacent arteries constitute the cornerstone of a safe operation.

© 2018 The Authors. Published by Elsevier Ltd on behalf of IJS Publishing Group Ltd. This is an open access article under the CC BY-NC-ND license (<http://creativecommons.org/licenses/by-nc-nd/4.0/>).

## 1. Introduction

Identification and ligation of the inferior mesenteric artery (IMA) constitutes a fundamental surgical step when performing lower anterior resection (LAR) for rectal cancer, prior to tumor mobilization [1,2]. The IMA is responsible for supplying arterial blood to the embryonic hindgut, that forms a large part of the bowel, including the caudal half of the transverse colon till the upper rectum [3]. Surgeons regularly identify the IMA and its branches during surgery by locating the bifurcation point of the abdominal aorta (AA) into the ileac arteries [1]. Anatomical variations of the origin of IMA are extremely rare, since the artery is typically diverging at the level of the L3 vertebra from the AA [4]. However, variations in

the relationship of the IMA with the AA, as in the presented case, are of paramount clinical importance as regards to diagnosis and surgical treatment [5]. The present manuscript, that aims to highlight a rare anatomic variation and its clinical significance for abdominal operations, has been reported in line with the SCARE criteria [6].

## 2. Case report

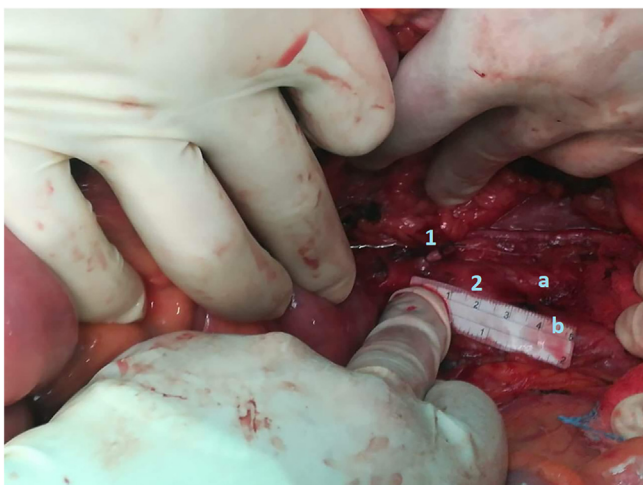
A 69-year-old Caucasian female presented to our institution with a 2-month history of rectal hemorrhage accompanied by changes of intestinal transit. The patient's medical history disclosed mild lower abdominal pain which progressively became worse and feeling of incomplete evacuation as well. Digital rectal examination, revealed a tumor in the posterior rectal wall. Colonoscopy showed a polypoid formation located at the upper rectum. Blood tests revealed anemia (Ht: 35% and Hb: 10 mg/dL). Additional CT of thorax, abdomen and pelvis detected no distant lung or liver metastases. Following these, lower anterior resection was scheduled.

\* Corresponding authors at: Anatomy and Histology Laboratory, Nursing School, National and Kapodistrian University of Athens, Papadiamantopoulou 123, Goudi, Athens, P.C:15773, Greece.

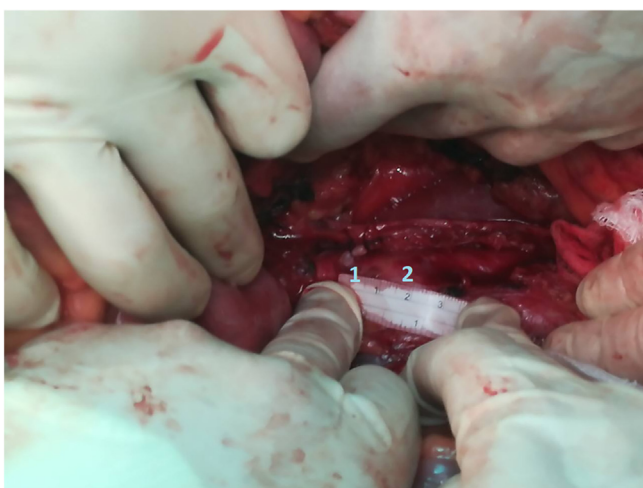
E-mail addresses: [mzarokos@nurs.uoa.gr](mailto:mzarokos@nurs.uoa.gr) (M. Zarokosta), [theo.piperos@gmail.com](mailto:theo.piperos@gmail.com) (T. Piperos).

<https://doi.org/10.1016/j.ijscr.2018.09.002>

2210-2612/© 2018 The Authors. Published by Elsevier Ltd on behalf of IJS Publishing Group Ltd. This is an open access article under the CC BY-NC-ND license (<http://creativecommons.org/licenses/by-nc-nd/4.0/>).



**Fig. 1.** Detailed exposure of the operative field before tumor mobilization. 1: origin of the IMA/2: bifurcation point of the AA/a: left common ileac artery/b: right common ileac artery.



**Fig. 2.** 1: origin of the IMA/2: bifurcation point of the AA.

Intraoperatively, the oncologic surgeons, after the mobilization of the sigmoid colon including the splenic flexure, attained to detect the inferior mesenteric vessels, prior tumor mobilization. The bifurcation point of the AA was utilized as key anatomical structure for the detection of the IMA. Nevertheless, the IMA was not found in the common mean distance of 4 cm to the bifurcation of AA. The IMA was incidentally detected originating from a distance of 1.2 cm to the bifurcation point (Figs. 1 and 2).

After the detailful exposure and isolation of the IMA, surgeons performed high ligation of the IMA close to the AA, in order to harvest the draining lymph nodes. Thus, it is considered that high ligation may improve node retrieval rates and ameliorate the accuracy of tumor staging. Therefore, the detection of its origin is a crucial and mandatory surgical step.

The operation continued in the usual fashion and was uneventful. The patient recovered uneventfully and was discharged the 6th postoperative day with instructions without any postoperative complications.

### 3. Discussion

During lower anterior resection (LAR) for rectal cancer, the identification and ligation of the IMA is a surgical step of major clinical

significance [1,2]. Indeed, this surgical maneuver is essential for the achievement of en bloc dissection of the lymph node metastases around the vessel's origin [7].

Surgeons may detect the origin of IMA during surgery by locating the bifurcation point of the AA into the common ileac arteries [1]. The bifurcation point of the AA is located at level of L4 vertebra in 87.1% and its mean distance from the origin of the IMA is estimated 4 cm (range: 2–5 cm) [8]. Nevertheless, in the presented case the origin of IMA was detected 1.2 cm prior to the bifurcation point of AA.

The position of the IMA appears to be rather stable and not subject to much variation [9]. In particular the artery is typically originating from the anterior or left anterolateral aspect of AA at the level of the L3 [4]. Herein, the L3 vertebra is commonly utilized as a key anatomical landmark when performing angiographs of the IMA [10].

However, in a recent study IMA was found arising at the level of L3 in approximately 50%, with approximately 25% arising at the lower third of the L3, and greater than 50% of the cases branching at locations other than the L3 [10].

Moreover, Kornreich et al. report that arteries tend to elongate with age due to arteriosclerosis, and that decreased vertebral height as a result of osteoporosis or other conditions may cause the bifurcation point of AA to shift caudally [11]. The present observation may probably explain the position of IMA from the AA in the present case due to the patient's age as well.

There are several documented variations of the IMA. In fact, the artery was found arising from the left common iliac artery or the superior mesenteric artery or it may even be entirely absent [4,9–12]. Lamentably though, it is considered that the anatomical variations of IMA are not extensively studied and the literature is restricted [9]. Therefore, it is quite evident that probable novel variations may be detected since the existing literature is restricted.

Anatomic variations of the origin of IMA and of its relationship with the AA, as in the presented case, are of paramount clinical importance regarding diagnosis and surgical treatment [5,9]. More specifically, such variations require specific caution, when using lumbar vertebral height as an anatomical landmark during surgical and imaging procedures of the IMA [10]. Additionally, abnormal relation between the IMA and the bifurcation of AA might encumber high ligation of the IMA during surgery for rectal cancer, with subsequent implications. Furthermore, aberrant location of the origin of the IMA poses a major risk factor of accidental injury and hemorrhage.

Finally, knowing the relation between AA and its branches is fundamental and crucial for both imaging and surgical interventions. Herein, more studies emphasizing on the investigation of the probable sites of the origins of all the arterial branches, including IMA should be conducted, and their results should be compared with current literature.

### 4. Conclusion

Conclusively, it seems that anatomic variations of the origin of the IMA and its relationship with AA, may be actually more common, than described in the literature, although they are not reported yet. Such variations pose difficulties on both surgical and diagnostic procedures that might lead to unpleasant implications. Hence, surgeons' deep knowledge in addition to detailed exposure of the relationship between these adjacent arteries constitute the cornerstone of a safe LAR and other abdominal operations.

### Conflict of interest

There is no any conflict.

**Funding**

None.

**Ethical approval**

This is a Case Report for which the patient provided written informed consent. Ethical approval has also been provided by the ethical committee of the General & Oncologic Hospital of Kifisia “Agii Anarguri”.

**Consent**

Written consent was provided from the patient for the publication of this case report and accompanying images.

**Author contribution**

Mariolis-Sapsakos and Zarokosta conceived of the study. Noursios was senior consultant at this case report and participated in its coordination. Nikou, Skarpas and Papapanagiotou contributed to the acquisition of clinical data, its interpretation and to the preparation of images. Piperos, Flessas and Chrysikos contributed to literature review. Nikou, Piperos and Zarokosta contributed to the preparation of the manuscript. Mariolis-Sapsakos and Tsiaousis contributed to the refinement of the case report. All authors have approved the final article.

**Registration of research studies**

This is not a first in a man study, subsequently, its registration is not essential.

**Guarantor**

Noussios George and Mariolis-Sapsakos Theodoros.

**Provenance and peer review**

Not commissioned, externally peer-reviewed.

**References**

- [1] J. Hida, K. Okuno, High ligation of the inferior mesenteric artery in rectal cancer surgery, *Surg. Today* 43 (January (1)) (2013) 8–19.
- [2] R.J. Wnale, C.M.S. Royston, Anterior resection of the rectum simplified stapling technique, *Ann. R. Coll. Surg. Engl.* 67 (1985).
- [3] B.M. Carlson, *Human Embryology and Developmental Biology*, 5th ed., Elsevier/Saunders, Philadelphia, 2013.
- [4] S.J. Yoo, M.J. Ku, S.S. Cho, S.P. Yoon, A case of the inferior mesenteric artery arising from the superior mesenteric artery in a Korean woman, *J. Korean Med. Sci.* 26 (2011) 1382–1385.
- [5] A. Songür, M. Toktaş, O. Alkoç, T. Acar, İ. Uzun, O. Baş, O.A. Özen, Abdominal aorta and its branches: morphometry – variations in autopsy cases, *Eur. J. Gen. Med.* 7 (3) (2010) 321–325.
- [6] R.A. Agha, A.J. Fowler, A. Saetta, I. Barai, S. Rajmohan, D.P. Orgill, for the SCARE Group, The SCARE statement: consensus-based surgical case report guidelines, *Int. J. Surg.* 34 (October) (2016) 180–186, 2016.
- [7] M.J. Dworkin, T.G. Allen-Mersh, Effect of inferior mesenteric artery ligation on blood flow in the marginal artery-dependent sigmoid colon, *J. Am. Coll. Surg.* 183 (1996) 357–360.
- [8] E.G. H Eldeen, M.A.H. Abdel Galil, Anatomical pattern of the origins of the ventral branches of the abdominal aorta, Conference: 8th International Symposium of Clinical and Applied Anatomy (2016), <http://dx.doi.org/10.13140/RG.2.2.21642.47046>, September.
- [9] R.A. Bergman, A.K. Afifi, R. Miyauchi, *Inferior Mesenteric Artery. Illustrated Encyclopedia of Human Anatomic Variation: Opus II: Cardiovascular System: Arteries: Abdomen*, 2018.
- [10] Y. Nakayama, S. Hayashi, K. Takeuchi, S. Kawata, N. Qu, M. Itoh, Positional relationships of abdominal aortic branches for contrast radiography of the inferior mesenteric artery using the coeliac trunk and superior mesenteric artery as landmarks, *Okajimas Folia Anat.* 93 (4) (2017) 139–145.
- [11] L. Kornreich, H. Hadar, J. Sulkes, M. Gornish, J. Ackerman, N. Gadoth, Effect of normal aging on the sites of aortic bifurcation and inferior vena cava confluence: a CT study, *Surg. Radiol. Anat.* 20 (1998) 63–68.
- [12] S.1 Kitamura, T. Nishiguchi, A. Sakai, K. Kumamoto, Rare case of the inferior mesenteric artery arising from the superior mesenteric artery, *Anat. Rec.* 217 (January (1)) (1987) 99–102.

**Open Access**

This article is published Open Access at [sciencedirect.com](https://www.sciencedirect.com). It is distributed under the [IJSCR Supplemental terms and conditions](#), which permits unrestricted non commercial use, distribution, and reproduction in any medium, provided the original authors and source are credited.