

# Degloving Soft Tissue Injuries of the Extremity: Characterization, Categorization, Outcomes, and Management

Christine Velazquez, MD\*  
 Litton Whitaker, MS†  
 Ivo A. Pestana, MD†

**Background:** We aimed to identify degloving soft tissue injury (DSTI) patient characteristics, injury and reconstruction patterns, and factors affecting outcomes of DSTI injuries to propose a reconstructive protocol for these injuries.

**Methods:** A retrospective analysis of consecutive patients with DSTIs of an extremity over a 22-year period has been done.

**Results:** 188 patients with 201 extremity DSTIs were included. Mean patient age was 37 years, with follow-up of 19.6 months. In total, 96% of injuries were related to motor vehicles or machinery, and 74.6% of DSTIs had injuries to structures deep to skin/subcutis. The avulsed tissue was utilized in reconstruction in 71.6% of cases and 86.8% of these experienced some loss of the used avulsed tissues. Of the total cases, 82% employed skin grafting in reconstruction. Dermal regeneration templates were used in 32% of patients. An estimated 86.5% of patients had negative pressure wound therapy utilized. Of the injured patients, 21% required flap reconstruction and 22% required some form of amputation. Age, body mass index, and tobacco use did not increase perioperative complications or amputation. DSTIs with injury to structures deep to skin/subcutis were associated with negative pressure wound therapy use ( $P = 0.02$ ). DSTIs with underlying fractures required more procedures to reach reconstruction completion ( $P = 0.008$ ), had more minor ( $P = 0.49$ ) and major perioperative complications ( $P = 0.001$ ), longer time to heal ( $P = 0.002$ ), and increased need for amputation ( $P = 0.02$ ).

**Conclusions:** Factors affecting the reconstructive management and outcome of DSTIs include injury to structures deep to the skin/subcutis. We categorized DSTIs based on the level of injury and proposed a systematic approach to extremity DSTIs which may be utilized by plastic surgeons and other surgical services to manage these complex injuries. (*Plast Reconstr Surg Glob Open* 2020;8:e3277; doi: 10.1097/GOX.0000000000003277; Published online 20 November 2020.)

## INTRODUCTION

Degloving soft tissue injuries (DSTIs) of the extremity are limb-threatening injuries produced by shearing forces applied to soft tissues during high-impact trauma.<sup>1</sup> The avulsion of native tissues from one another may devascularize these structures and create debilitating wounds. Each DSTI is unique and differs in complexity based upon the mechanism of injury, anatomic location, presence of

co-existing injuries, and degree of tissue loss. The true incidence of DSTIs is unknown due to the variable nature of these injuries, the lack of widely accepted diagnostic criteria, and unknown prognostic indicators.<sup>2,3</sup>

The basic treatment principles of extremity DSTIs include early diagnosis, excision of devitalized tissues, revascularization, and skeletal fixation as indicated. Once these limb-preserving interventions are executed, the affected extremity commonly requires reconstruction to restore meaningful function. Damage to structures including fascia, muscle, tendon, nerve, blood vessels, and bone requires a multidisciplinary approach across surgical subspecialties to achieve optimal outcomes.<sup>4-10</sup>

To date, the majority of literature regarding DSTIs of the extremity have been descriptive in nature, focusing on management techniques for the avulsed soft tissues. In this study, we aim to identify patient characteristics, injury

From the \*Department of General Surgery, Wake Forest School of Medicine, Wake Forest University, Winston-Salem, N.C.; and †Department of Plastic and Reconstructive Surgery, Wake Forest School of Medicine, Wake Forest University, Winston-Salem, N.C.

Received for publication October 6, 2020; accepted October 8, 2020.

Copyright © 2020 The Authors. Published by Wolters Kluwer Health, Inc. on behalf of The American Society of Plastic Surgeons. This is an open-access article distributed under the terms of the Creative Commons Attribution-Non Commercial-No Derivatives License 4.0 (CCBY-NC-ND), where it is permissible to download and share the work provided it is properly cited. The work cannot be changed in any way or used commercially without permission from the journal.

DOI: 10.1097/GOX.0000000000003277

**Disclosure:** The authors have no financial interest to declare in relation to the content of this article. No financial assistance or support was obtained for this study.

types, and reconstruction patterns affecting patient outcomes who suffer from traumatic DSTIs. Furthermore, we propose a management protocol to standardize the approach to reconstruction and to expedite the use of resources necessary to successfully treat these devastating injuries.

### METHODS

After obtaining institutional review board approval, a retrospective analysis was conducted for evaluating consecutive patients with DSTIs of an extremity over a 22-year period at a single, academic institution. Patients included in the study were those with a confirmed DSTI on medical record evaluation (documented injury descriptions, clinical images) and DSTI International Classification of Diseases, Ninth Revision, codes (ICD-9, codes encompassing extremity wounds with or without foreign body) and International Classification of Diseases, Tenth Revision, codes (ICD-10, codes equivalent to ICD-9 codes in addition to specific ICD-10 degloving injury codes). Patients excluded from the study were those lacking the presence of a DSTI based on descriptions, images, or codes identified in the medical record. Morel-Lavallée injuries (closed DSTIs) and finger degloving injuries were excluded from the study. Data collected included patient age, gender, occupation, medical comorbidities, smoking status, injury mechanism and extremity involved, vascular assessment of the degloved tissue and its use, associated extremity injuries, surgical management of the injuries and their reconstruction, perioperative complications, and time to wound healing. Patient age was subcategorized into <18 years, 18–39 years, 40–59 years, and ≥60 years. Time to heal was divided into <2 weeks or >2 weeks. Perioperative complications were classified into major and minor, in which major complications required hospital admission, unplanned procedures, or unplanned return to the operating room. Minor complications were those that could be managed in the clinic setting. Associated extremity injuries were analyzed per extremity while complications were analyzed per patient injured.

Descriptive statistics (including means and SDs for continuous measures, frequencies, and proportions) were calculated for all study measures. With some subjects having multiple injuries, repeated measures logistic regression models (with Generalized Estimating Equations, or GEE, and an exchangeable correlation structure) were used to test for associations between outcomes and potential predictor variables. SAS (version 9.4; Cary, N.C.) was used for all statistical analyses. Statistical significance of  $P < 0.05$  was utilized.

### RESULTS

A total of 188 patients with 201 extremity DSTIs were included. The injuries were initially evaluated and managed by multiple independent surgical services. Specifically, the general surgery service at our institution evaluated over half of the patients at initial presentation ( $n = 98, 52.1\%$ ). The mean patient age at the time of injury was 37 years, with a mean follow-up of 19.6 months. Over 75% of injured patients were men, and 13.3% of patients

**Table 1. Characteristics of DSTI Study Patients**

Characteristic	Data
Total Patients, n	188
Total DSTIs, n	201
Age, mean (SD), y	37 (18.6)
Body mass index, mean (SD), kg/ m <sup>2</sup>	27.8 (7.2)
Follow-up, mean (SD), m	19.6 (26.7)
Male, n (%)	142 (75.5)
Female, n (%)	46 (24.5)
Pediatric (<18 y), n (%)	25 (13.3)
Adult (>18 y), n (%)	163 (86.7)
Diabetes, n (%)	13 (6.9)
Active tobacco use, n (%)	80 (42.6)
CAD, n (%)	12 (6.4)
Hypertension, n (%)	42 (22.3)
PAD, n (%)	1 (0.5)
Initial service to evaluate and manage injury	
General surgery, n (%)	98 (52.1)
Orthopedics, n (%)	58 (30.1)
Plastic surgery, n (%)	25 (13.3)
Pediatric surgery, n (%)	7 (3.9)

**Table 2. Characteristics of DSTI Injuries and Associated Injuries**

Characteristic	Data
Injured extremity	
Upper extremity, n (%)	98 (48.8)
Lower extremity, n (%)	103 (51.2)
DSTI involving skin/subcutis, n (%)	51 (25.4)
DSTI involving skin/subcutis + deeper structures, n (%)	150 (74.6)
Vascular injury, n	35
Nerve injury, n	22
Bone fracture, n	126
Tendon laceration, n	50
Burn, n	14
Non-extremity injury, n	3

were aged <18 years. The mean patient body mass index was 27.8 Kg/m<sup>2</sup>, and the comorbidities analyzed included active tobacco use (42.6%), diabetes mellitus (7%), hypertension (22.3%), coronary artery disease (6.4%), and peripheral vascular disease (0.5%) (Table 1). Ninety-six percent of these injuries were related to motor vehicles or machinery, and they were evenly distributed between the upper and lower extremity (Table 2).

Over 74% of the extremity DSTIs had injuries to anatomic structures deep to skin and subcutaneous tissues, most commonly bone fractures ( $n = 126, 62.7\%$ ) (Table 2). Patients required an average of 5.6 operations to reach reconstruction completion. All injured extremities underwent debridement, and 82% of injuries employed skin grafting as a reconstructive technique. In the majority of cases, the avulsed soft tissues were used in the reconstruction ( $n = 144, 71.6\%$ ). Of those patients, 86.8% experienced either partial or complete loss of this tissue (referred to as “usable tissue”). Use of dermal regeneration templates (DRTs) and negative pressure wound therapy (NPWT) was at the discretion of the operative team/surgeon. Although no significant relationship was identified between the presence of a bone, tendon, or nerve injury and the use of a DRT, they were used in 32% of patients. NPWT was utilized in 86.5% of patients and, when utilized, it was commonly initiated at the first operative debridement and an average of 3.8 dressing changes were completed before definitive wound management.

**Table 3. Operative Characteristics of Study Group**

Characteristic	Data
Patients that underwent operative debridement, n (%)	188 (100)
No. debridements before reconstruction, mean (SD)	3.1 (2.1)
No. procedures to reconstruction completion, mean (SD)	5.6 (3.3)
Use and loss of degloved tissues	
Available and used in reconstruction, n (%)	144 (71.6)
Complete or partial loss of used avulsed tissue, n (%)	125 (86.8)
Reconstructive interventions	
Bony fixation, n	98
Bone graft, n	1
Vascular reconstruction*, n	17
Vascular ligation, n	11
Nerve repair, n	7
Nerve graft, n	3
Fasciotomy, n	33
Tendon repair, n	24
Tendon transfer, n	9
Tendon graft, n	2
Skin graft, n	165
DRT, n	65
NPWT, n	174
Pedicled or free flap, n	42
Time to heal per DSTI	
<2wk, n (%)	67 (33.3)
>2wk, n (%)	134 (66.6)
Amputation, n (% of injured extremities)	44 (21.8)

\*Vascular reconstructions performed acutely to re-vascularize the limb.

Twenty-two percent of patients required flap reconstruction consisting of 32 pedicled flaps and 13 free flaps, and one-third of extremity DSTIs healed in the 2 weeks or less timeframe. Despite limb salvage and reconstructive procedures employed, 22% of patients required some form of amputation (Table 3). The overall complication rate was 42.6%, and the majority of these complications (77.5%) were major complications. Over 40% of documented complications were infectious in nature (Table 4).

Regarding factors affecting the reconstructive technique utilized, DSTIs with injury to structures deep to skin/subcutaneous tissues, particularly those with tendon injuries, were associated with NPWT use ( $P = 0.02$ , OR 2.86, 95% CI 1.24–6.63) indirectly indicating the clinical reasoning for its use (Table 5). Furthermore, the general presence of any comorbidity did not affect the occurrence of a perioperative complication, the need for amputation, the number of surgical interventions, or time to heal (Table 6). Comorbidity subgroup analysis demonstrated that the presence of hypertension was associated with a higher rate of amputation compared with other individual comorbidities ( $P = 0.029$ , OR 2.63, 95% CI 1.26–5.51). DSTIs with injuries to structures deep to skin and subcutaneous tissue were noted to have higher rates of perioperative complications and amputation, more surgical interventions, and longer time to heal. DSTIs with a bone fracture required more procedures to reach reconstruction completion ( $P = 0.008$ ), had more minor ( $P = 0.49$ , OR 3.04, 95% CI 1.03–8.93) and major perioperative complications ( $P = 0.001$ , OR 2.71, 95% CI 1.40–5.25), longer time to heal ( $P = 0.002$ , OR 2.70, 95% CI 1.49–4.91), and increased need for amputation ( $P = 0.02$ , OR 2.40, 95% CI 1.11–5.19) (Table 6).

### DISCUSSION

DSTIs of the extremity are avulsion-type injuries associated with significant patient morbidity.<sup>5</sup> The true incidence

**Table 4. Summary of Extremity DSTI Complications**

Characteristic	Data
Patient with perioperative complication, n (%)	80 (42.6)
Patient with major perioperative complication, n (%)	62 (77.5)
Patient with minor perioperative complication, n (%)	18 (22.5)
Total perioperative complications, n	194
Myocardial infarction, n	2
Compartment syndrome, n	9
Extremity ischemia, n	7
Flap loss, n	4
Delayed wound healing, n	22
Hematoma, n	5
Nerve injury/ compression/ palsy, n	8
Joint contracture, n	29
Bony nonunion or malunion, n	12
Complex Regional Pain Syndrome, n	8
DVT/PE, n	4
<b>DRT Infection/ Loss, n</b>	<b>8</b>
<b>Skin Graft Infection/ Loss, n</b>	<b>10</b>
<b>Flap Infection, n</b>	<b>3</b>
<b>Skin Graft or Flap Donor Site Infection, n</b>	<b>2</b>
<b>Tissue Expander or Hardware Infection/ Loss, n</b>	<b>5</b>
<b>Wound Infection, n</b>	<b>21</b>
<b>Osteomyelitis, n</b>	<b>11</b>
<b>Abscess, n</b>	<b>13</b>
<b>Cellulitis, n</b>	<b>9</b>
<b>Septic Shock, n</b>	<b>2</b>
Infectious Complication, n (% of all Complications)	84 (43.3)

Bold entries denote infection-related complications which accounted for 43.3% of all complications that occurred in study group.

of this injury type is unknown due to several factors, including, but not limited to, the myriad of possible etiologies of a DSTI, the lack of standard diagnostic criteria defining them, and the variability in injury severity. Furthermore, the mechanism of DSTI and presence of associated injuries not only affects the clinical setting of initial management (wound care center, outpatient clinic, emergency department, or trauma center) but also the healthcare specialty treating the injury. Despite the above variables, treatment generally begins with defining the injury by determining injured tissue viability and debridement of necrotic and poorly perfused tissues. This is followed by repair of salvageable structures and determination of the ideal soft tissue coverage for the injured regions.<sup>2,11,12</sup>

Due to the paucity of available literature concerning overall extremity DSTI management and factors affecting their prognosis, this study was undertaken. To our knowledge, we report the largest cohort of extremity degloving injuries evaluated and managed at an academic hospital in the United States. We characterize extremity DSTIs by identifying patient characteristics who sustain these injuries, injury etiologies and tissues injured, injury management and reconstruction outcomes, as well as the factors affecting them. Based upon these findings and knowledge of current extremity DSTI literature, we propose a classification system and treatment algorithm.

The initial evaluation and management of degloving injuries affects their outcome. Factors contributing to this include diagnostic challenges faced by healthcare providers unfamiliar with this injury type and the lack of clear decision-making strategies for DSTIs. This frequently results in underestimation of underlying tissue damage and delay in definitive wound management increasing the risk of infection.<sup>2</sup> At our institution, initial evaluation of

**Table 5. Factors Affecting DSTI Reconstruction Techniques**

Associated Injury	NPWT Use ( <i>P</i> , OR, and 95% CI)	DRT Use ( <i>P</i> )	Flap ( <i>P</i> )
Vascular	NS	NS	NS
Nerve	NS	NS	NS
Bone Fracture	NS	NS	NS
Tendon Injury	0.015, 2.86 (1.24, 6.63)	NS	NS
Burn	NS	NS	NS

extremity DSTIs was most commonly completed by the general surgery service. This is typical for our hospital setting because general surgery is the initial surgical team to evaluate level 1 and 2 trauma patients. Albeit less frequent, orthopedics, vascular surgery, pediatric surgery, and plastic surgery were also noted to be services that assumed initial care of these patients. In addition to multiple different teams managing these patients, many patients in our cohort required evaluation by more than one surgical service in the emergency department. Although this provided necessary healthcare and interventions, initial evaluation and management of these injuries by different surgical specialties may have introduced a significant confounder into the care and ultimate outcome of the patient’s injury. For instance, initial management of a complex DSTI requiring multiple service evaluations may increase the time to treatment. If surgical interventions are performed by multiple services, this may result in over or under-resection of injured tissues affecting injury size and reconstructive needs. The theoretical advantage of minimizing the number of involved services, or organizing management into an established multidisciplinary team, is decreased time interval between presentation and definitive wound management. Improved efficiency to DSTI management has been shown to increase viability of extremity structures and decrease the risk of infection from trauma-site inoculation.<sup>3</sup> A multidisciplinary approach with early involvement of intensivists and surgical teams, including reconstructive surgery, is essential in the care of these patients. Mello et al.<sup>13</sup> analyzed cases of degloving injuries and compared outcomes of early versus delayed assessment by the plastic and reconstructive surgery team. They found that delayed assessment resulted in an increased number of operations as well as length of hospital stay.<sup>13</sup> Based upon the above, as well as the identification that over 40% of complications in our patient population were infectious in origin, our group is actively developing a multidisciplinary team to manage these patients once they are identified.

Other factors that may expedite evaluation and initiation of DSTI treatment include methods employed to define tissue viability. At our institution, clinical evaluation

of injured tissues by the surgical team was utilized in most cases to assess for tissue viability. However, this method is subjective, varies among providers, and can be unreliable when used alone. In our patient cohort, Indocyanine green fluorescent angiography (ICGFA) was utilized to assess tissue perfusion as a reflection of tissue viability in a limited number of cases and its benefit, or lack thereof, cannot be determined from the study cohort. Although ICGFA has been used extensively to determine the adequacy of tissue perfusion and predict skin flap necrosis, it has not achieved widespread use in the evaluation of degloved soft tissues.<sup>14-17</sup> Green et al.<sup>18</sup> conducted a retrospective review of war-related traumatic extremity injuries and amputations.<sup>18</sup> Fluorescent angiography was used to assess perfusion concerns in 35 cases and found ICGFA to not only reduced perfusion-related complications but also aided intraoperative surgical decision-making.<sup>18</sup> Similarly, Mothes et al.<sup>19</sup> reported the prognostic power of ICGFA to be higher than other objective measures in predicting tissue necrosis and reported a 47.2% procedure modification based on their intraoperative ICGFA findings.<sup>19</sup> These studies, in addition to its use in our cohort, suggest that there is a basis for implementation of ICGFA into reconstruction algorithms and the evaluation of degloved soft tissues.

Patients identified with extremity DSTIs were most commonly overweight adult males who sustained a degloving injury due to some form of machinery. The most common comorbidities identified in the patient cohort were hypertension and tobacco use. The presence of comorbidities (ie, diabetes, smoking) and their associated hostile tissue microenvironment (ie poor perfusion, infection) have the potential to limit tissue healing, increase the risk of complications, and prolong patient recovery.<sup>20,21</sup> Despite this, the general presence of a comorbidity within our patient population was not associated with worse outcomes. This correlates with previous reports that outcomes of severe extremity injuries may be more affected by the patient’s social, economic, and personal resources rather than by their physical status and initial injury treatment.<sup>22</sup>

Three-quarters of the degloving injuries in our patient cohort involved skin and subcutaneous tissue layers in addition to deeper structures. Classification schemes have been developed to describe and organize complex extremity injuries. In 1976, Gustilo and Anderson<sup>23</sup> classified tibial fractures in the context of overlying soft tissue damage severity.<sup>23</sup> Similarly, Tschernie and Südkap<sup>12</sup> classified bony fractures based on the presence of an open wound versus a closed wound, as well as described their subsequent management.<sup>12</sup> The AO/ASIF classification of extremity

**Table 6. Factors Affecting DSTI Outcomes**

Characteristic	Perioperative Complication ( <i>P</i> , OR, and 95% CI)	Amputation ( <i>P</i> , OR, and 95% CI)	More Operative Interventions ( <i>P</i> )	Time to Heal: >2wk ( <i>P</i> , OR, and 95% CI)
ANY comorbidity	NS	NS	NS	NS
ANY associated injury	0.006, 2.9 (1.53, 5.54)	0.008, 3.15 (1.16, 8.54)	0.0003	0.017, 2.42 (1.23, 4.78)
Bone fracture	0.0006, 2.9 (1.53, 5.54)	0.015, 2.4 (1.11, 5.19)	0.0088	0.002, 2.7 (1.49, 4.91)

injuries includes the delineation of deep structures injuries (ie, muscle, tendon, nerve, and vasculature).<sup>24</sup>

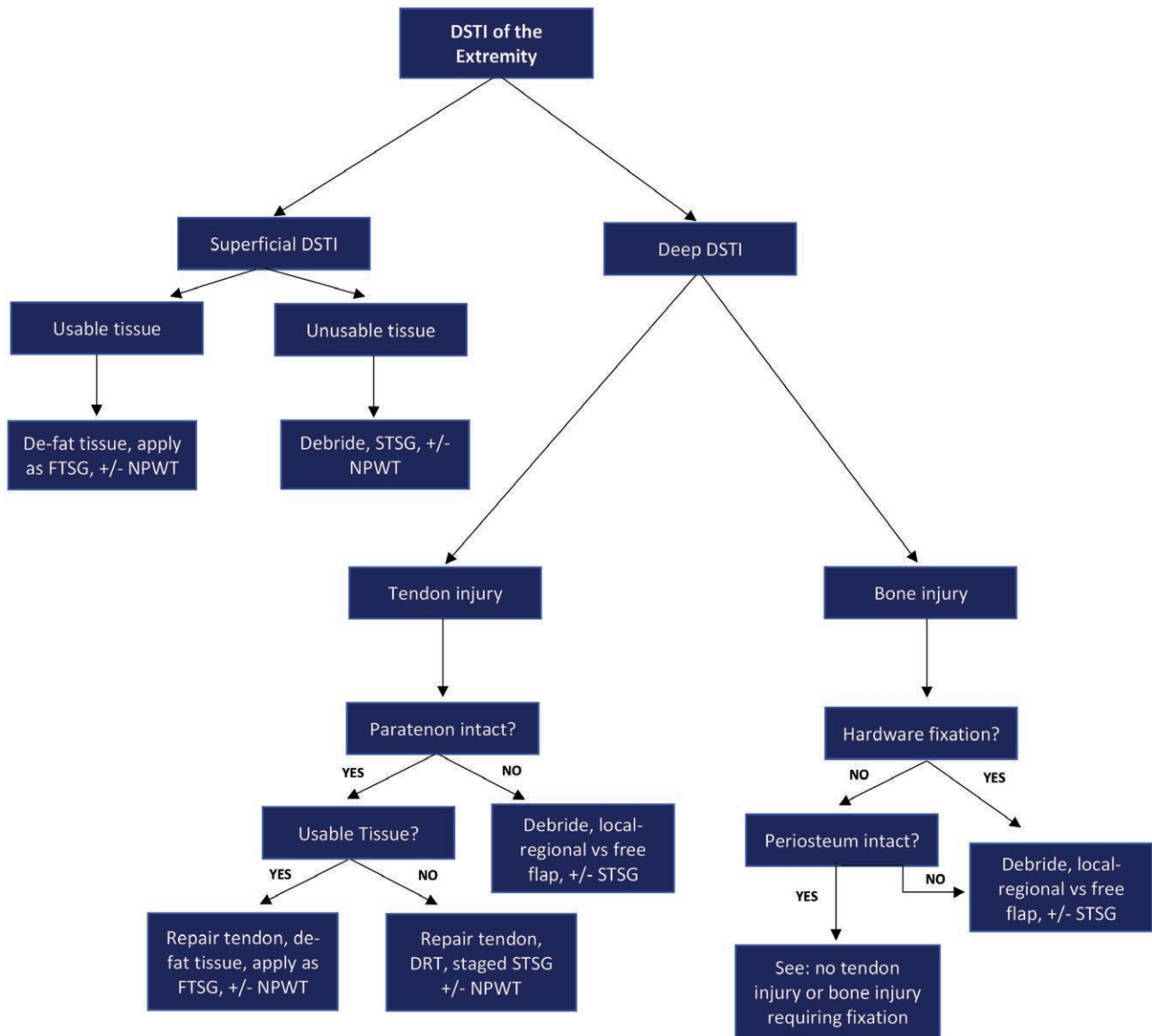
Only recently noted in the literature, descriptive systems specific to degloving injuries are few and not universally employed due to specific limitations. Arnez et al.<sup>4</sup> retrospectively reviewed 68 patients with 79 degloved limbs to describe soft tissue injury patterns and their relation to prognosis. The authors categorized DSTIs into abrasion/avulsions, non-circumferential deglovings, circumferential deglovings in a single-plane (usually between deep fascia and subcutaneous tissues/skin), and circumferential multi-plane deglovings.<sup>4</sup> Similar to our cohort, the more complex the injury pattern, the less likely the wounds would heal with primary closure and would need alternative soft tissue reconstruction. While this grading pattern organizes limb DSTIs into basic groups and identifies the direct relation of injury pattern grade to poor prognosis, it does not describe other factors that affect patient outcomes or the use of commonly employed interventions in today's wound management armamentarium. Yan et al.<sup>5</sup> proposed an alternative degloving classification system in 2013. The group reviewed 102 patients with 129 lower extremity skin avulsions and described the technique of avulsion wound radical debridement followed by immediate full-thickness skin grafting using the avulsed skin. The authors grouped injuries into 3 patterns: pure degloving injury (either circumferential or non-circumferential), degloving injury involving deep soft tissues, and deglovings with long-bone fracture.<sup>5</sup> The magnitude of shearing forces required to produce these patterns were noted to increase between pure deglovings and those with associated long-bone fractures.<sup>5</sup> While the authors report results of their technique, factors affecting patient outcomes were not clearly identified nor were use of other accepted management techniques. Interestingly and in contradistinction to our patient cohort where NPWT was utilized in the majority of cases particularly when tendon injuries were present, Yan et al.<sup>5</sup> did not find this intervention helpful due to skin graft losses in several patients where NPWT was employed.<sup>5</sup> Furthermore, this group followed a protocol of immediate radical debridement and reconstruction, which is quite different than the more conservative approach applied at our institution to minimize the sacrifice of potentially healthy tissues. We identified that 71.6% of extremity deglovings had avulsed tissue available at the time of evaluation and this was utilized for attempted closure of the wounds. Due to the lack of standardized descriptions/measurements or images of the degloving injury as it evolved through management, objective evaluation of loss of used soft tissues in reconstruction could not be determined beyond partial or complete loss. Of the patients with avulsed tissue used in attempted closure, approximately 15% maintained at least part, if not all, of those used tissues. Although high percentage of patients will lose some salvaged tissue, an attempt at its preservation is justified to minimize future interventions or to control the size of skin graft or flap donor sites.

The majority of the literature specific to degloving injuries focuses on degloved tissue handling techniques or reconstructive options. For instance, the use of avulsed

skin as a full-thickness skin graft has been described, as well as difficulties maintaining graft position due to edema and bleeding.<sup>25</sup> Perforated patterns, such as that described by Jeng et al,<sup>26</sup> have been used to minimize seroma formation and improve full-thickness graft success rates. The use of DRTs in the reconstruction of degloving injuries has been increasing. Graham et al.<sup>27</sup> conducted a retrospective review of 10 patients who were treated with Integra DRT followed by split-thickness auto-grafting. They reported that 9 of 10 patients experienced adequate cosmetic and functional results.<sup>27</sup> Similarly, Dini et al.<sup>28</sup> described the management of a subtotal, circumferential lower extremity degloving injury with cryopreserved split-thickness skin graft (STSG) in combination with a DRT and NPWT therapy.<sup>28</sup> Reynolds et al.<sup>29</sup> investigated the role of Integra DRT in complex hand wounds from non-burn trauma.<sup>29</sup> The case series included patients with exposed bone, tendon, and joints and demonstrated a high rate of reconstructive success and return to pre-injury function levels with the use of this DRT.<sup>29</sup> Although the above series are small, their results support the use of DRTs as an option in the management of complex wounds to achieve adequate aesthetic and functional outcomes.<sup>27-29</sup> Dermal regeneration templates were employed in 32% of degloved limbs, further supporting the trend of increasing use of these materials in the management of complex extremity injuries.

Reconstructive algorithms for complex extremity injuries have been described with potential benefits in patient outcomes.<sup>30</sup> Based upon the above characterization of extremity DSTIs and the factors affecting their outcomes, we propose an extremity DSTI classification and management algorithm. Although we understand there are nuances to the management of DSTIs of different anatomic locations, the proposed classification system simplifies the injuries into 2 groups based upon the anatomic level of injured tissues, which is generalizable to various anatomic levels due to the presence of fascial structures in both the upper and lower extremity. "Superficial" extremity DSTIs are those with tissue injuries isolated to structures superficial to the extremity's deep fascia and may be managed with either full thickness or split thickness skin grafting, based on the surgeons experience and expertise. In contrast, "Deep" extremity DSTIs are those with tissue injury superficial and deep to the extremities deep fascia. The management algorithm relies on the "usability" of degloved tissues and the status of underlying critical structures including tendon, paratenon, bone, and periosteum (Fig. 1). The clinical impact of the proposed algorithm is to provide a simplified thought process for a variety of practitioners that may evaluate and begin management of an extremity DSTI. The anatomic component of the algorithm provides an easily identifiable anatomic level to cue the evaluating service of the likelihood of the presence or absence of deeper injury and the need for multidisciplinary evaluation and care.

Limitations of the study include its completion at a single institution as well as its retrospective nature. Our cohort was not randomly assigned to specific interventions, although this may be impossible to do in this patient population. Despite this, we are currently studying the implementation of the above management approach in a prospective manner



**Fig. 1.** Extremity DSTI classification and management algorithm. Usable tissue, degloved tissues deemed salvageable; FTSG, full-thickness skin graft.

to evaluate its effects on end-points such as treatment times and patient outcomes. Use of ICD-9/ICD-10 codes, clinical descriptions, and images of the injuries from the electronic medical record may be considered a limitation of this study since characterization of the injury orientation/ geometry and remnant tissue vascularity could not be routinely identified. Furthermore, data regarding functional outcomes of extremity use, particularly for the upper extremity, were unavailable or incomplete, limiting the description of patient outcomes in our cohort. Additionally, DSTIs managed in an outpatient setting or those that were misdiagnosed as lacerations or other injury types may have gone unaccounted. Our experience also lacks generalizability beyond an academic, level 1 trauma center because care of this injury type requires healthcare providers familiar with DSTIs as well as those capable of advanced imaging techniques and reconstructive procedures.

### CONCLUSIONS

DSTIs are complex injuries managed by a variety of surgical services, which may require multiple operations and a variety of techniques for reconstruction. Avulsed tissue resulting from an extremity DSTI is frequently available and used during the initial reconstructive efforts. However, this method has a high rate of tissue loss. Factors affecting outcomes and reconstructive management of DSTIs include injury to structures deep to skin/subcutis. Reconstruction efforts for injuries involving tendon disruption frequently involve the use of NPWT. DSTIs have a high complication rate, most of which are secondary to infections.

Any extremity DSTI with an associated injury is associated with an increased risk of amputation, particularly an extremity DSTI with an underlying bone fracture. Based on the above, we categorize DSTIs based on anatomic level of injury and propose a systematic approach to the

reconstruction of DSTIs, which may be utilized by plastic surgeons and other surgical services to aid in the care of these complex injuries.

**Ivo A Pestana, MD**

Department of Plastic and Reconstructive Surgery  
Wake Forest University  
Medical Center Boulevard  
Winston-Salem, NC 27157  
E-mail: [ipestana@wakehealth.edu](mailto:ipestana@wakehealth.edu)

## ACKNOWLEDGEMENT

The author acknowledges Greg Russell for aid in the statistics section of this article.

## REFERENCES

- Morris M, Schreiber MA, Ham B. Novel management of closed degloving injuries. *J Trauma*. 2009;67:E121–E123.
- Hakim S, Ahmed K, El-Menyar A, et al. Patterns and management of degloving injuries: a single national level I trauma center experience. *World J Emerg Surg*. 2016;11:35.
- Latifi R, El-Hennawy H, El-Menyar A, et al. The therapeutic challenges of degloving soft-tissue injuries. *J Emerg Trauma Shock*. 2014;7:228–232.
- Arnez ZM, Khan U, Tyler MP. Classification of soft-tissue degloving in limb trauma. *J Plast Reconstr Aesthet Surg*. 2010;63:1865–1869.
- Yan H, Gao W, Li Z, et al. The management of degloving injury of lower extremities: technical refinement and classification. *J Trauma Acute Care Surg*. 2013;74:604–610.
- Khan U, Ho K, Deva A. Exchanging split-skin grafts to reduce donor morbidity in limited pretibial degloving injuries. *Plast Reconstr Surg*. 2004;113:1523–1525.
- DeFranzo AJ, Argenta LC, Marks MW, et al. The use of vacuum-assisted closure therapy for the treatment of lower-extremity wounds with exposed bone. *Plast Reconstr Surg*. 2001;108:1184–1191.
- Stabryła P, Kulińska J, Warchoń Ł, et al. Degloving lower leg injury – the importance of additional treatment: negative pressure and hyperbaric oxygen therapy. *Pol Przegl Chir*. 2018;90:5–9.
- Boernert K, Ganot G, Ulrich MK, et al. Preserving the lower extremity after severe degloving injuries to meet the patient's demand in two cases: (Limb salvage after degloving injury). *Trauma Case Rep*. 2018;15:8–15.
- McGrouther DA, Sully L. Degloving injuries of the limbs: long-term review and management based on whole-body fluorescence. *Br J Plast Surg*. 1980;33:9–24.
- Tseng S, Tornetta P III. Percutaneous management of Morel-Lavallee lesions. *J Bone Joint Surg Am*. 2006;88:92–96.
- Tscherne H, Südkap NP. [Pathophysiology of open fractures and principles of their treatment. Review]. *Acta Chir Orthop Traumatol Cech*. 1990;57:193–212.
- Mello DF, Assef JC, Soldá SC, et al. Degloving injuries of trunk and limbs: comparison of outcomes of early versus delayed assessment by the plastic surgery team. *Rev Col Bras Cir*. 2015;42:143–148.
- Pestana IA, Coan B, Erdmann D, et al. Early experience with fluorescent angiography in free-tissue transfer reconstruction. *Plast Reconstr Surg*. 2009;123:1239–1244.
- Losken A, Styblo TM, Schaefer TG, et al. The use of fluorescein dye as a predictor of mastectomy skin flap viability following autologous tissue reconstruction. *Ann Plast Surg*. 2008;61:24–29.
- Newman MI, Samson MC, Tamburrino JF, et al. Intraoperative laser-assisted indocyanine green angiography for the evaluation of mastectomy flaps in immediate breast reconstruction. *J Reconstr Microsurg*. 2010;26:487–492.
- Gurtner GC, Jones GE, Neligan PC, et al. Intraoperative laser angiography using the SPY system: review of the literature and recommendations for use. *Ann Surg Innov Res*. 2013;7:1.
- Green JM III, Sabino J, Fleming M, et al. Intraoperative fluorescence angiography: a review of applications and outcomes in war-related trauma. *Mil Med*. 2015;180(3 suppl):37–43.
- Mothes H, Dönicke T, Friedel R, et al. Indocyanine-green fluorescence video angiography used clinically to evaluate tissue perfusion in microsurgery. *J Trauma*. 2004;57:1018–1024.
- Guo S, Dipietro LA. Factors affecting wound healing. *J Dent Res*. 2010;89:219–229.
- Castillo RC, Bosse MJ, MacKenzie EJ, et al; LEAP Study Group. Impact of smoking on fracture healing and risk of complications in limb-threatening open tibia fractures. *J Orthop Trauma*. 2005;19:151–157.
- Bosse MJ, MacKenzie EJ, Kellam JF, et al. An analysis of outcomes of reconstruction or amputation after leg-threatening injuries. *N Engl J Med*. 2002;347:1924–1931.
- Gustilo RB, Mendoza RM, Williams DN. Problems in the management of type III (severe) open fractures: a new classification of type III open fractures. *J Trauma*. 1984;24:742–746.
- Norris BL, Kellam JF. Soft-tissue injuries associated with high-energy extremity trauma: principles of management. *J Am Acad Orthop Surg*. 1997;5:37–46.
- DeFranzo AJ, Marks MW, Argenta LC, et al. Vacuum-assisted closure for the treatment of degloving injuries. *Plast Reconstr Surg*. 1999;104:2145–2148.
- Jeng SF, Hsieh CH, Kuo YR, et al. Technical refinement in the management of circumferentially avulsed skin of the leg. *Plast Reconstr Surg*. 2004;114:1225–1227.
- Graham GP, Helmer SD, Haan JM, et al. The use of Integra dermal regeneration template in the reconstruction of traumatic degloving injuries. *J Burn Care Res*. 2003;34:269.
- Dini M, Quercioli F, Mori A, et al. Vacuum-assisted closure, dermal regeneration template and degloved cryopreserved skin as useful tools in subtotal degloving of the lower limb. *Injury*. 2012;43:957–959.
- Reynolds M, Kelly DA, Walker NJ, et al. Use of Integra in the management of complex hand wounds from cancer resection and nonburn trauma. *Hand (NY)*. 2018;13:74–79.
- Ivanov PA, Shibaev EU, Nevedrov AV, et al. Emergency soft tissue reconstruction algorithm in patients with open tibia fractures. *Open Orthop J*. 2016;10:364–374.