

# Case Report of Diagnostic Evidence Depicting Palmaris Longus Origin Reversal: Ultrasound and MRI Evaluation

Jesse A. Raszewski<sup>1</sup>, H. Brent Bamberger<sup>2</sup>

## Learning Point of the Article:

Although rare, anatomic muscle variants will be encountered in orthopedic practice. With proper history gathering and diagnostic imaging, treatment can be guided to lead to patient satisfaction and improved outcomes.

## Abstract

**Introduction:** The palmaris longus (PL) is very prone to anatomical variance. It may exhibit agenesis, reversal, and duplication. The reversal variant presents with the PL tendinous aspect proximally and the muscle belly distally. It is an important finding, and it is important to consider when making a differential diagnosis. This is the only reported case of a left distal forearm PL muscle variant with ultrasound and magnetic resonance imaging (MRI) in a Caucasian adult male.

**Case Report:** A 28-year-old Caucasian male presented to the clinic with an abnormal ultrasound finding of a left wrist mass. The patient was instructed to get an MRI, which demonstrated and further confirmed the reversed PL muscle.

**Conclusion:** Although rare, anatomic muscle variance may occur in many places of the body leading to symptoms that need attention. These variants should be considered in orthopedic differential diagnosis and ruled out appropriately with proper diagnostic techniques. By making the correct diagnosis, it leads to improved patient outcomes and satisfaction both conservatively and surgically.

**Keywords:** Palmaris longus, anatomic variant, forearm musculature, forearm flexor.

## Introduction

There are many cases of anatomical variance in the musculature of the upper extremity (UE). The fusiform palmaris longus (PL) muscle is prone to variance, and in order of prevalence; the completely absent is the most common, followed by the reverse, duplicated, bifid or hypertrophied form [1]. Opposite to normal anatomy, the reversed PL exhibits a proximal tendinous structure and a muscle belly distally [1]. A recent meta-analysis from 1975 to 2014 reported that there is only one medical record of magnetic resonance imaging (MRI) displaying the reversed PL [2]. The present report describes a case of a reversed PL diagnosed with ultrasound and MRI, with a literature review to demonstrate the vast spectrum of variation seen in the musculature of the UE.

## Case Report

A right hand dominant, 28-year-old Caucasian male presented to the orthopedic associates of Southwest Ohio as a referral to a hand specialist due to an abnormal ultrasound finding and left wrist mass. The ultrasound of the suspected left wrist mass was executed 10 days prior, exhibiting increased echogenicity within the musculature of the left distal wrist at the site of the patient's reported abnormality. This echogenicity was asymmetric when compared to the right wrist. The image of the left anterior distal forearm on ultrasound is displayed in Fig. 1. There was no evidence of a focal mass or fluid collection according to the ultrasound report. The patient presented complaining of left wrist swelling, with no pain. There was an unremarkable past medical, surgical, or family history significant to the chief complaint. As far as a differential, the

## Author's Photo Gallery



Dr. Jesse A. Raszewski



Dr. H. Brent Bamberger

Access this article online

Website:  
www.jocr.co.in

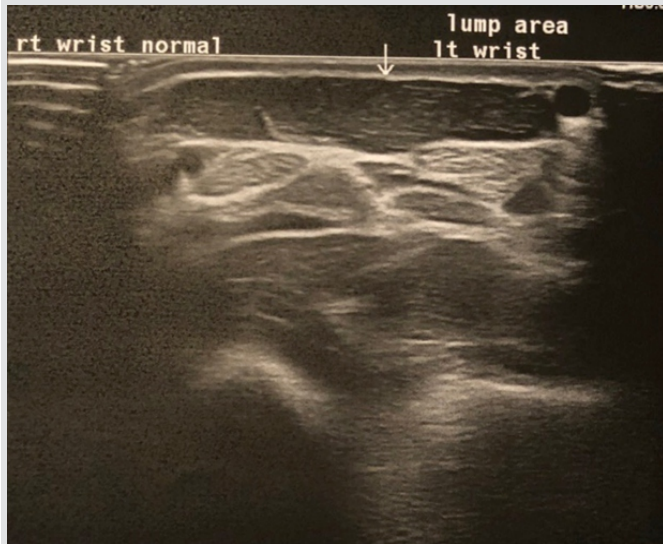DOI:  
10.13107/jocr.2250-0685.1538

<sup>1</sup>Department of Orthopaedics, Kettering Health Network – Grandview Medical Center, 405 W. Grand Ave., Dayton, OH 45405, United States,  
<sup>2</sup>Department of Orthopaedics, Orthopedic Associates of SW Ohio, 7677 Yankee St, Suite 110 Centerville, OH 45459, United States.

### Address of Correspondence:

Dr. Jesse A Raszewski,  
Department of Orthopaedics, Kettering Health Network – Grandview Medical Center, 155 Delano Drive, Pittsburgh, PA 15236, United States.  
E-mail: jar81189@gmail.com



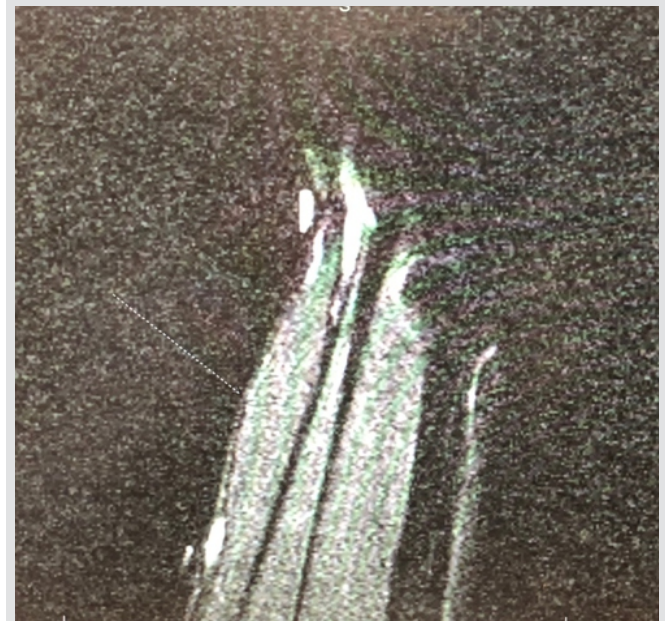


**Figure 1:** Demonstrated on ultrasound imaging 1 month before the initial follow-up to presenting surgeon/ultrasound of the left anterior wrist area.

questionable echogenicity within the musculature of the left distal forearm could have been related to a mild non-specific myositis. Moreover, there was no evidence of focal mass or fluid collection, so an MRI was considered to rule out a neoplasm.

The patient completed the MRI in 10 days, and then followed up in a week to the clinic. The current status of the patient remained unchanged. The MRI of the patient demonstrated a palpable abnormality secondary to a congenital variation consisting of a PL muscle variant due to an accessory muscle belly volar to the flexor tendons. The signal intensity of this muscle appears within normal limits. This finding was confirmed on the retrospective review of the prior ultrasound. The abnormal muscle variant is displayed in the sagittal view T1 MRI in (Fig. 2), it is displayed in the coronal view T1 MRI in (Fig. 3), and it is displayed in the coronal view T2 MRI in (Fig. 4).

After consecutive diagnostic imaging techniques ruled out anything pathologic including neoplasm, the patient was



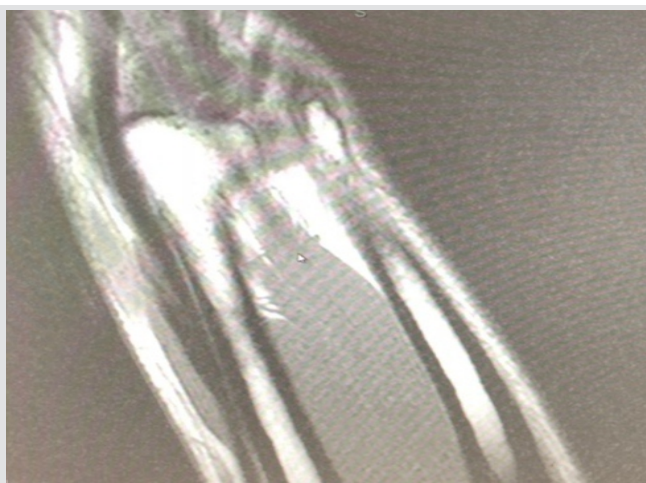
**Figure 2:** Sagittal view of the anterior left forearm mass demonstrating the muscle variant on magnetic resonance imaging (MRI) T1 without contrast 10 days after physical exam/MRI of the left upper extremity sagittal view.

counseled on the plan. Since the muscle variant was not painful and it did not limit functional outcomes, a non-operative conservative plan was instituted. The patient was informed to follow-up as needed, and if any concerning symptoms arose to schedule an appointment and new measures would be taken for continued care.

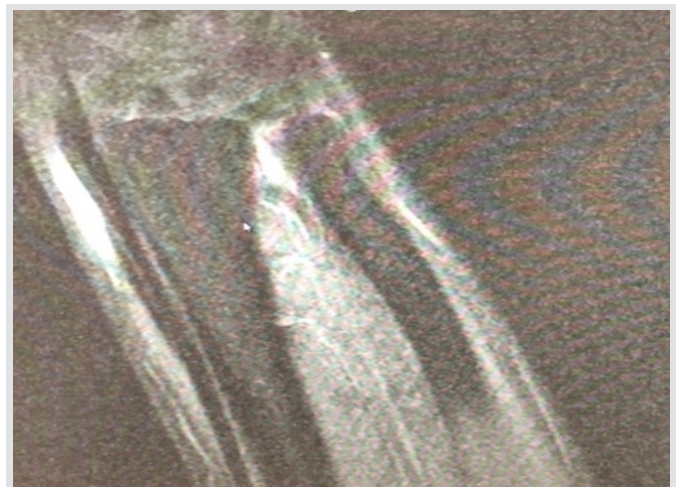
In the present case, the PL muscle belly originated at the distal forearm volar to the flexor digitorum profundus and superficialis tendons. The abnormality lied between the soft tissue markers placed at the site of the patient’s complaint of the palpable abnormality.

### Discussion

The standard anatomical origin of the PL is located on the



**Figure 3:** Coronal view of the anterior left forearm mass demonstrating the muscle variant on magnetic resonance imaging T1 without contrast 10 days after physical exam/MRI of the anterior left forearm coronal cut T1.



**Figure 4:** Coronal view of the anterior left forearm mass demonstrating the muscle variant on magnetic resonance imaging T2 without contrast 10 days after physical exam/MRI of the anterior left forearm coronal cut T2.



medial epicondyle at the common flexor tendon, and the insertion is the palmar aponeurosis located volarly to the flexor retinaculum [1]. The PL tendon and the palmar aponeurosis are described as two separate entities based on their origin and development [3]. Neurovascularly, it is supplied by branches of the ulnar artery and innervated by branches of the median nerve [4].

This patient is a 28-year-old Caucasian male that presented with a left distal forearm PL muscle variant. Reimann et al. conducted the first major study that looked at 1600 UEs and the incidence of PL variations, and it showed that there were only three aberrancies of the attachment of the muscle in the 540 consecutive arms [5]. Moreover, Olewnik et al. created a classification system that described nine different types of anatomical presentations of the PL [6]. The patient's abnormality presented with the muscle belly distally and tendinous portion proximally, which is described as the Type VI variant and is only identified in 2% of cases [6].

The clinical significance of this case is placed on the nervous systems implications. Proximal muscle belly PL variants may predispose patients to median nerve compression [6]. Although it is much less common, compression of the ulnar nerve in Guyon's canal has been reported as well [7]. Patients may also present with distal forearm edema and inflammation that may result in reduction of hand function due to wrist

flexion movements [8].

It is important to understand anatomical variants of the PL and to incorporate into the differential diagnosis list because it plays a crucial role in reconstructive surgeries [9]. It is essential to clinically examine patients that present with an anterior distal forearm mass with suitable diagnostic techniques to avoid inappropriate surgical procedures.

### Conclusion

This is a case report of a patient exhibiting symptoms from the reversed PL muscle in the forearm. Anatomical muscle variants should be considered in a differential diagnosis when there is an unknown muscular mass in a patient. Due to the minimal number of case reports on anatomical muscle variation, we suggest that with appropriate diagnostic techniques and proper management of such cases, it can lead to improved patient outcomes and satisfaction.

### Clinical Message

With appropriate history and diagnostic techniques, considering anatomic muscle variants in your differential diagnosis can lead to improved patient outcomes and satisfaction.

### References

1. Murabit A, Gnarra M, Mohamed A. Reversed palmaris longus muscle: Anatomical variant case report and literature review. *Can J Plast Surg* 2013;21:55-6.
2. Ioannis D, Anastasios K, Konstantinos N, Lazaros K, Georgios N. Palmaris longus muscle's prevalence in different nations and interesting anatomical variations: Review of the literature. *J Clin Med Res* 2015;7:825-30.
3. Caughell KA, McFarlane RM, McGrouther DA, Martin AH. Developmental anatomy of the palmar aponeurosis and its relationship to the palmaris longus tendon. *J Hand Surg Am* 1988;13:485-93.
4. Wafae N, Itezerote AM, Laurini Neto H. Arterial branches to the palmaris longus muscle. *Morphologie* 1997;81:25-8.
5. Reimann AF, Daseler EH, Anson BJ, Beaton LE. The palmaris longus muscle and tendon. A study of 1600 extremities. *Anat Rec* 1944;89:495-505.
6. Olewnik Ł, Waśniewska A, Polguy M, Podgórski M, Łabętowicz P, Ruzik K, et al. Morphological variability of the palmaris longus muscle in human fetuses. *Surg Radiol Anat* 2018;40:1283-91.
7. Regan PJ, Roberts JO, Bailey BN. Ulnar nerve compression caused by a reversed palmaris longus muscle. *J Hand Surg Br* 1988;13:406-7.
8. Park MJ, Namdari S, Yao J. Anatomic variations of the palmaris longus muscle. *Am J Orthop (Belle Mead NJ)* 2010;39:89-94.
9. Sebastin SJ, Lim AY, Bee WH, Wong TC, Methil BV. Does the absence of the palmaris longus affect grip and pinch strength? *J Hand Surg Br* 2005;30:406-8.

**Conflict of Interest:** Nil  
**Source of Support:** Nil

**Consent:** The authors confirm that Informed consent of the patient is taken for publication of this case report

### How to Cite this Article

Raszewski JA, Bamberger B. Case Report of Diagnostic Evidence Depicting Palmaris Longus Origin Reversal: Ultrasound and MRI Evaluation. *Journal of Orthopaedic Case Reports* 2019 Sep-Oct; 9(5):67-69.