

Available online at www.sciencedirect.com

ScienceDirect

journal homepage: www.elsevier.com/locate/radcr

Case report

Retroperitoneal liposarcoma mimicking pheochromocytoma [☆]

Fidel Rampersad, MBBS, DM Radiology, FRCR^{a,*}, Jason Diljohn, MBBS^b, Surujpal Teelucksingh, MBBS, PhD, FRCP(E)^c, Wesley Greaves, MD, America Board certification in Anatomic and Clinical Pathology at Brown University, Hematopathology and Molecular Genetics Pathology at MD Anderson Cancer Center^d, Dilip Dan, MBBS, FACS, ABS RECERTIFIED, Professor of Minimally Invasive Surgery^e

^aRadiology Unit, Department of Clinical Medical Sciences, The University of the West Indies, St Augustine Campus, Trinidad, West Indies

^bThe University of the West Indies, St Augustine Campus, Trinidad, West Indies

^cDepartment of Clinical Medicine Sciences, The University of the West Indies, St Augustine Campus, Trinidad, West Indies

^dNexgen Pathology Services Limited, San Juan, Trinidad and Tobago, Puerto Rico

^eDepartment of Clinical Surgical Sciences, The University of the West Indies, St Augustine Campus, Trinidad, West Indies

ARTICLE INFO

Article history:

Received 14 February 2021

Revised 13 March 2021

Accepted 17 March 2021

Keywords:

Retroperitoneal liposarcoma

Pheochromocytoma

ABSTRACT

Retroperitoneal liposarcomas are rare mesenchymal tumors which carry a poor prognosis because of their late presentation. When symptoms do occur, they are usually nonspecific and related to mass effect or invasion of local structures. Rarely, retroperitoneal liposarcomas can clinically and biochemically mimic pheochromocytomas. We discuss one such case of a 56-year-old Afro-Trinidadian female who presented to her primary care physician with a 3-month history of weakness, intermittent sweating, difficulty sleeping and elevated blood pressure. After a 2 week trial of an oral antihypertensive regime her blood pressure was still elevated and she complained of new right sided abdominal pain. A subsequent Computed Tomography scan of her abdomen revealed an enhancing, heterogeneous right suprarenal mass suspicious for pheochromocytoma. Urinary catecholamines were also elevated and an MRI of her abdomen supported the diagnosis of pheochromocytoma although intralesional fat was noted, an uncommon feature of pheochromocytomas. She was booked for laparoscopic adrenalectomy. Histological analysis of the resected specimen confirmed a dedifferentiated retroperitoneal liposarcoma. While the imaging features of pheochromocytomas and retroperitoneal liposarcomas can be similar, the presence of intralesional fat on CT and MRI should favour the diagnosis of a retroperitoneal liposarcoma, albeit the clinical and biochemical picture.

[☆] Competing Interests: The authors have declared that no competing interests exist.

* Corresponding author. Fidel Rampersad

E-mail address: fidelrampersad@gmail.com (F. Rampersad).

<https://doi.org/10.1016/j.radcr.2021.03.033>

1930-0433/© 2021 The Authors. Published by Elsevier Inc. on behalf of University of Washington. This is an open access article under the CC BY-NC-ND license (<http://creativecommons.org/licenses/by-nc-nd/4.0/>)

© 2021 The Authors. Published by Elsevier Inc. on behalf of University of Washington.
This is an open access article under the CC BY-NC-ND license
(<http://creativecommons.org/licenses/by-nc-nd/4.0/>)

Introduction

Liposarcomas are malignant tumors of mesenchymal origin that can arise from any fat containing region, including the retroperitoneum. They are the most common sarcoma of the retroperitoneum with a frequency of 41% followed by leiomyosarcoma and malignant fibrous histiocytoma [1]. In the retroperitoneum about 35% arise in the perinephric fat [2]. Histologically, liposarcomas are divided into five types including: well-differentiated, dedifferentiated, myxoid/round cell, pleomorphic and mixed. The well-differentiated type occurs most frequently while the dedifferentiated and pleomorphic types are aggressive with metastases often seen at presentation. Rarely, they may mimic a pheochromocytoma. We contribute one more such case to the literature.

Case report

A previously well 56-year-old Trinidadian female of African descent presented to her primary care physician with a three-month history of weakness, intermittent sweating and difficulty sleeping. Her blood pressure was found to be elevated (usually above 170/100 mm Hg) and she was started on enalapril 10 mg and nifedipine sustained release 20 mg daily. Two weeks later, her blood pressure were still uncontrolled and remained markedly elevated, and there was a new complaint of right upper quadrant abdominal pain. Physical exam was unremarkable with no palpable abdominal masses. A Computed Tomography (CT) scan of her abdomen and pelvis with IV contrast was requested which demon-

strated a heterogeneous, avidly enhancing, right suprarenal mass (Figs 1 and 2). An MRI of her abdomen and urine catecholamines (24-hour 5-hydroxyindoleacetic acid [5-HIAA] and 24-hour metanephrine) were requested to investigate for possible pheochromocytoma. The MRI revealed an intermediate T1, mildly hyperintense T2, right suprarenal mass with heterogeneous enhancement post IV gadolinium (Figs. 3, 4 and 5). Foci of signal dropout were visualized on the out of phase sequences consistent with intralesional fat (Fig. 6). The right adrenal gland was seen in close relation to this mass. Urinary metanephrine was marginally elevated at 218 microgram/24 h (reference range:36-209 microgram/24 h) as was 5-HIAA at 22.7 mg/24 h (reference range:0-14.9 mg/24h). Though the presence of intralesional fat is uncommon for pheochromocytomas, the clinical presentation and elevated urine catecholamines supported pheochromocytoma as the primary differential diagnosis. The patient was referred for preoperative medical management with an alpha blocker (terazosin 2 mg nocte), followed by beta blocker (propranolol 10 mg bid) with good effect such that her blood pressure rarely exceeded 125/75 mmHg in the 2-week interval from surgery. Laparoscopic adrenalectomy was then performed with initial control of the right adrenal vein. There was no typical drop in the blood pressure once this was done. Slight bleeding was encountered laterally and superiorly with subsequent removal of the perinephric fat pad for control. The patient was discharged on post-op day 1. Histological examination of the resected specimen revealed a dedifferentiated liposarcoma (Fig. 7) with positive resection margins. There was no histological evidence of pheochromocytoma and the right adrenal gland was normal. Interestingly, there was no further need for antihypertensive medications even after 6 weeks of having surgery and her abdominal pain

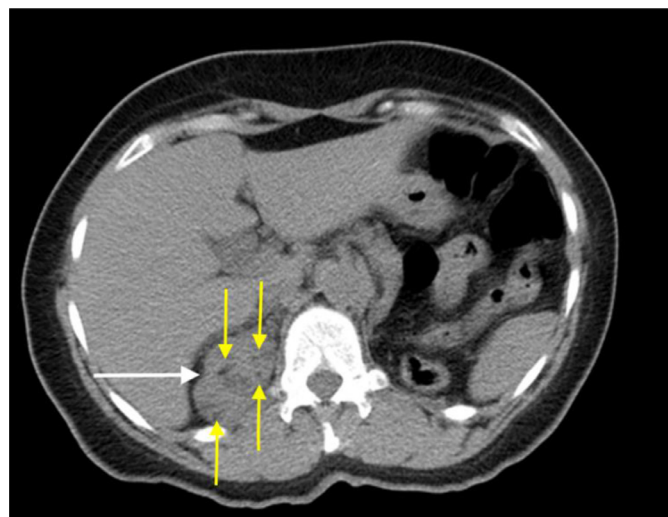


Fig. 1 – Axial non contrast CT image showing a well circumscribed soft tissue density right suprarenal mass (white arrow) containing a few tiny hypodense foci within (yellow arrows). No calcifications were visualised (colour version of figure is available online).

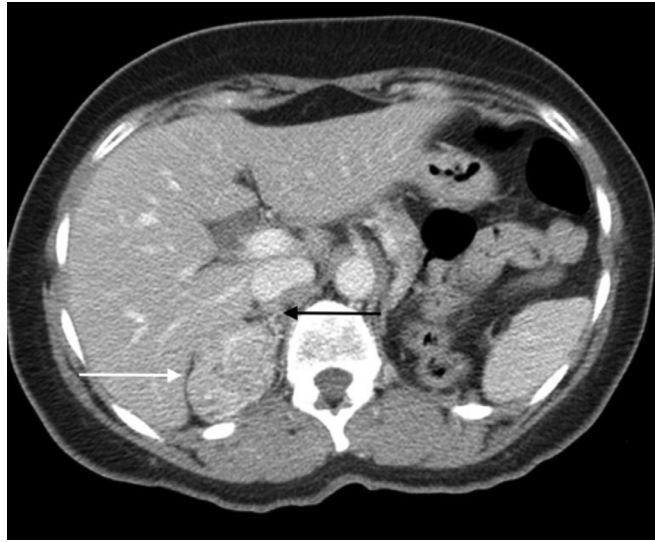

Fig. 2 – Arterial phase post IV contrast CT imaged demonstrating marked hypervascularity of the right suprarenal mass (white arrow), which is separate from the posterior segment of the right lobe of liver and the right adrenal gland (black arrow).

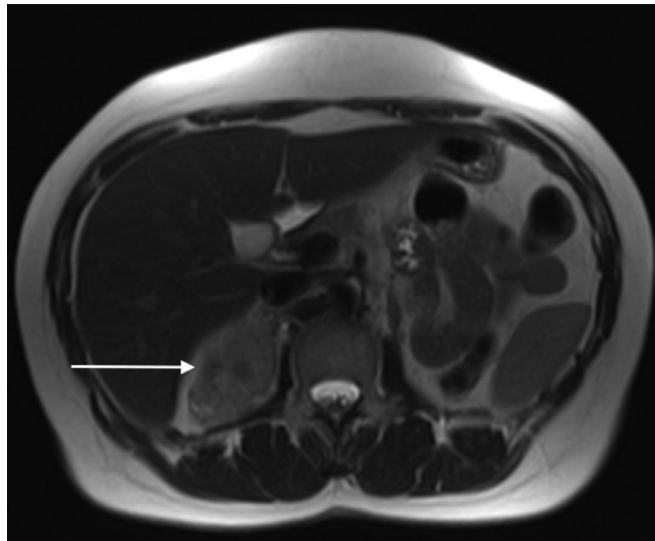


Fig. 3 – Axial T2 weighted MRI image showing a well-circumscribed, heterogenous, mildly hyperintense right suprarenal lesion (white arrow).

resolved. A post-op CT demonstrated a non-enhancing right suprarenal soft-tissue density, suggestive of post-operative changes (Fig. 8).

Discussion

Retroperitoneal liposarcomas are a subtype of liposarcomas originating from retroperitoneal fat. They occur at any age but tend to occur most frequently in the sixth and seventh decades of life with no gender or sex predilection [3]. The large potential space of the retroperitoneum allows retroperi-

toneal liposarcomas to grow quite big before presenting with symptoms. When symptoms do occur, they are usually non-specific and include abdominal and flank pain, early satiety, and lower limb swelling and pain [4]. Neurological, musculoskeletal and obstructive symptoms can occur secondary to local invasion or compression of adjacent structures [4]. Our presentation of a retroperitoneal liposarcoma mimicking a pheochromocytoma with markedly elevated blood pressures, elevated urine catecholamines and suggestive imaging features is uncommon but previously documented by Marmouch H et al. [5]. Dedifferentiated liposarcomas have been shown to present with elevated catecholamines, and demonstrate somatostatin receptors both on imaging (somatostatin receptor

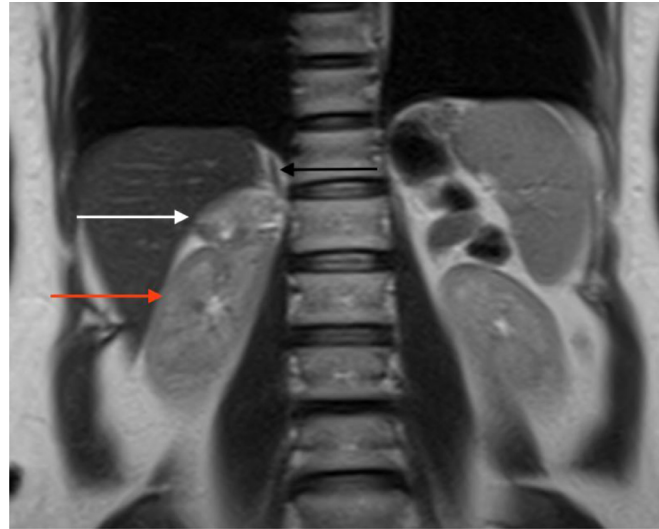


Fig. 4 – Coronal T2 weighted MRI image demonstrating the relationship of the right suprarenal mass (white arrow) to the right kidney (red arrow), right adrenal gland (black arrow) and the right lobe of the liver (colour version of figure is available online).

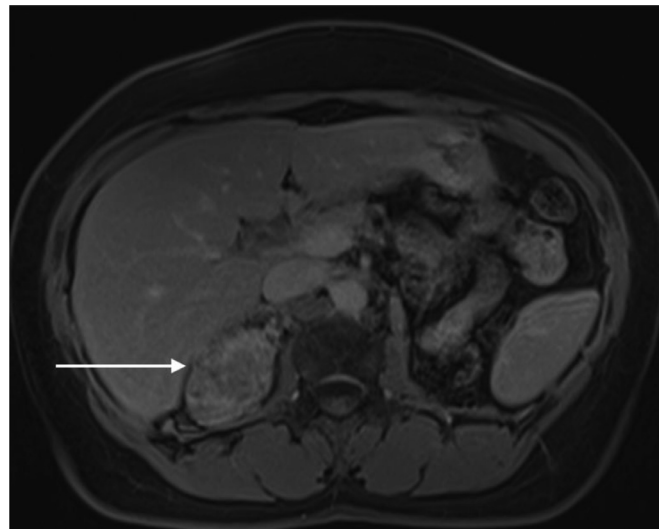


Fig. 5 – Axial T1 weighted post IV gadolinium MRI image demonstrating hypervascularity and heterogeneous enhancement within the right suprarenal mass (white arrow).

scintigraphy) and histopathology (reverse transcription polymerase chain reaction) [6].

CT is used for the diagnosis, staging and preoperative evaluation of liposarcomas. On CT, these tumors contain fat and varying degrees of soft tissue. Low grade liposarcomas contain mostly fat and very little soft tissue, intermediate-grade tumors are relatively lucent with transverse septations and higher-grade sarcomas are dense, heterogenous and enhance with IV contrast [4]. Our case of a dedifferentiated liposarcoma appeared as a heterogenous, enhancing soft tissue density mass with a few small fatty foci. Calcifications were not present but when visualized are associated with a poor prognosis [4]. CT can also be used to determine invasion of adjacent structures, assess regional lymph node status and de-

termine the presence of liver and lung metastases. MRI is used in cases of an indeterminate retroperitoneal mass and to also determine neurovascular invasion. Abdominal ultrasound when done, demonstrates a hyperechoic mass but fails to separate retroperitoneal liposarcomas from other retroperitoneal masses. CT and ultrasound may be used to guide percutaneous biopsy but histopathological examination of the surgical specimen remains the gold standard [7,8].

Management of retroperitoneal liposarcomas is wide local excision with negative resection margins. En bloc resection can however be challenging when the tumor encases vital structures such as the great vessels. A balance between removing tumor and patient safety should therefrom form the basis of surgical management in such cases. Attempts at

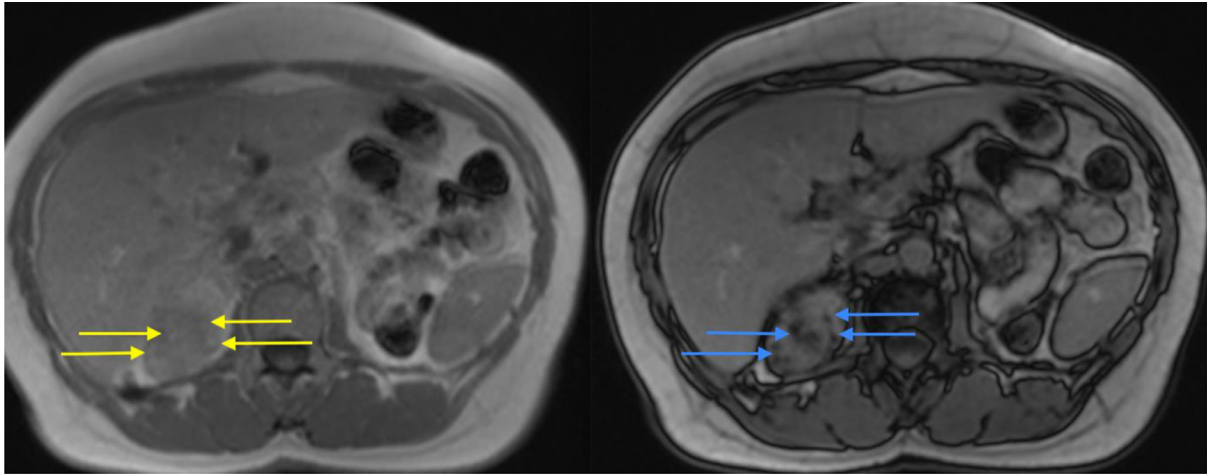


Fig. 6 – Axial T1 in-phase (left) and out-of-phase (right) MR images revealing high T1 signal foci within the right suprarenal mass (yellow arrows) in the in-phase image, which demonstrate signal drop out (blue arrows) in the out-of-phase image, consistent with intralesional fat (colour version of figure is available online).

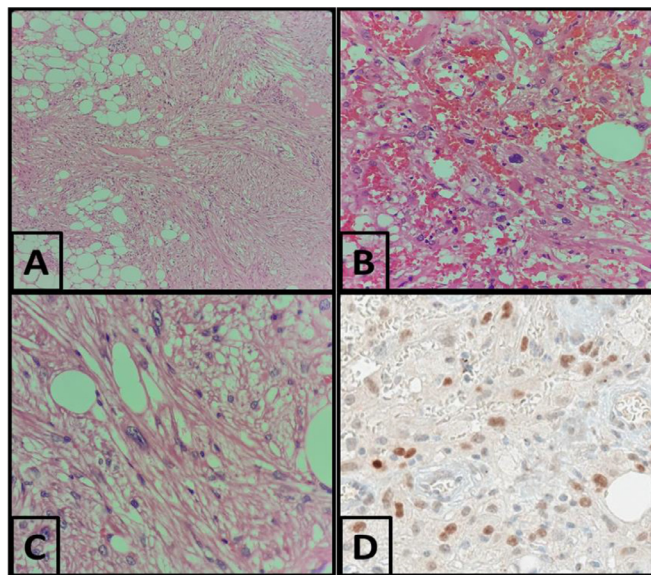


Fig. 7 – A (40x), B (100x), and C (400x)- microscopic images showing a low grade lipomatous tumor admixed with high grade spindle sarcoma (H&E). D (100x)- Immunohistochemical stain for MDM2 highlighting nuclear staining in the tumor cells, thus confirming a diagnosis of liposarcoma.

neoadjuvant chemotherapy have proven useless [9]. Haas RL et al. concluded that perioperative radiotherapy has been associated with better local control but level I evidence is still required [10]. An open approach is generally preferred by most surgeons because of tumor bulk and the need to removal adjacent organs. Today with growing expertise in minimally invasive surgery, a laparoscopic approach can be used in very selected patients with limited disease which would offer reasonable vision of the surgical field, less post-operative pain and better cosmesis [11]. Poor prognosis is seen in cases with a positive resection margin, higher-grade tumors, and multifocal disease. High-grade tumors are also associated with higher

local recurrence rates and distant metastases. The recurrence rate of dedifferentiated tumors is about 80% [9,12]. The five-year survival rate of low-grade well differentiated and myxoid tumors is 90% while the 5 year survival rate of high-grade pleomorphic, round cell and dedifferentiated tumors is 30%-50%, 60% and 75% respectively [4]. Our patient will receive a follow up MRI scan in 3 months and further surgery determined as necessary.

In conclusion, although unusual, retroperitoneal liposarcomas can rarely mimic a pheochromocytoma. Typically retroperitoneal liposarcomas produce symptoms, when large, secondary to mass effect and invasion of adjacent struc-

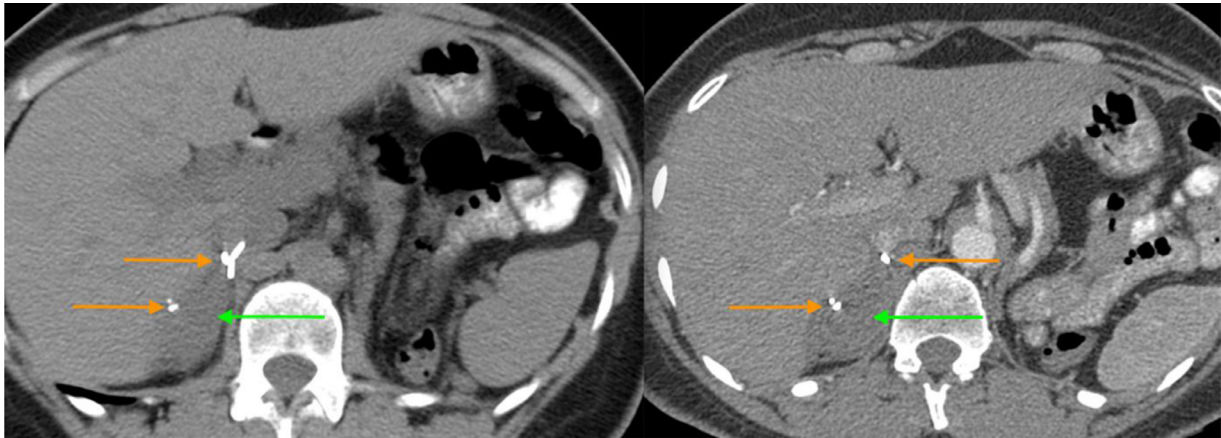


Fig. 8 – Post-operative CT images through the upper abdomen, pre and post IV contrast, with surgical staples (orange arrows), demonstrating non-enhancing right suprarenal soft-tissue density (green arrows), suggestive of post-operative changes (colour version of figure is available online).

tures. While imaging features of pheochromocytomas and retroperitoneal liposarcomas can be similar, the presence of intralesional fat on CT and MRI should favour diagnosis of the latter, despite the clinical and biochemical picture.

Patient consent

Informed consent was obtained from the patient to use her information in this manuscript.

REFERENCES

- [1] Herrera-Gómez Á, Ortega-Gutiérrez C, Betancourt AM, Luna-Ortiz K. Giant retroperitoneal liposarcoma. *World Journal of Surgical Oncology*. 2008;6(1):115 Dec.
- [2] Gupta TK. Tumors and tumor-like conditions of the adipose tissue. *Current problems in surgery* 1970 Mar 1;7(3):3–60.
- [3] Chouairy CJ, Abdul-Karim FW, MacLennan GT. Retroperitoneal liposarcoma. *The Journal of urology* 2007;177(3):1145 Mar.
- [4] Vijay A, Ram L. Retroperitoneal liposarcoma. *American journal of clinical oncology* 2015 Apr 1;38(2):213–19.
- [5] Marmouch H, Trabelsi A, Ach K, Maaroufi A, Chaieb L. Retroperitoneal liposarcoma mimicking pheochromocytoma. *Pathologica* 2008 Dec 1;100(6):470–2.
- [6] Imperiale A, Chenard MP, Rohr S, Barlier A, Goichot B. In vivo and in vitro evidence of somatostatin receptors expression in a dedifferentiated retroperitoneal liposarcoma. *Clinical nuclear medicine* 2014;39(10):892–3 Oct.
- [7] Fletcher CD, Akerman M, Dal Cin P, De Wever I, Mandahl N, Mertens F, et al. Correlation between clinicopathological features and karyotype in lipomatous tumors. A report of 178 cases from the Chromosomes and Morphology (CHAMP) Collaborative Study Group. *Am J Pathol* 1996;148:623–30.
- [8] Kraus MD, Guillou L, Fletcher CD. Well-differentiated inflammatory liposarcoma: an uncommon and easily overlooked variant of a common sarcoma. *Am J Surg Pathol* 1997;21:518–27.
- [9] Pisapia A, Crolla E, Saggiocolo RA, Perrella A, Molino C. Preoperative diagnosis and surgical treatment for giant retroperitoneal liposarcoma: a case report. *Int J Surg Case Rep* 2019;57:179–82. doi:10.1016/j.ijscr.2019.04.003.
- [10] Haas RL, Bonvalot S, Miceli R, Strauss DC, Swallow CJ, Hohenberger P, et al. Radiotherapy for retroperitoneal liposarcoma: a report from the Transatlantic Retroperitoneal Sarcoma Working Group. *Cancer* 2019 Apr 15;125(8):1290–300.
- [11] Agrusa A, Di Buono G, Buscemi S, Randisi B, Gulotta L, Sorce V, et al. Dedifferentiated retroperitoneal large liposarcoma and laparoscopic treatment: Is it possible and safe? The first literature case report. *International Journal of Surgery Case Reports* 2019 Jan 1;57:113–17.
- [12] Crago AM, Dickson MA. Liposarcoma: multimodality management and future targeted therapies. *Surg Oncol Clin N Am* 2016;25:761–73.