

Contents lists available at [ScienceDirect](http://www.sciencedirect.com)

International Journal of Surgery Case Reports

journal homepage: www.casereports.com

An unusual anterior dislocation of fractured mandibular condyle leading to psuedo-ankylosis in a 8 yr old child—A distinct case report



Ranjit Kumar P. (Dr., MDS)^{a,*}, Naveen G. (Dr., MS, Asst. Prof.)^b, Raja Satish P. (Dr., MDS)^c, Srinivas Chakravarthy P. (Dr., MDS, Prof.)^d, L. Krishna Prasad (Dr., Prof., HOD)^e

^a Department of Oral & Maxillofacial Surgery, Sibar Institute of Dental Sciences, Takkellapadu, Guntur, 522509, Andhra Pradesh, India

^b Department of General Surgery, Katuri Medical College, Chinakondrupadu, Guntur, Andhra Pradesh, India, India

^c Department of Oral & Maxillofacial Surgery, Sibar Institute of Dental Sciences, Takkellapadu, Guntur, 522509, Andhra Pradesh, India

^d Department of Oral & Maxillofacial Surgery, Sibar Institute of Dental Sciences, Takkellapadu, Guntur, 522509, Andhra Pradesh, India

^e Department of Oral & Maxillofacial Surgery, Sibar Institute of Dental Sciences, Takkellapadu, Guntur, 522509, Andhra Pradesh, India

ARTICLE INFO

Article history:

Received 9 May 2016

Received in revised form 9 July 2016

Accepted 10 July 2016

Available online 14 July 2016

Keywords:

Distinct case report

Pseudoankylosis

Temporomandibular joint

Bilateral pediatric condylar fracture

Dislocated

ABSTRACT

INTRODUCTION: Literature reviews are replete with discussions focusing on the incidence, types, and patterns of disruption in TM joint function, besides enumerating and classifying its causes. However, atypical situations do present, such situations warranting a detailed, methodical assessment before therapeutic institution.

PRESENTATION OF CASE: Described here is management of a unique case of post-traumatic pseudo-ankylosis in a 8 year old child that had an old fractured condyle, displaced and dislocated anteriorly into the sigmoid notch, with eventual fusion to the ipsilateral zygomatic arch on its medial side.

DISCUSSION: Although conventional imaging tools still have relevance, but the significance of multi detector CT scan with multiplanar reformation and three dimensional images have a become unequivocally a standard part of assessment of such complex facial injuries regardless of therapeutic setting. The probable explanation for the condylar fracture and unusual anterior dislocation of the condylar segment is also hypothesized.

CONCLUSION: Although Post traumatic ankylosis is common in developing countries like India, distinct cases do present rarely which requires a disciplined approach in the management of such cases.

© 2016 The Author(s). Published by Elsevier Ltd on behalf of IJS Publishing Group Ltd. This is an open access article under the CC BY-NC-ND license (<http://creativecommons.org/licenses/by-nc-nd/4.0/>).

1. Introduction

Kazanjian (1938) classified TMJ ankylosis, according to the site involved, into true (intracapsular) and false/pseudoankylosis (extracapsular). While true ankylosis refers to fibrous or bony ankylosis that occurs between the condylar head of the mandible and the mandibular fossa of the temporal bone, false/pseudo ankylosis refers to restriction of mandibular movement that occurs as result of pathology or physical obstruction that is outside the temporomandibular (TM) joint. Pseudo-ankylosis is less common than true ankylosis [1].

Radiographic examination is a vital diagnostic tool for the diagnosis and management of TMJ ankylosis. Although conventional radiographs such as Orthopantomogram (OPT) and TM joint tomography have been in use, imaging techniques such as computed tomographic (CT) scanning with three-dimensional reconstruction

have been developed and improved. They provide the fine, unobstructed anatomic detail required to guide the surgeons [2].

Any pathology that afflicts the TM joint and restricts the mouth opening carries a mental stigma that overweighs the physical disability posed by the problem in growing children [3].

In reviewing the types and patterns of disruption in TM joint function, we describe a distinct case of pseudo-ankylosis of a low condylar fracture, anteriorly displaced, dislocated, and fused to the zygomatic arch, in an 8-year-old child that sustained an old trauma; the probable mechanism of injury that lead to this unique presentation is also proposed. In addition, the importance of therapy and its implications in TM joint ankylosis are briefly discussed.

2. Case report

An 8 year-old boy, of moderate build and nourishment, accompanied by his father, presented to the department of oral/maxillofacial surgery with reduced mouth opening. Further questioning revealed that two years earlier the boy allegedly met with a Road traffic accident (RTA) – the victim fell flat on his face, chin first, after being hit on the head, while traveling home in an

* Corresponding author.

E-mail address: drranjitkumar_omfs@yahoo.co.in (R.K. P.).

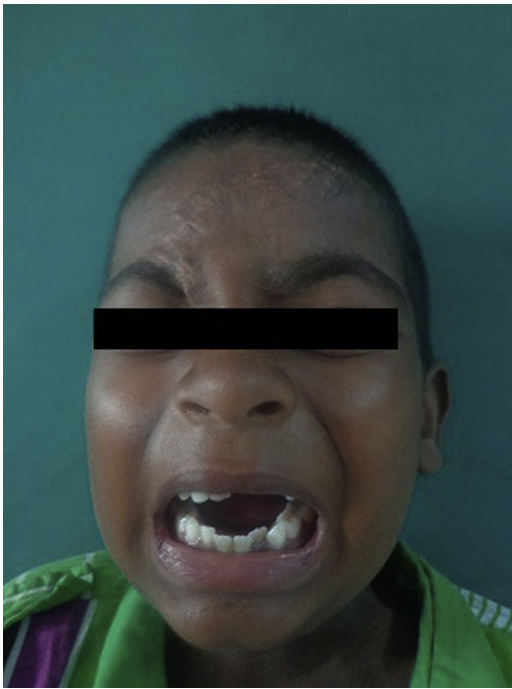

Fig. 1. Pre operative Clinical view showing reduced mouth opening.

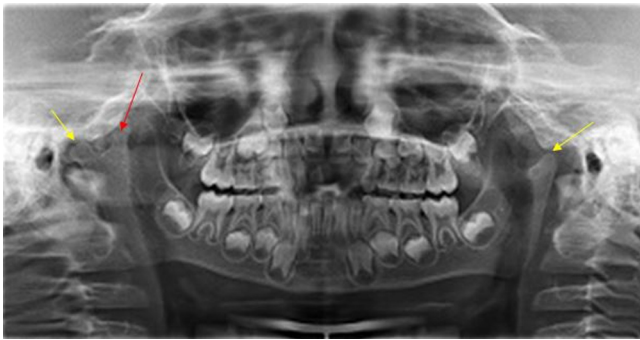

Fig. 2. Pre op OPT showing radio opaque projection in the sigmoid notch (Red arrow) and TM Joint space (Yellow arrow).

auto rickshaw (a public transport vehicle commonly used in India). At the time, he sustained lacerations to his forehead and chin. A little later, the boy developed mild swelling in the right preauricular region, which eventually resolved without any form of intervention. No history of loss of consciousness or bleeding from the ear or nose was reported. There were no other major injuries associated. His medical history was unremarkable. Primary care constituted wound debridement and closure of the forehead laceration at a local primary health centre. As time went by, the boy's father began noticing a progressive reduction in his son's ability to open his mouth (Fig. 1).

Clinically, the patient appeared to have limited mouth-opening – his maximal interincisal distance measured 15 mm, and the chin was mildly retruded. There were extensive scars noted on the forehead and chin. Conventional imaging included an orthopantomogram (OPT) that revealed deformed condylar head on the right side and shortened condyle on the left side which is outside the glenoid fossa. A unique, radiopaque bone-like projection (Red arrow) situated in the right sigmoid notch between the condyle and coronoid process was also observed (Fig. 2).

For further elucidation, and owing to considerable distortion in regional osseous anatomy, computed tomography (CT) with 3D

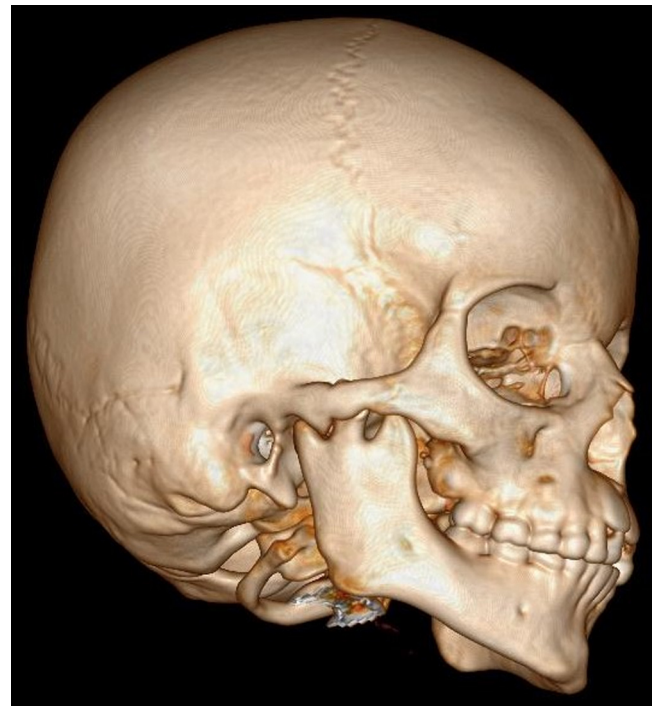

Fig. 3. Pre op 3D CT scan – Lateral/oblique view showing relationship of right condyle and deformed condyle to TMJ and Zygomatic arch.

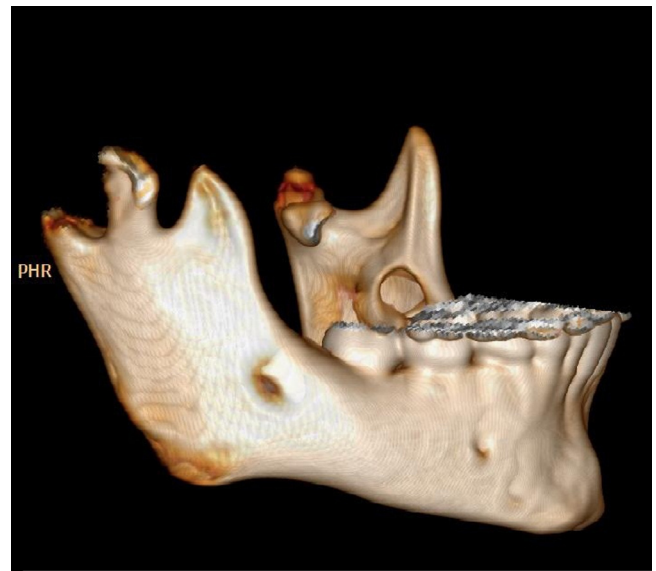


Fig. 4. Pre op 3D CT scan of mandible.

reconstruction was advised. The 156-slice scan revealed an osseous mass fused to the sigmoid notch between the condyle and coronoid process on the right side. Bilaterally, the condyles appeared to be deformed and shortened, reminiscent of an old fracture (Figs. 3 and 4). Axial views survey revealed an osseous mass located just medial to the zygomatic arch (Fig. 5). 3D reconstruction view of the mandible (Fig. 4) shows a shortened, deformed and remodeled condyles on both the sides. There is also fractured anteriorly dislocated condylar stump into the sigmoid notch on the right side. There is also an evidence of an osseous mass on the left side suggestive of a medially displaced fractured condyle. Taken together, a final diagnosis of post-traumatic, pseudo-ankylosis of the TM joint was made, for which surgery was planned.

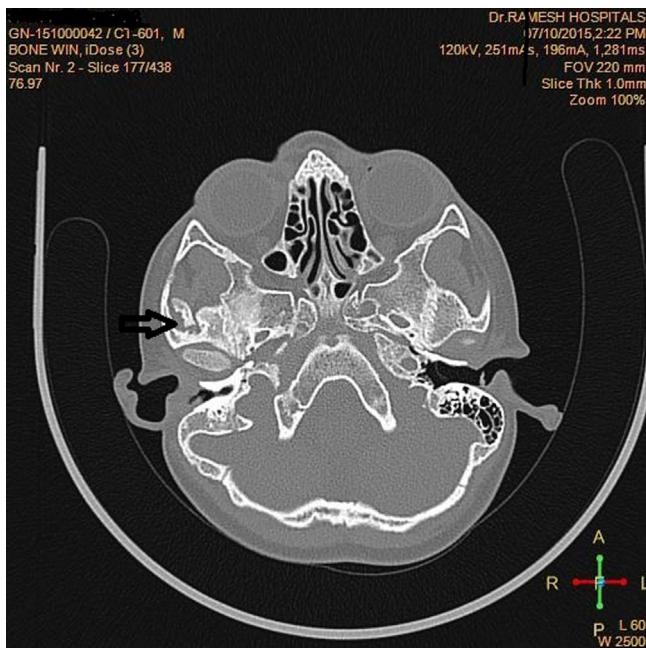


Fig. 5. Pre op CT scan –Axial View showing a bony mass medial to zygomatic arch (Black arrow).

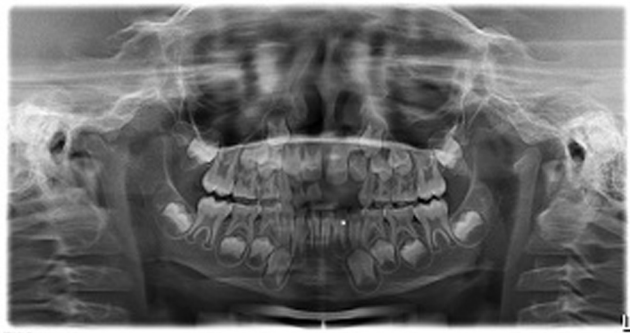

Fig. 6. Post op OPT showing absence of radioopaque mass and coronoidectomy on the right side.

2.1. Surgical procedure

Routine blood investigations revealed anemia Hb-(9.8gm%), nevertheless, the patient was taken up for surgery. Under nasotracheal, hypotensive anesthesia, the right TM joint was exposed via a preauricular incision – the joint had no structural abnormality, however, a bony projection (seen as ‘projection’ on the OPT & CT Scan) from the sigmoid notch loosely ankylosed (Fibrous) just medial to the ipsilateral zygomatic arch was seen. Release of this ankylotic mass was done using a fissure bur, freeing it of all bony and fibrous adhesions (Fig. 6). At first, a 32 mm mouth-opening was successfully achieved using a Hister’s jaw stretcher. To further optimize the intraoperative result, an ipsilateral coronoidectomy was performed so as to facilitate adequate mouth-opening. Primary closure of the incision was done, and patient reversal and recovery were uneventful. The fibrous ankylotic mass was sent for histopathological analysis which revealed proliferating connective tissue with fibroblast transition to osteoblasts and areas of cartilage, osteoid and bone.

Active physiotherapy was instituted on the 2nd post-operative day, and a maximum interincisal opening of 37 mm was achieved and maintained using a Therabite appliance (Fig. 7). The patient also

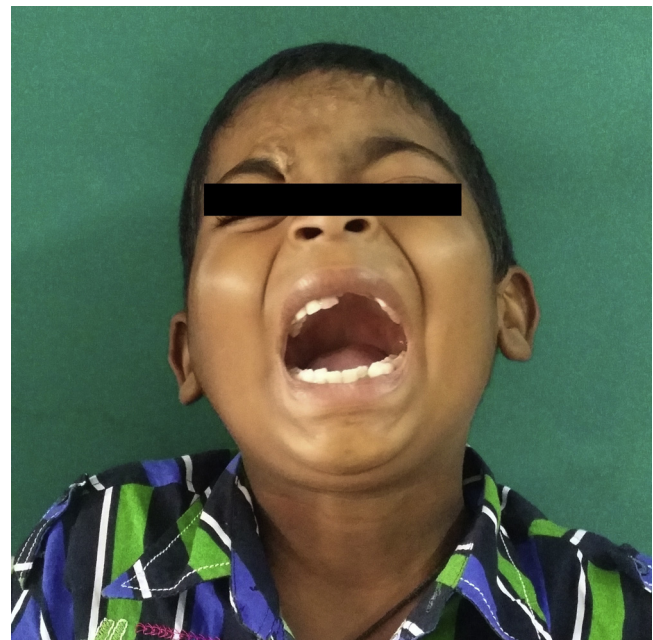

Fig. 7. Post op Clinical View showing significant increased mouth opening.

demonstrated positive outcomes in psychological and nutritional status.

3. Discussion

Many distinctive findings that have been noted in this particular patient are worth discussing. Several case reports [4–6] cite falls as a cause of condylar fractures in children below the age of 6 years, with intracapsular or ‘burst’ fractures being more common than extra capsular fractures [2]. However, in the current case, the patient had sustained trauma at the age of 6 years, and both the patient’s condyles had a ‘low’ (extracapsular) fracture. While a vast majority of mandibular condylar fractures are displaced in an anteromedial or anterolateral direction, very few cases report of a superolateral dislocation/displacement [7], or traumatic impaction–dislocations into middle cranial fossa with the condyle intact [8]. However, a case of anterior dislocation and displacement of a fractured condyle in a child below 6 years of age is rarely seen.

The probable mechanism explained in the literature for the displacement of the fractured condylar segment has been attributed to the action of unopposed pull of lateral pterygoid muscle on the fractured condylar segment leading to anteromedial displacement [9]. In the present case scenario the probable explanation that could be given for unusual anterior displacement and dislocation of the fractured condylar segment against the usual action of lateral pterygoid is as follows:

- 1 Stripping of lateral pterygoid due to the impact of the injury, failing the action of lateral pterygoid on the fractured condyle.
- 2 Open mouth position during the impact causing the fracture of the condyle in a position anterior to the eminence with resultant premature displacement of the residual major component of the mandible into the glenoid fossa preventing any further movement of the already anteriorly displaced fractured condylar segment towards either lateral or medial or superior directions.

The patient revealed that treatment had been delayed owing to poor socioeconomic status, and late reporting/referral to doctors, undesirably translating into a prolonged period of restricted mouth opening due to pain following trauma, eventually leading to

Pseudo-ankylosis. Miyamoto stated that restricted jaw movement is not the determinant factor, but rather the promoting agent for ankylosis [10]. Malnourishment could be another factor influencing such an outcome, as recent evidence indicates that, in malnutrition, impaired callus formation as well as fibrous ankylosis in the TM joint result on healing of a displaced condylar process [11].

Complete remodeling of the Temporomandibular joint bilaterally, was evident on the CT scan, the findings of which are consistent with those of Lindalh, who reports that 20 of 27 study patients, in the age group of 3–11 years, had complete return to normal skeletal relationship, a finding that was not observed in other age groups [12]. In our case, conventional radiographs revealed altered regional (osseous) anatomy, further supplemented by a 3D CT scan to locate the condylar fragment, displaced and/or dislocated into the sigmoid notch, and study its relationship to the zygomatic arch, as the latter modality greatly increases diagnostic accuracy in TMJ ankylosis imaging [2].

Cases of condylar fractures are common in both developed and developing countries, but cases of post-traumatic TM joint ankylosis are few in developed countries compared to developing countries for various reasons as stated by Dongmei He et al. & Gururaj Arakeri et al. [13,14].

4. Conclusion

TM joint ankylosis may be very recent or old but of vital importance to any kind is an accurate diagnosis for successful management outcomes. It is equally important to recapitulate the types and patterns of disruption in TM joint function when setting out to 'open' these cases as most cases usually get away without 'open' treatment, not to mention the considerable physical and psychological insult otherwise associated with TM joint ankylosis and its management. Institution of aggressive physical therapy as early as possible is as important as the surgical intervention itself, if not more. Complications, though rare, are potentially fatal.

To conclude, we herein report a unique case of anterior dislocation of fractured mandibular condyle leading to pseudo-ankylosis in a 8 yr Old Child. In this case report we have highlighted the hypothesis of mechanism of pseudo-ankylosis. This case report also suggests that unusual dislocations of mandibular condyle do occur in children, which require careful planning and treatment.

Conflict of interest

All authors have no conflict of interests.

Funding

All authors have no funding of research.

Ethical approval

Ethical approval not required.

Consent

Written informed consent was obtained from the patient for publication of this case report and accompanying images. A copy of the written consent is available for review by the Editor-in-Chief of this journal on request.

Author contribution

Dr Ranjit kumar P: Treated the patient , writing the paper and submission, Dr Naveen G: Obtaining patient records ,Followed up the patient, Dr Raja Satish: Assisting in treating the patient, Writing the paper, Dr Srinivas Chakravarthy P: Treated the patient, Review the article, Dr L Krishna Prasad: Assisted in revising the article.

Guarantor

Dr Ranjit Kumar Peravali.

Acknowledgement

We would like to acknowledge the contributions of Dr Phani kumar, Dr Rajay Kamath and Dr Rahul Tiwary in the preparation of this manuscript.

References

- [1] V.H. Kazanjian, Ankylosis of the temporomandibular joint, *Am. J. Orthodontia* 24 (1938) 1181–1206.
- [2] C.E. Zimmerman, M.J. Troulis, L.B. Kaban, *Int. J. oral Maxillofac. Surg.* 34 (2005) 823–833.
- [3] U.M. Das, R. Keerthi, D.P. Ashwin, R. VenkataSubramaniam, D. Reddy, N. Shiggaon, *J. Indian Soc. Pedod. Prev. Dent.* 27 (2) (2009) 116–120.
- [4] L.B. Kaban, J.B. Mulliken, J.E. Murray, Facial fractures in children: an analysis of 122 fractures in 109 patients, *Plast. Reconstr. Surg.* 1 (1977) 15.
- [5] J.C. Posnick, M. Wells, G.E. Pron, Pediatric facial fractures: evolving patterns of treatment, *J. Oral Maxillofac. Surg.* 51 (1993) 836.
- [6] S.E. Norholt, V. Krishnan, S. Sindet-Pedersen, I. Jensen, Pediatric Condylar Fractures: a long-term follow-up study of 55 patients, *J. Oral Maxillofac. Surg.* 51 (1993) 1302.
- [7] David Tauro, Shubha Lakshmi, Madan Mishra, *Craniomaxillofac Trauma Reconstr.* 3 (2010) 119–123.
- [8] C. Man, S.-S. Zhu, S. Chen, L. Jiang, J. Hu, Dislocation of the intact mandibular condyle into the middle cranial fossa: a case report, *Int. J. Oral Maxillofac. Surg.* 40 (2011) 118–120.
- [9] Jiirgen-Riidiger Petzel, Georg Biilles, Experimental Studies of the Fracture Behavior of the Mandibular Condylar Process, *J. Maxfac. Surg.* 9 (1981) 211–215.
- [10] H. Miyamoto, K. Kurita, N. Ogi, J.I. Ishimaru, A.N. Goss, Effect of limited jaw motion on ankylosis of the temporomandibular joint in sheep, *Br. J. Oral Maxillofac. Surg.* 38 (2000) 148–153.
- [11] Lucimar Rodrigues, Luciana Corrêa, João Gualberto C. Luz, Healing of displaced condylar process fracture in rats submitted to protein undernutrition, *J. Craniomaxillofac. Surg.* 39 (2011) 73–78.
- [12] Lars Lindalh, Lars Hollender, Condylar fractures of the mandible: a radiographic study of remodeling processes in the temporomandibular joint, *Int. J. Oral Surg.* 6 (1977) 153–165.
- [13] Dongmei He, D.D.S. Edward Ellis III, Yi Zhang, Etiology of temporomandibular joint ankylosis secondary to condylar fractures: the role of concomitant mandibular fractures, *J. Oral Maxillofac. Surg.* 66 (2008) 77–84.
- [14] Gururaj Arakeri, Atul Kusanale, Graeme A. Zaki, Peter A. Brennan, Pathogenesis of post-traumatic ankylosis of the temporomandibular joint: a critical review, *Br. J. Oral Maxillofac. Surg.* 50 (2012) 8–12.

Open Access

This article is published Open Access at sciendoirect.com. It is distributed under the [IJSCR Supplemental terms and conditions](#), which permits unrestricted non commercial use, distribution, and reproduction in any medium, provided the original authors and source are credited.