



## Case report

## Mediastinal paraganglioma as a large dumbbell tumor: A case report

Imene Bouassida<sup>a</sup>, Bochra Zayene<sup>a,\*</sup>, Hazem Zribi<sup>a</sup>, Amina Abdelkbir<sup>a</sup>, Rahma Ayadi<sup>b</sup>, Adel Marghli<sup>a</sup>

<sup>a</sup> Department of Thoracic and Cardiovascular Surgery, Abderrahman Mami Hospital, Ariana, Tunisia

<sup>b</sup> Department of Anatomopathology, Abderrahman Mami Hospital, Ariana, Tunisia

## ARTICLE INFO

## Keywords:

Paraganglioma  
Neurogenic  
Dumbbell  
Surgery

## ABSTRACT

Mediastinal paraganglioma presented as a large dumbbell tumor is a rare entity.

We report a case of a 47 year old woman who suffered from spinal pain and sporadic lower limb paresis.

The imaging studies showed a voluminous mass occupying the posterior mediastinum with right foraminal extension. For excellent results, a combined effort was necessary including thoracic and neurosurgeons teams. Complete resection was successfully performed without laminectomy.

The operative course was uneventful.

## 1. Introduction and importance

Thoracic dumbbell tumors are defined as neoplasms arising from neurogenic cells. They are characterised by a paraspinal and intraspinal component which connect through an intervertebral foramen [1].

Dumbell posterior mediastinal tumors are uncommon. Paraganglioma in this location is too rare, presenting 1–2% of all paragangliomas and <0.3% of mediastinal neoplasm [2].

The treatment of choice is based essentially on surgery with a controversial approach.

We describe a nonfunctional dumbbell shaped paraganglioma arising in the posterior mediastinum that was successfully removed through thoracotomy without laminectomy.

The work has been reported in line with the SCARE 2020 criteria [3].

## 2. Case presentation

A 47 year old woman, with medical history of asthma presented with thoracic spinal pain and sporadic lower limb paresis since 3 months. Physical examination was without particularities. A chest X-Ray showed a right pleural effusion (Fig. 1).

A further thoracic CT scan revealed a tissue mass in the paravertebral gutter measuring 86\*67\*54 with extension through the D10, D11 and D12 vertebral foramen associated with a pleural effusion of great abundance (Fig. 2). A cerebro-medullary MRI has performed showing a voluminous mass of the right costo-vertebral gutter of 105 mm with a

heterogeneous hypersignal T2, and hyposignal T1 with a homogeneous enhancement after injection with right foraminal extension (T10-T11 and T11-T12) without intracanal extension or metastasis (Fig. 3). A surgical biopsy of the mass was indicated, and the anatomopathological examination was in favor of a neurogenic tumor, PS100 and CD56 were positive.

The decision was to resect the mass with the neurosurgery team. The patient had a posterolateral thoracotomy in the 8th intercostal space. The mass was easily identified above the diaphragm and abutting the inferior vena cava with intimate contact with the spine. The mass was dissected carefully with liberal clipping and tying of ample vascular supply. After assessing the dumbbell portions extirpability a complementary laminectomy did not seem to be necessary and the tumor was successfully removed in one bloc (Fig. 4). The postoperative course was uneventful. The definitive anatomopathological examination confirm the diagnosis of paraganglioma with free margins of resection. A follow up with thoracic CT scan after six months came back with no recurrences.

## 3. Clinical discussion

Mediastinal dumbbell tumors are an extremely rare neoplasms with a double thoracic and spinal composition. They can rarely extend to the neural foramen and cause a spinal cord compression [4].

Paragangliomas are a rare neuroendocrine tumors with an extra-adrenal origin, they can be functional producing excess of

\* Corresponding author.

E-mail address: [bochra.zayene@gmail.com](mailto:bochra.zayene@gmail.com) (B. Zayene).

<https://doi.org/10.1016/j.ijscr.2022.107160>

Received 24 February 2022; Received in revised form 30 April 2022; Accepted 30 April 2022

Available online 4 May 2022

2210-2612/© 2022 Published by Elsevier Ltd on behalf of IJS Publishing Group Ltd. This is an open access article under the CC BY-NC-ND license (<http://creativecommons.org/licenses/by-nc-nd/4.0/>).

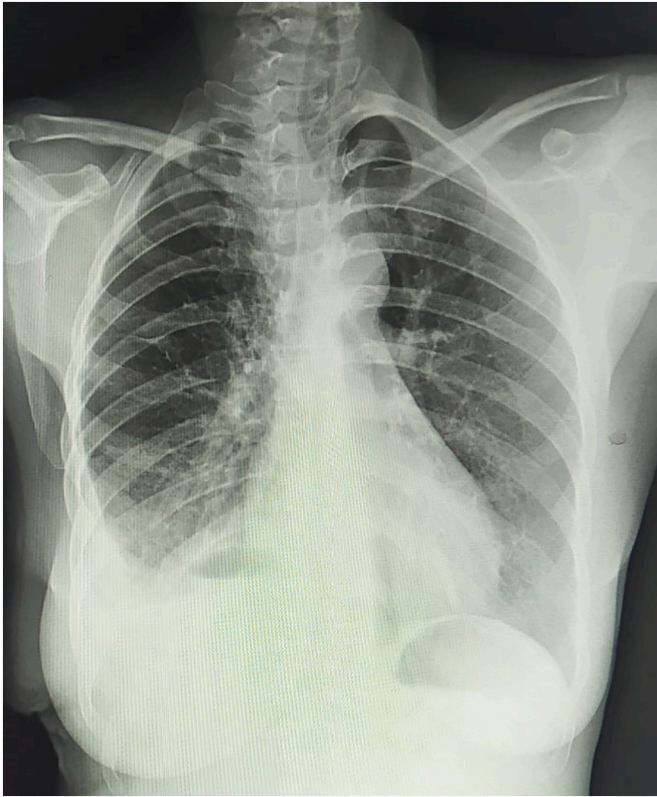


Fig. 1. Chest X-Ray showing right pleural effusion.

catecholamines or nonfunctional. Mediastinal paraganglioma are classified in two types: aorticosympathetic paraganglioma that arise in the posterior mediastinum, and aorticopulmonary paraganglioma occurring in the anterior or middle mediastinum [5].

Young adults are the most touched people. The mean symptoms were palpitation, hypertension and sweating and they are related to the functional activity of the tumor. Usually, the tumor can be totally asymptomatic discovered fortuitously on radiological examination [6]. In our case, the patient presented with nonfunctional symptoms.

The diagnosis of posterior mediastinal tumors is based on both CT scan and MRI to evaluate the extension to the spinal canal, neural foramen and erosion of the pedicle of the vertebrae [4].

The imaging features of mediastinal paragangliomas have specific characteristics. On CT Scan, it presents a uniform contrast enhancement with rapid washout and may appear with heterogenic enhancement on large necrosis tumors [5]. On MRI, the mass appears with low or intermediate signal intensity on T1 and high signal intensity on T2 which was observed in our patient. It was also reported the feature of a salt and pepper appearance [7].

The most differential diagnosis of dumbbell shaped lesions in posterior mediastinum are meningiomas, hemangiomas and neurogenic tumors [8].

Surgical resection is the basic treatment for paraganglioma which may require an extensive approach [9]. The aim of surgery is to remove the intraspinal and the extraspinal tumors.

For successful outcome a coordinated effort combined thoracic and neurosurgery team is important to deal with dumbbell tumors [4]. A two stage operation can be indicated in a few cases of extensive intraspinal tumors [4]. A single stage procedure is recommended when possible. Ma et al. considered that thoracotomy still the right choice for tumors with an abundant blood supply and without foraminal extension. In the other hand endoscopic resection can be successfully applied in small, noninvasive paraganglioma [10].

In our case, the mass was too large, with slight extension through the vertebral foramen. The appropriate approach was challenging. The tumor was completely removed without laminectomy in a single stage procedure with excellent result.

#### 4. Conclusion

Paraganglioma is a benign tumor in 90% of cases and the presentation as a dumbbell tumor is exceptional. Posterior mediastinal mass diagnosed as neurogenic tumor was completely resected in collaboration with neurosurgeons via thoracotomy with good outcome at 6 month follow up.

#### Funding

This study was not supported by any institution and company.

#### Ethical approval

Ethical approval was not required and patient identifying knowledge was not presented in the report

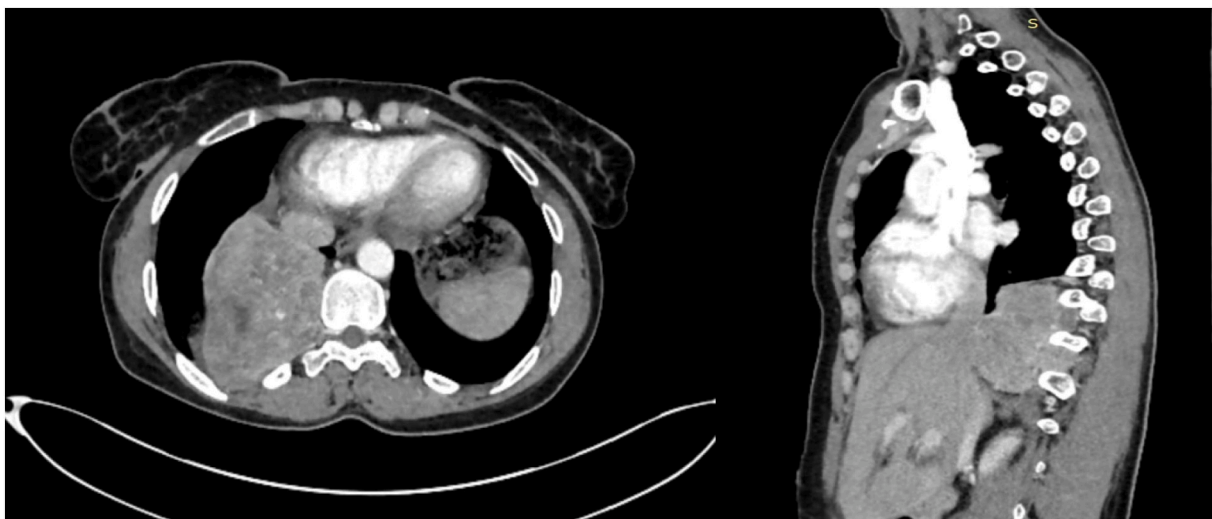


Fig. 2. Chest CT showing a homogeneous dumbbell-shaped mass in the right posterior mediastinum with vertebral extension.

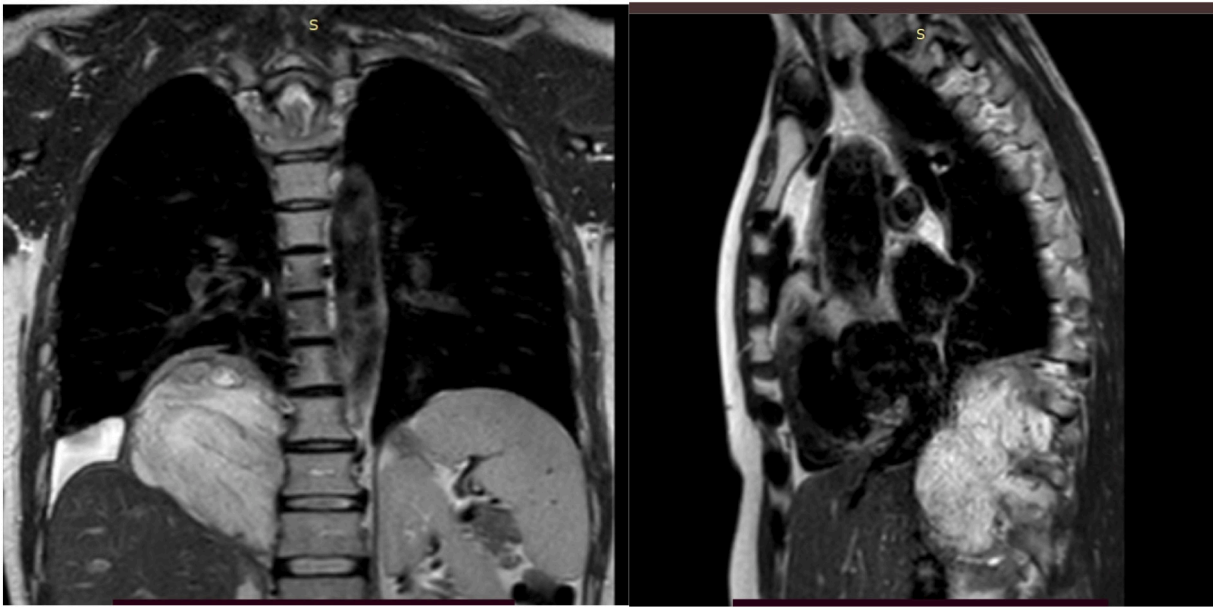


Fig. 3. MRI showing a mass in the posterior mediastinum with right foraminal extension.

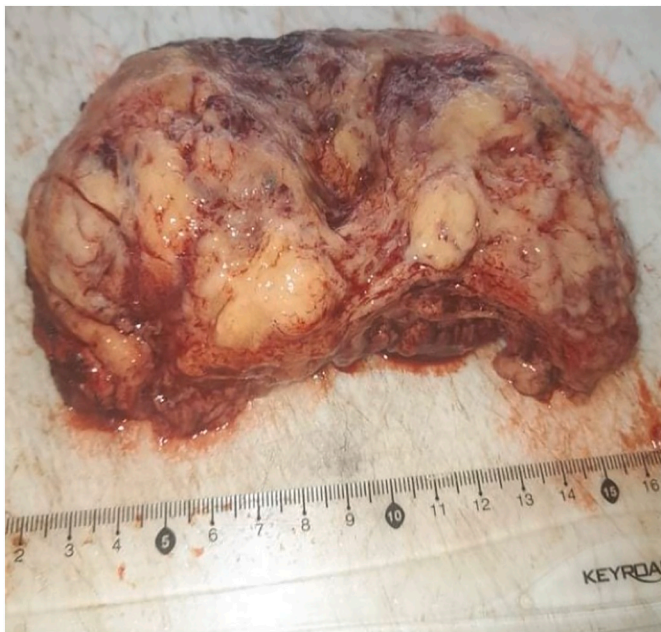

Fig. 4. Surgical specimen, Peroperative view after resection of the mass through the D10, D11 and D12 vertebral foramen.

#### Consent

Written informed consent was obtained from the patient for publication of this case report and accompanying images. A copy of the written consent is available for review by the Editor-in-Chief of this journal on request

#### Guarantor

Dr. Adel Marghli

#### CRedit authorship contribution statement

Study concepts: Dr. Imene Bouassida Manuscript writing: Dr. Bochra Zayene. Helped in data interpretation and manuscript evaluation: Dr. Hazem Zribi, Dr. Amina Abdelkbir Data acquisition: Dr. Rahma Ayadi. Critical revision: Dr. Adel Marghli.

#### Declaration of competing interest

Authors declare no conflict of interest

#### References

- [1] K. Ando, S. Imagama, N. Wakao, K. Hirano, R. Tauchi, A. Muramoto, H. Matsui, T. Matsumoto, Y. Matsuyama, N. Ishiguro, Single-stage removal of thoracic dumbbell tumors from a posterior approach only with costotransversectomy, *Yonsei Med. J.* 53 (3) (2012) 611–617.
- [2] Y. Takashima, T. Kamitani, S. Kawanami, M. Nagao, M. Yonezawa, Y. Yamasaki, S. Baba, H. Yabuuchi, T. Hida, K. Kohashi, K. Nakamura, H. Sonoda, Y. Oda, H. Honda, Mediastinal paraganglioma, *Jpn. J. Radiol.* 33 (7) (2015 Jul) 433–436.
- [3] R.A. Agha, T. Franchi, C. Sohrabi, G. Mathew, for the SCARE Group, The SCARE 2020 guideline: updating consensus Surgical Case Report (SCARE) guidelines, *Int. J. Surg.* 84 (2020) 226–230.
- [4] M.B. Shadmehr, H.A. Gaissert, J.C. Wain, A.C. Moncure, H.C. Grillo, L.F. Borges, D. J. Mathisen, The surgical approach to "dumbbell tumors" of the mediastinum, *Ann. Thorac. Surg.* (2003).
- [5] J. Balcombe, D.A. Torigian, W. Kim, W.T. Miller, Cross-sectional imaging of paragangliomas of the aortic body and other thoracic brachiomeric paraganglia, *AJR Am. J. Roentgenol.* 188 (2007) 1054–1058.
- [6] A. Ayadi-Kaddour, E. Braham, O. Ismail, B. Smati, H. Djlani, F. El Mezni, Posterior mediastinal paragangliomas: a report of three patients with peculiar tumours, *Respirology* 14 (3) (2009 Apr) 459–461.
- [7] H. Wang, H. Ye, A. Guo, Z. Wei, X. Zhang, Y. Zhong, et al., Bladder paraganglioma in adults: MR appearance in four patients, *Eur. J. Radiol.* 80 (2011) e217–e220.
- [8] A. Mo, J. Zhang, Surgery for posterior mediastinal dumbbell tumors: a case report, *Ann. Med. Surg. (Lond.)* 4 (4) (2015) 366–370. Published 2015 Oct 3.
- [9] Yang Yue, Hua Xin, Fu-Qiang Li, Jun-Duo Wu, Jun-Zhi Liu, Le-Ning Zhang, Asymptomatic left posterior mediastinal functional paraganglioma, *Medicine* 98 (28) (July 2019), e16383.
- [10] L. Ma, J. Mei, L. Liu, Thoracoscopic resection of functional posterior mediastinal paraganglioma: a case report, *J. Thorac. Dis.* 6 (2014) 1861–1864.