

# Arthroscopic Synovectomy of the Hip Joint: The Regional Surgical Technique



Kang Tian, M.D.\*, Guanying Gao, M.D.\*, Hanmei Dong, Weiguo Zhang, M.D., Jianquan Wang, M.D., and Yan Xu, M.D.

**Abstract:** Synovial disease is a common reason for hip joint dysfunction. Although traditionally treated with open synovectomy, with the popularization and development of arthroscopic techniques, arthroscopic synovectomy has become the main surgical treatment for synovial diseases. Given the long soft tissue channel and learning curve, arthroscopic synovectomy of the hip joint has high surgical requirements for surgeons. However, there is currently no standardized surgical protocol for arthroscopic synovectomy of the hip joint to guide the surgeon to perform hip synovectomy in an orderly manner. During the past 3 years, we have employed a novel technique, wherein we divided the synovium of the hip into seven regions based on the anatomical structure and the operating range of the arthroscopic portals. With the assistance of flexion, extension, and traction of the hip joint, synovectomy was sequentially performed under arthroscopic guidance. This regional surgical technique can be popularized and likely has the potential to become a standardized arthroscopic synovectomy protocol of the hip joint.

## Introduction

Synovial diseases such as pigmented villonodular synovitis (PVNS), synovial chondromatosis, and rheumatoid arthritis are common causes of hip joint dysfunction in clinical practice.<sup>1-4</sup> Synovial pathological changes of such diseases could lead to articular cartilage

lesions or even irreversible joint degeneration of the hip.<sup>5</sup> Traditional surgical treatment uses open surgery and synovectomy; however, with the development of arthroscopic technology, arthroscopic synovectomy of the hip has gradually become the first treatment option for surgeons.<sup>6-8</sup>

Synovectomy under hip arthroscopy has high surgical technical requirements. However, there are few technical studies about the surgical protocol for arthroscopic synovectomy, including portals, positioning, and surgical procedure.<sup>9,10</sup> In addition, incomplete excision of the synovium has become one of the main reasons for the recurrence of hip synovial disease, including PVNS and synovial chondromatosis.<sup>11-14</sup> Here, on the basis of our surgical experience, we aim to introduce a regional surgical protocol for synovectomy of the hip that we have been using in the past 3 years. Using this surgical protocol, we divided the hip synovium into seven regions under arthroscopy, with the assistance of flexion, extension, and traction, synovectomy was sequentially performed under an arthroscope. The regional surgical technique likely has the potential to become a popular and standardized arthroscopic synovectomy protocol for the hip joint.

## Regions of the Hip Synovium

To make this a regular surgical protocol for hip synovectomy, we divided the synovium of the peripheral and central compartment of the hip joint into seven

*From the Department of Sports Medicine, Beijing Key Laboratory of Sports Injuries, Institute of Sports Medicine, Peking University Third Hospital, Beijing, China (K.T., G.G., H.D., J.W., Y.X.); and Department of Bone and Joint, First Affiliated Hospital, Dalian Medical University, Dalian, China (K.T., W.Z.).*

*The authors report the following potential conflicts of interest or sources of funding: The study was supported by Beijing Municipal Natural Science Foundation (Z200003), Peking University Medicine Seed Fund for Interdisciplinary Research (BMU2021MX022), National Natural Science Foundation (no. 81601901) and Natural Science Foundation of Liaoning (no. 2019-MS-079), China. Full ICMJE author disclosure forms are available for this article online, as [supplementary material](#).*

*\*K.T. and G.G. have contributed equally to this work and share first authorship.*

*Received January 5, 2022; accepted February 11, 2022.*

*Address correspondence to Yan Xu, M.D., Department of Sports Medicine, Beijing Key Laboratory of Sports Injuries, Institute of Sports Medicine, Peking University Third Hospital, No.49 Huayuan North Rd., Beijing 100191, China. E-mail: [yanxu@139.com](mailto:yanxu@139.com)*

© 2022 THE AUTHORS. Published by Elsevier Inc. on behalf of the Arthroscopy Association of North America. This is an open access article under the CC BY-NC-ND license (<http://creativecommons.org/licenses/by-nc-nd/4.0/>).

2212-6287/2221

<https://doi.org/10.1016/j.eats.2022.02.029>

regions (see [Video 1](#)). Region 1 is the medial capsular recess, surrounded by the labrum from 4:30 to 7:30, according to the clock position, medial synovial fold, and medial side of joint capsule. Region 3 is the lateral capsular recess, surrounded by the labrum from 10:30 to 1:30, lateral synovial fold and lateral side of joint capsule. Region 2 is defined as the anterior capsular recess located between regions 1 and 3 ([Fig 1A](#)).

We divided the posterior recess into two portions by taking the rim of the zona orbicularis as the boundary ([Fig 1B](#)). The inferior side is defined as region 4 and the superior side is defined as region 5. Region 6 is defined as the synovial tissue attached to the labrum, and region 7 is the synovium surrounding the acetabular fossa ([Fig 1C](#)).

### Surgical Techniques

The patient is positioned supine on a traction table (Smith & Nephew, Andover, MA) and prepared and draped in standard fashion. Mark the proximal mid-anterior portal (PMAP) at the middle and inner one-third of the connection between the anterolateral (AL) and anterior superior iliac spine (ASIS). An obturator is used to create a puncture on the marked PMAP without traction. The mid-anterior portal (MAP) was established with inspection using 30° arthroscope. The outside-in technique was used to enter the joint due to the hyperplasia of the synovium and the relaxant joint capsule without traction.

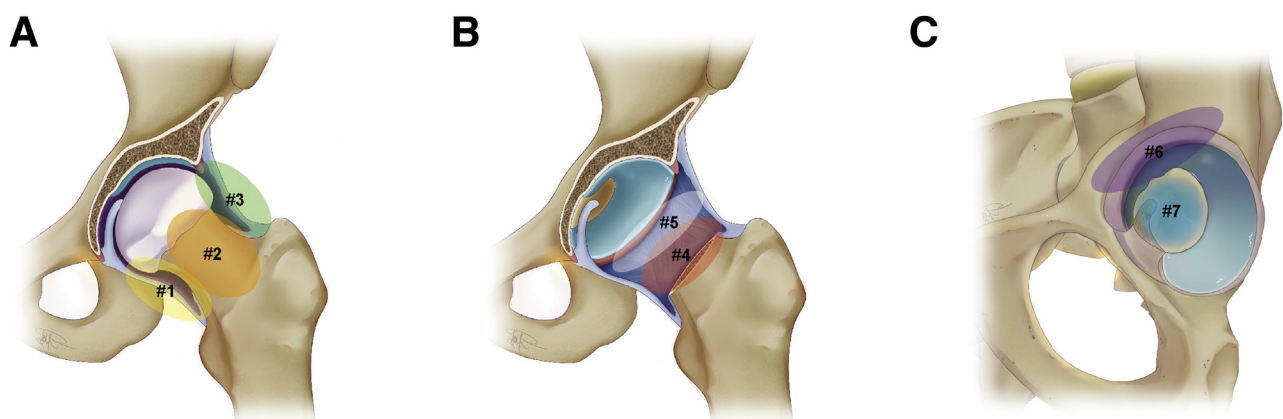
With PMAP as the viewing portal and MAP as the working portal, keep the hip joint straight without traction. Arthroscopic examination begins with inspection of the peripheral compartment, including medial and anterior capsular recess. Proximal lesions of

the medial and anterior capsular recess were excised with 0° flexion. The hip joint was gradually flexed for dissection of the distal site of the medial and anterior capsular recess. Keep the hip joint flexed and gradually internally rotate the hip to access deeper into the medial capsular recess for complete excision of the synovium ([Fig 2, A and B](#)).

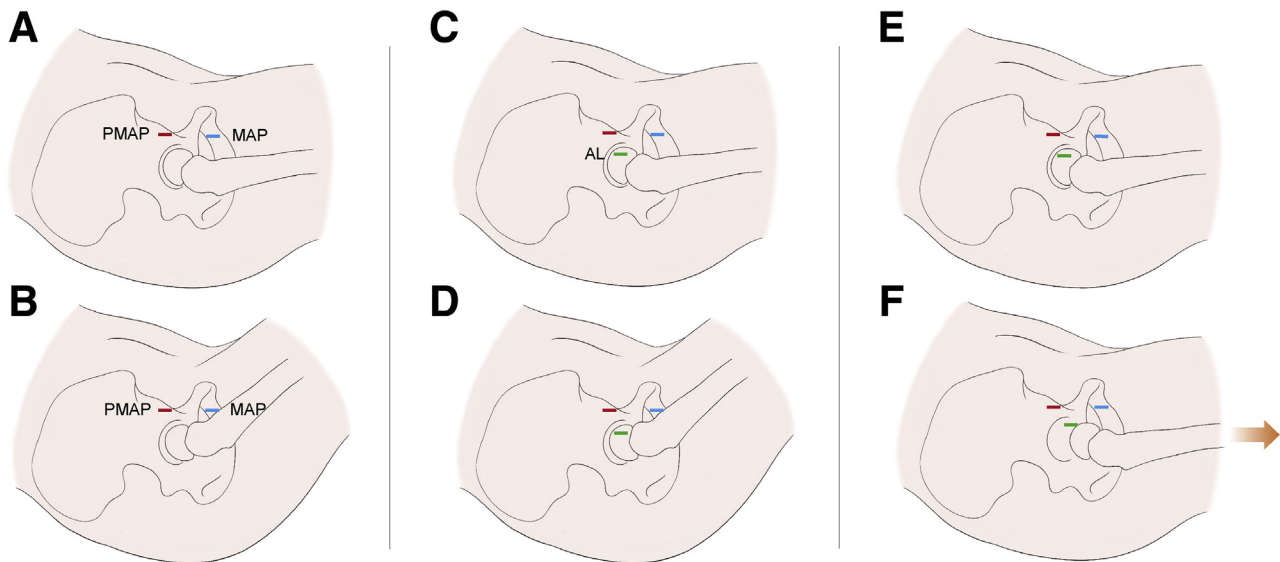
Switch the viewing portal to MAP and take PMAP as the working portal, keep the hip in flexion and neutral position for excision of synovial lesions in the distal site of lateral capsular recess. Gradually extend the hip joint to 0°, establish the AL portal and stretch the portal using radiofrequency (RF). Synovectomy of the lateral capsular recess was performed via the AL portal ([Fig 2, C and D](#)). As above, using the assistance of the AL portal and joint flexion, the synovectomy of medial, anterior, and lateral capsular recess was completely performed by switching portals between PMAP and MAP.

Extended incision (iliofemoral ligament and anterior part of iliac sitting ligament) was made through AL along the posterior-inferior rim of the zona orbicularis to obtain appropriate posterior exposure. However, it should be noted that if the incision is extended too much, the posterior and lateral gross synovium of the joint will block the arthroscope and result in poor vision. Taking AL and PMAP as the working portal, the hip joint was gradually flexed during shaving for better exposure of the postero-inferior capsular recess. Moreover, the working space could be increased with appropriate external rotation after hip flexion (see [Video 1](#)).

Switch the viewing portal from MAP to PMAP and gradually extend the joint, with appropriate traction



**Fig 1.** Schematic diagram of the regions of the hip synovium. To provide a regional surgical protocol for synovectomy of the hip joint, we divided the synovium of peripheral and central compartments of the hip joint into seven regions for better expression of the surgical technique. (A) Region 1 is the medial capsular recess, region 3 is the lateral capsular recess and region 2 is defined as the anterior capsular recess located between regions 1 and 3. (B) Likewise, we divided the posterior recess into two portions by taking the rim of the zona orbicularis as the boundary, the inferior side is defined as region 4, and the superior side is defined as region 5. (C) Region 6 is defined as the synovial tissue attached to the labrum, and region 7 is the synovium surrounding the acetabular fossa.



**Fig 2.** Schematic of portals and positioning. (A and B) For exposure of each region of the hip joint synovium, we performed synovectomy of the medial and anterior capsular recess using proximal mid-anterior portal (PMAP) and mid-anterior portal (MAP) with gradual flexion of the hip joint. (C and D) The anterolateral (AL) portal is necessary to perform synovectomy of the lateral capsular recess. (E and F) With joint flexion and external rotation, the postero-inferior recess could be reached. Synovectomy of the postero-superior region and central compartment, including the acetabular fossa and peri-labrum region, was finally performed with extension and traction of the hip joint.

applied to the hip under supervision through PMAP to expose the central compartment (Fig 2, E and F). The viewing portal was switched to MAP from PMAP, and AL was taken as the working portal. With joint traction and the extended incision of AL, we could achieve appropriate posterior exposure for excision of the posterior-superior recess. Besides the AL portal, PL was occasionally used for assistance to achieve complete dissection of the posterior region. The viewing portal was switched to AL, and MAP was made as the working portal to remove the synovium attached to the labrum. On the basis of our experience, for hip synovial diseases such as PVNS, the synovial lesion attached to the anterior labrum is hard to remove without traction. Finally, the synovium attached to the fossa acetabuli was subsequently removed. Therefore, we could achieve synovectomy of the hip joint by using the PMAP, MAP, and AL portals with the assistance of traction and flexion of the hip joint (Table 1). Finally, keep the hip

flexed by about 60° and suture the joint capsule through PMAP and MAP at the 12, 1, 2, and 3 o'clock positions under AL inspection. Arthroscopic view of each surgical step is shown in Fig 3 and Video 1, and a typical case of synovial chondromatosis is shown in Fig 4.

In our surgical protocol, the following points are worthy of mention: 1) without traction, slotted cannula is a necessary tool for assisting the passage of instruments through portals; 2) stay away from the lateral synovial fold to protect the blood supply of the femoral head while performing synovectomy of the lateral capsular recess; and 3) for viewing of the posterior recess, 70° arthroscope could be selected if necessary for a better arthroscopic view (Table 2).

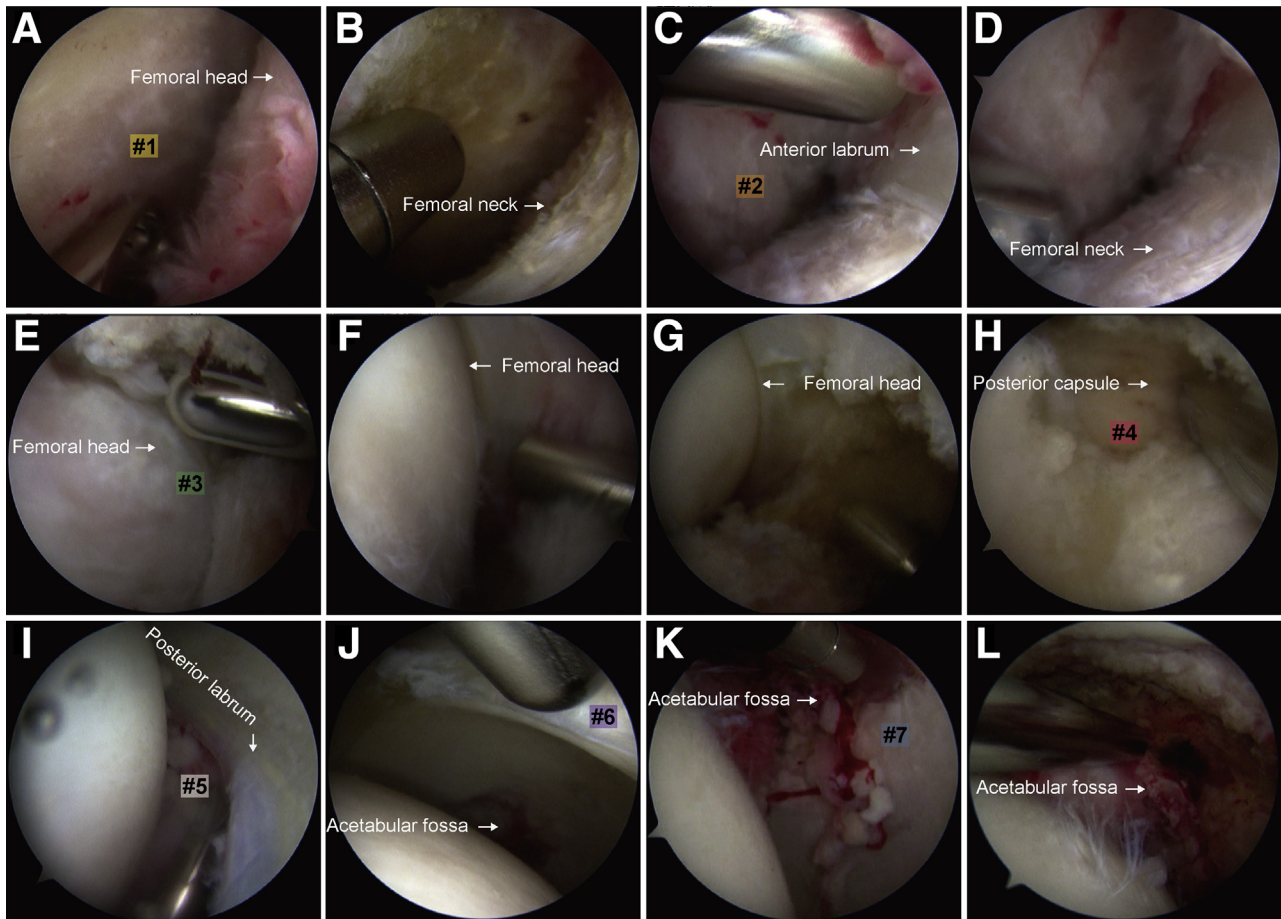
## Discussion

Hip joint synovial diseases, including rheumatoid arthritis, synovial chondromatosis, and pigmented

**Table 1.** Procedures Involved in the Regional Surgical Technique

|                             | Viewing Portal | Working Portal | Position                      | Traction |
|-----------------------------|----------------|----------------|-------------------------------|----------|
| #1 Medial Capsular Recess   | PMAP           | MAP            | Flexion and internal rotation | –        |
| #2 Anterior Capsular Recess | PMAP           | MAP            | Extension and flexion         | –        |
| #3 Lateral Capsular Recess  | MAP            | AL             | Extension and flexion         | –        |
| #4 Postero-inferior Recess  | MAP            | AL             | Flexion and external rotation | –        |
| #5 Postero-superior Recess  | MAP            | AL             | Extension                     | +        |
| #6 Peri-labrum              | AL             | MAP            | Extension                     | +        |
| #7 Acetabular Fossa         | AL             | MAP            | Extension                     | +        |

AL, anterolateral; MAP, mid-anterior portal; PMAP, proximal mid-anterior portal.



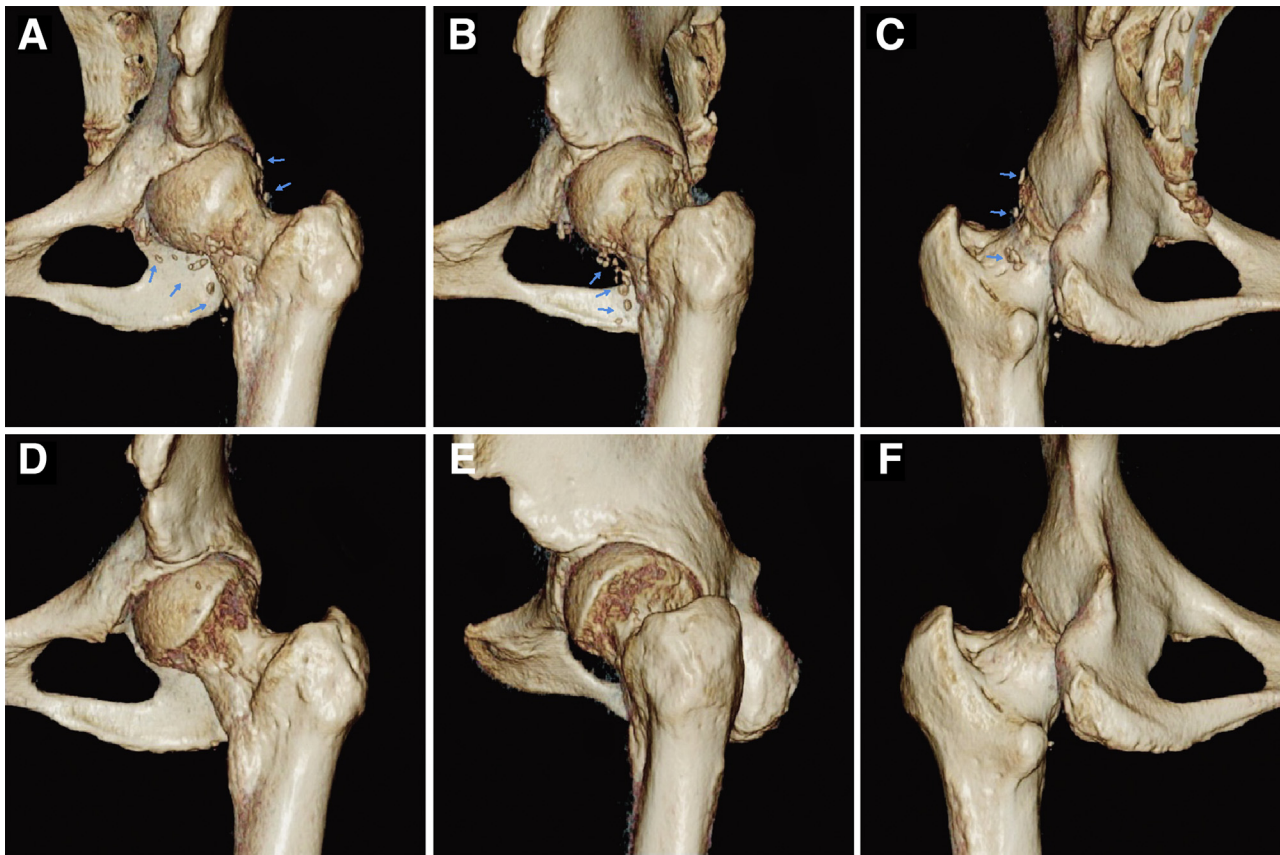
**Fig 3.** Arthroscopic view of different regions and surgical procedures. Resection of synovial lesions of the medial capsular recess (A) with gradual flexion of the hip and assistance with internal rotation for better exposure (B). Synovectomy of anterior (C and D) capsular recess was performed using hip flexion. The anterolateral (AL) was established (E) for excision of the lateral (F) and postero-inferior recess (G-H). Resection of synovial lesions of the postero-inferior recess (I), peri-labrum (J), and central compartment (K and L) was performed with hip joint extension and traction.

villous nodular synovitis (PVNS) are characterized by unobvious and nonspecific symptoms and long disease course.<sup>14,15</sup> It is difficult to achieve a diagnosis at the early stage of onset, and many patients are first diagnosed by imaging examinations after years of onset of hip symptoms. Synovectomy is the ultimate treatment option for synovial disease of the hip joint.<sup>11,16,17</sup> The traditional surgical treatment follows surgical dislocation technique to expose the synovium for resection, which has disadvantages or complications such as large surgical trauma, long rehabilitation time, postoperative infection, heterotopic ossification, and femoral head necrosis. With the development of hip arthroscopy, the completion of arthroscopic hip synovectomy has obvious advantages with respect to perioperative care, rehabilitation, and reduced complications. Therefore, arthroscopic synovectomy has become the first choice for many surgeons to treat synovial diseases of the hip. Arthroscopy has its unique advantages for the diagnosis

of synovial lesions such that a diagnosis is possible on the basis of general observation, as well as arthroscopic treatment.

Previous clinical studies on arthroscopic synovectomy for PVNS, synovial chondromatosis, and rheumatoid synovitis reported good clinical outcome.<sup>16-18</sup> However, arthroscopic synovectomy for the hip joint has high technical requirements; accordingly, treatment outcome and postoperative recurrence of arthroscopic synovectomy are both closely related to the expertise of the surgeon. Incomplete joint synovectomy during surgery is an important reason for postoperative recurrence. Therefore, we believe that the establishment of a standardized protocol for hip arthroscopic synovectomy will be necessary to increase the popularity of surgical experience of arthroscopic synovectomy for the hip.

In our surgical protocol, we divided the hip joint synovium into seven regions: the dissection of medial



**Fig 4.** Typical case of synovial chondromatosis. Preoperative (A-C) and postoperative (D-F) three-dimensional CT reconstruction in a 35-year-old female patient with synovial chondromatosis of the left hip. Arthroscopic synovectomy was performed within 75 min using the regional surgical technique with no recurrence at the 1-year follow-up. Anterior view (A, D); lateral view (B, E); and posterior view (C, F) of the 3D-reconstructed imaging results were compared before and after surgery. Synovial chondromas of the hip joint are marked by blue arrows (A-C), which disappeared in the postoperative computed tomography (D-F).

capsular recess (region 1), anterior capsular recess (region 2), and lateral capsular recess (region 3) was conducted alternately through the PMAP and MAP portals without traction, with assistance from flexion and external rotation of the hip. The hip was flexed for the dissection of posterior-inferior recess (region 4) through AL. Gradually, the hip is then extended to 0° flexion with traction for the exposure of peri-labrum synovium (region 6), central compartment (region 7),

and posterior-superior capsular recess (region 5). It should be noted that for the exposure of posterior recess (regions 4 and 5), the hip should be extended and applied with traction. Moreover, the AL should be stretched with backward incision of iliofemoral ligament along with the rim of the zona orbicularis for better observation of the posterior compartment. Extended incision of the lateral-posterior joint capsule along the AL portal will cause migration of loose bodies

**Table 2.** Pearls and Pitfalls

| Pearls  | Pitfalls   |
|---|--|
| Traction could be applied to establish the proximal mid-anterior and mid-anterior portal and be released after entering the peripheral compartment. | Extended incision of the lateral-posterior joint capsule along the anterolateral portal will cause migration of loose bodies from the inside to outside of the joint. To avoid this, we usually try to clean up regions 3 and 4 as much as possible before proceeding to the extended incision of the joint capsule.   |
| Without traction, slotted cannula is a necessary tool for assisting the passage of instruments through portals.                                     | Owing to partial incision of the joint capsule, our technique may cause instability of the hip joint. Therefore, suturing of the joint capsule is necessary in this technique, especially for the iliofemoral ligament. However, with appropriate management of the joint capsule, none of our patients have so far acquired postoperative instability of the hip joint. |
| This procedure stays away from the lateral synovial fold to protect the blood supply of the femoral head while performing synovectomy of region 3.  |  |
| For viewing of the posterior recess, 70° arthroscope could be selected if necessary for a better arthroscopic view.                                 |  |

**Table 3.** Advantages and Limitations of the Technique

| Advantages  | Limitations  |
|---|--|
| We divided the synovium of the hip joint into seven regions and synovectomy of the hip was performed in a sequence by using our protocol to avoid omission of synovectomy and recurrence of synovial disease. | This technique requires certain clinical expertise regarding hip arthroscopy. Moreover, the tension-free state of the joint capsule increases the difficulty of the operation. |
| We named the seven regions of the synovium with numbers for better understanding of the surgical procedure and for better academic communication.   |  |
| Our protocol optimizes the surgical procedure of the hip arthroscopic synovectomy and provides a reliable and time-saving regional surgical technique for synovectomy of the hip joint.                       |  |

from the inside to outside of the joint. To avoid this, we usually try to clean up regions 3 and 4 as much as possible before proceeding to the extended incision of the joint capsule (Table 2). Owing to partial incision of joint capsule, our technique may cause instability of the hip joint. Therefore, suturing of the joint capsule is necessary in this technique, especially for the iliofemoral ligament. However, with appropriate management of the joint capsule, none of our patients have so far acquired postoperative instability of the hip joint.

Using this surgical technique and for better understanding of the surgical procedure and its subsequent teaching, we divided the synovium of the hip joint into seven regions, and synovectomy of the hip was performed in an orderly manner to avoid omission of synovectomy and recurrence of the synovial disease. Our protocol optimizes the surgical procedure of the hip arthroscopic synovectomy and provides a reliable and time-saving regional surgical technique for synovectomy of the hip joint (Table 3).

The above surgical protocol was applied to our clinical practice during the past 3 years for treatment of patients with synovial chondroma, PVNS, and rheumatoid arthritis, and no recurrence has been reported thus far. Therefore, with this report, we wish to share our surgical experience and possibly establish a standardized surgical protocol for hip arthroscopic synovectomy.

## References

- Lee S, Haro MS, Riff A, Bush-Joseph CA, Nho SJ. Arthroscopic technique for the treatment of pigmented villonodular synovitis of the hip. *Arthrosc Tech* 2015;4:e41-e46.
- Willimon SC, Schrader T, Perkins CA. Arthroscopic management of pigmented villonodular synovitis of the hip in children and adolescents. *Orthop J Sports Med* 2018;6:2325967118763118.
- Rath E, Amar E, Doron R, Matsuda DK. Hip arthroscopy for synovial chondromatosis: Tips and tricks. *Arthrosc Tech* 2014;3:e709-e712.
- Liu Y, Li J, Ma N, et al. Arthroscopic treatment of synovial chondromatosis of hip joint. *J Orthop Surg Res* 2020;15:405.
- Steinmetz S, Rougemont AL, Peter R. Pigmented villonodular synovitis of the hip. *EFORT Open Rev* 2016;1:260-266.
- Zusmanovich M, Haselman W, Serrano B, Banffy M. The incidence of hip arthroscopy in patients with femoroacetabular impingement syndrome and labral pathology increased by 85% between 2011 and 2018 in the United States. *Arthroscopy* 2022;38:82-87.
- Nguyen KH, Shaw C, Link TM, et al. Changes in hip capsule morphology after arthroscopic treatment for femoroacetabular impingement syndrome with periportal capsulotomy are correlated with improvements in patient-reported outcomes. *Arthroscopy* 2022;38:394-403.
- McGovern RP, Bucci G, Nickel BA, Ellis HB, Wells JE, Christoforetti JJ. Arthroscopic capsular management of the hip: A comparison of indications for and clinical outcomes of periportal versus interportal capsulotomy. *Arthroscopy* 2021;37:86-94.
- Wunsch M, Ruhmann O, Lipka W, Stark DA, Lerch S. [Arthroscopic synovectomy of the hip joint]. *Oper Orthop Traumatol* 2014;26:469-486.
- Nazal MR, Parsa A, Martin SD. Arthroscopic treatment of pigmented villonodular synovitis of the hip using puncture capsulotomy. *Arthrosc Tech* 2019;8:e641-e646.
- Tibbo ME, Wyles CC, Rose PS, Sim FH, Houdek MT, Taunton MJ. Long-term outcome of hip arthroplasty in the setting of pigmented villonodular synovitis. *J Arthroplasty* 2018;33:1467-1471.
- Verspoor FG, Zee AA, Hannink G, van der Geest IC, Veth RP, Schreuder HW. Long-term follow-up results of primary and recurrent pigmented villonodular synovitis. *Rheumatology (Oxford)* 2014;53:2063-2070.
- Fang Y, Zhang Q. Recurrence of pigmented villonodular synovitis of the knee: A case report with review of literature on the risk factors causing recurrence. *Medicine (Baltimore)* 2020;99:e19856.
- de Sa D, Horner NS, MacDonald A, et al. Arthroscopic surgery for synovial chondromatosis of the hip: A systematic review of rates and predisposing factors for recurrence. *Arthroscopy* 2014;30:1499-1504 e1492.
- Startzman A, Collins D, Carreira D. A systematic literature review of synovial chondromatosis and pigmented villonodular synovitis of the hip. *Phys Sportsmed* 2016;44:425-431.

16. Tang HC, Sadakah M, Wirries N, Dienst M. Outcomes of arthroscopic management for pigmented villonodular synovitis of the hip. *Arch Orthop Trauma Surg* In press.
17. Nazal MR, Parsa A, Gibbs JS, Abraham PF, Martin SD. Mid-term results of arthroscopic synovectomy for pigmented villonodular synovitis of the hip. *Arthroscopy* 2020;36:1587-1598.
18. Martin RL, Christoforetti JJ, McGovern R, et al. The impact of depression on patient outcomes in hip arthroscopic surgery. *Orthop J Sports Med* 2018;6:2325967118806490.