

## ABNORMAL DEVELOPMENT OF THE THYMUS IN "NUDE" MICE

BY HENRY H. WORTIS,\* M.D., SANDRA NEHLSSEN,† Ph.D.,  
AND JOHN J. OWEN, M.D.

(From The National Institute for Medical Research, London NW 7, England)

(Received for publication 15 March 1971)

Normally, mice have two populations of lymphocytes; one is long-lived thymus dependent, recirculates, occupies the paracortical region of lymph nodes, bears  $\theta$ -antigen, and participates in cell-mediated immunity; the other is short-lived, tends to be sessile, occupies the primary follicles of lymph nodes, and can be induced to secrete humoral antibody (1).

Both cell types arise from hematopoietic precursors: fetal liver or bone marrow (1, 2). In the absence of a thymus, the normal, rapid differentiation of the long-lived recirculating lymphocyte fails to take place (3). Presumably the thymic epithelial cells induce this normal differentiation (4). Whether this induction requires cell-to-cell contact or whether some other mechanism is involved is still debatable. Mice homozygous for the mutation *nude* (5) lack thymocytes (6) and thymus-derived cells (7-9) and thus may have a defect of either the hematopoietic precursors of thymocytes or of thymic epithelium. This paper reports studies designed to distinguish between these two major possibilities.

### *Materials and Methods*

*Mice.*—The origin of the colony, the breeding scheme, and housing conditions have been described previously (9). The nude mice used in these experiments were from the F<sub>2</sub>, F<sub>3</sub>, and F<sub>4</sub> generations of a nu/+ × CBA cross.

*Pathology.*—Tissue was fixed in a formalin-acetic acid-ethanol mixture. Sections were routinely stained with hematoxylin and eosin.

*Hematology.*—Blood smears were air dried, methanol fixed, and stained with Giemsa.

*Chromosome.*—Analysis was carried out by the method of Fox and Zeiss (10) as modified by Croft (11).

*Cell Transfer.*—Bone marrow or fetal liver cells were suspended in medium 199 with 10% heat-inactivated fetal calf serum and tris(hydroxymethyl)aminomethane (Tris) buffer (pH 7.2). Viability counts were made using eosin dye exclusion. Cells were injected intravenously except where indicated.

*Irradiation.*—A Co<sup>60</sup> source was used to administer whole body irradiation.

\* Present address: Tufts University School of Medicine, Department of Pathology, Boston, Mass. 02111.

† Present address: Department of Surgical Research, Sloan-Kettering Institute for Cancer Research, New York.

*Skin Grafts.*—Skin grafts were transplanted orthotopically by the method of Billingham and Medawar (12).

*Thymus Grafts.*—Thymus grafts from newborn (AKR × CBA) F<sub>1</sub> mice were placed under the left kidney capsule of nude mice. Thymic rudiments from nude mice were placed under the kidney capsule of normal mice.

#### RESULTS

*Presence of Thymic Rudiment.*—Newborn nude mice were sacrificed and appropriate tissues fixed. Serial sagittal sections of the neck and upper thorax were made. These sections revealed that in the anterior, upper mediastinum in the triangle formed by the heart, trachea, and chest wall there were paired discrete bodies each surrounded by a connective tissue capsule from which septae enter the body to divide it into lobules. One such body is shown in Fig. 1 and another in Fig. 13 *a*.

Cells of the body are arranged irregularly and have prominent nuclei; the cytoplasm is basophilic but not markedly so; the cytoplasm is “foamy” (Fig. 2).

Serial transverse sections were made of the upper thorax of a 4 day old nude mouse. These revealed paired bodies similar to that described above. Closely attached to each of these was a smaller structure which consists of cysts or tubules lined by columnar cell, containing prominent nuclei (Fig. 3). Although closely apposed to the larger structure, this smaller body is quite discrete and has its own capsule. In all, sections of the upper mediastinum from a total of eight nude mice less than 1 wk old were examined. In each both of the paired structures were found: one lobulated and composed primarily of vacuolated cells, the other with a tubular or cystic structure.

Four nude mice examined at 35 days and four at 42–53 days had both the paired lobulated bodies and the paired cystic bodies. The cysts were lined with columnar, ciliated epithelium (Figs. 4–7).

*Parathyroid Gland.*—Parathyroid glands were seen in sections of the trachea and thyroid from each of seven nude mice. The parathyroids appeared similar to those described in normal mice, and were very distinct from the two unusual bodies described above (Fig. 8).

From our studies of newborn and older nude mice, we cannot say that either of the unusual paired bodies represents the thymic rudiment. For instance, they might be the anlagen of the ultimo branchial body or of the epithelial body. However, Pantelouris and Hair (13) have concluded from their studies of the newborn and the 14–15 day old nude fetus, that the cystic organ is the thymus rudiment.

*Effects of Normal Thymus Grafts on Nude Mice.*—Each of four nude mice (18 days old) from a single litter was given a thymus graft from a normal (CBA × AKR)F<sub>1</sub> mouse. One mouse died 21 days later. On microscopic examination no thymus tissue was identified in the graft site. At 29 days after thymus grafting the three remaining mice were given a C57BL/6 skin graft.

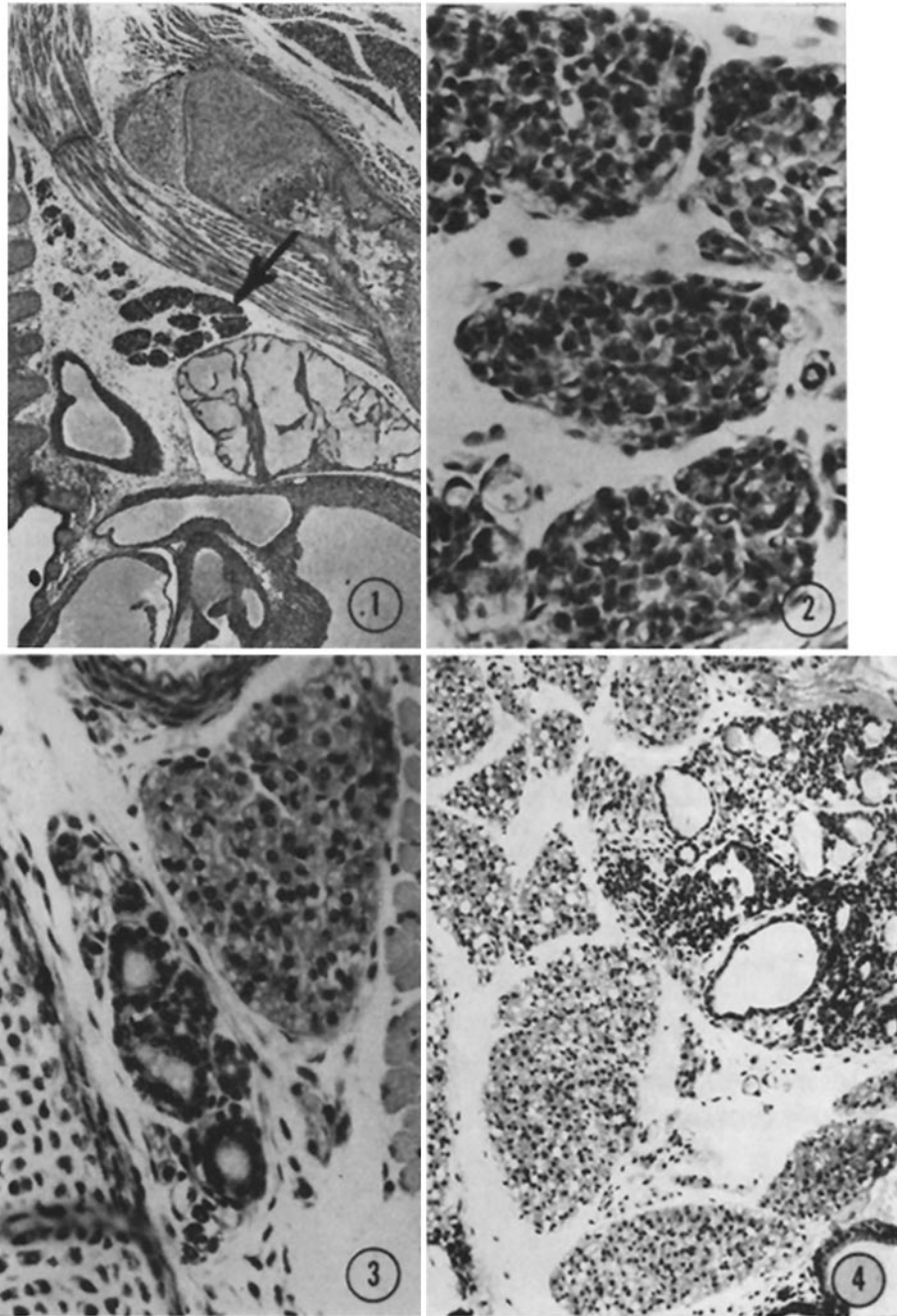


FIG. 1. Newborn nude mouse. Saggital section. In the triangular space bordered by the trachea on the left, the heart at the base, and the sternum as the hypotenuse lies a multilobular organ.  $\times 28$ .

FIG. 2. Newborn nude mouse. Saggital section. Higher magnification of the body seen in Fig. 1. Note that the cells are arranged irregularly and that a few have small vacuoles.  $\times 275$ .

FIG. 3. 4 day old nude mouse. Transverse section. In the upper right-hand corner is a lobule of tissue composed of irregularly arranged cells with vacuolated cytoplasm. In the center is the cystic body.  $\times 250$ .

FIG. 4. 35 day old nude mouse. Transverse section of the upper anterior mediastinum. In the upper-hand corner is one of the cystic bodies. Immediately adjacent to and surrounding it is the lobulated body with many vacuolated cells. In the extreme lower right-hand corner is a cyst from the other member of the organ pair.  $\times 110$ .

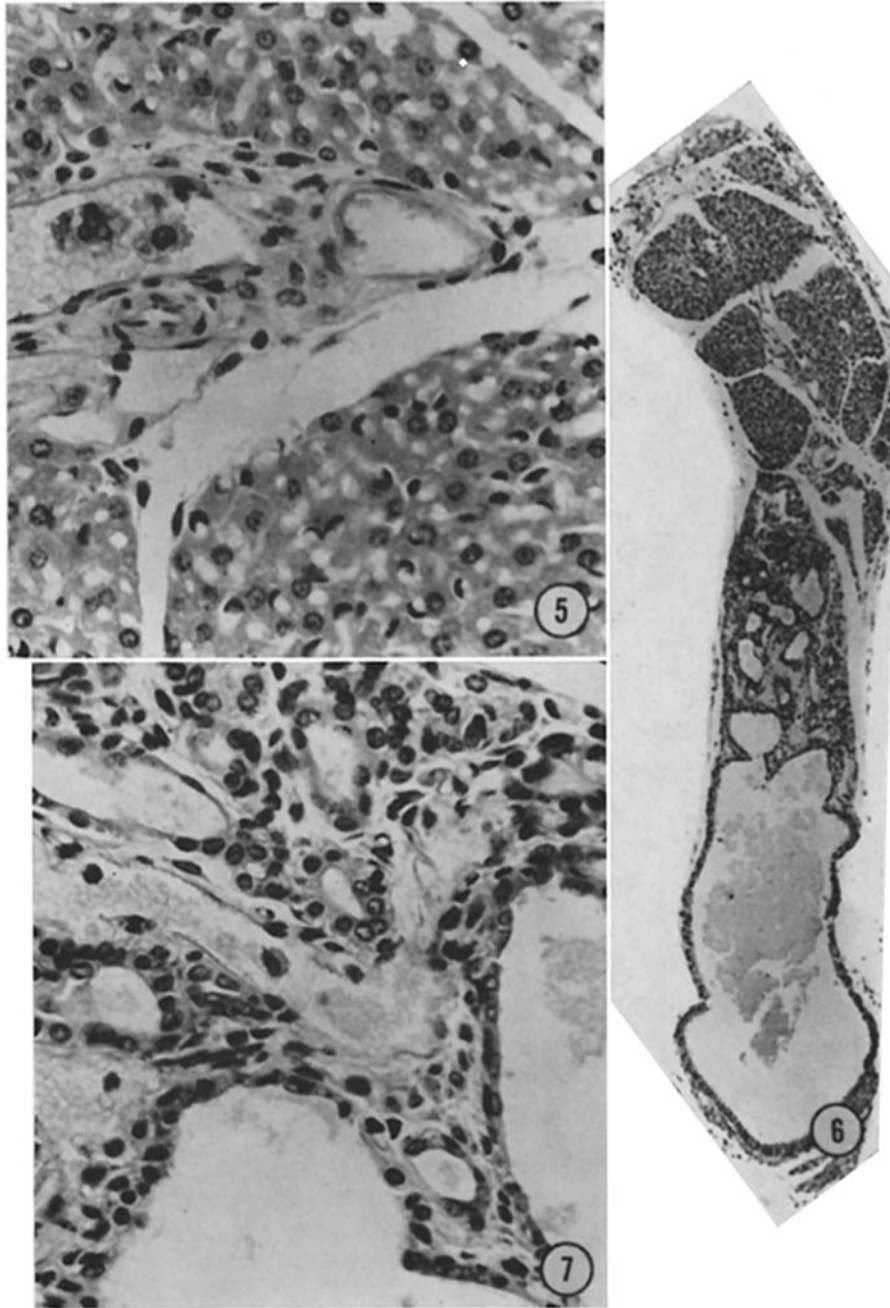


FIG. 5. 53 day old nude mouse. One of two paired bodies with lobulations and irregularly arranged cells with vacuolated cytoplasm. No lymphocytes are present. This animal was one of a group (experiment NU-8) which received  $20 \times 10^6$  normal fetal liver cells when 10 days old.  $\times 440$ .

FIG. 6. 53 day old nude mouse. Multilobular body (at top) with adjoining cystic body. This is the same mouse depicted in Figs. 5 and 7.  $\times 69$ .

FIG. 7. 53 day old nude mouse. The cyst is lined with ciliated epithelium (cf. Figs. 5, 6).  $\times 440$ .

Two of the mice rejected their skin grafts at 16 days. These mice were alive and well 210 days later. The third failed to reject its skin graft. It died at 140 days (Fig. 9). Littermates of nude mice reject C57BL/6 skin grafts by 10 days, untreated nude mice to not reject skin grafts during their life-span (9, 14).

Peripheral white blood cell counts and differentials were done when the mice were 60 and 74 days old (Table I). Each mouse with a thymus graft showed a definite lymphocytosis but did not achieve the levels found in normal mice.

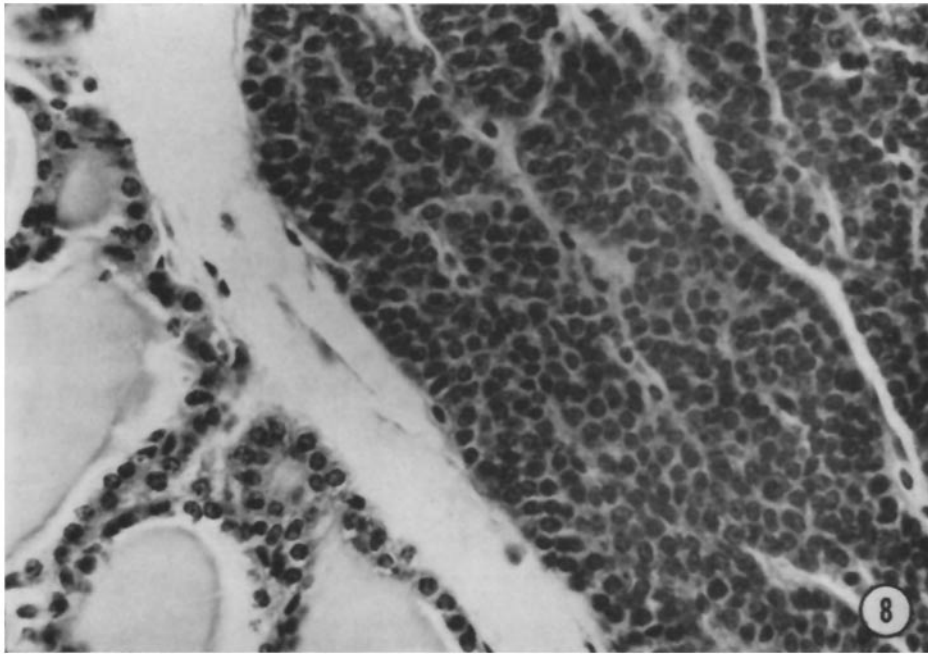


FIG. 8. Nude mouse. Parathyroid (right) and thyroid.  $\times 440$ .

Therefore, as measured by two criteria, circulating lymphocyte count and the ability to reject allografts, a normal thymus can restore a nude mouse.

*Attempts to Repopulate Nude Mice with Normal Fetal Liver.*—If nude mice lack only thymocyte precursors they should develop normal lymphoid tissue when given normal hematopoietic cells, such as fetal liver.

In the first experiment (NU-8)  $20 \times 10^6$  liver cells from 15-day old fetuses were given to one 13-day old and two 10-day old nude mice. In a second experiment (NU-14)  $26 \times 10^6$  liver cells from 16-day old CBA fetuses were used to repopulate four nude mice aged 57, 39, 32, and 31 days.

Four of these seven mice lived longer than nontreated mice of corresponding

ages (Fig. 9). But the difference was not significant. The lower portion of this figure shows the mortality for nude mice in our colony. It shows that 50% of all nudes die by 4 wk of age. The upper portion of the figure shows the time at which an individual mouse was given fetal liver cells and the time of death of

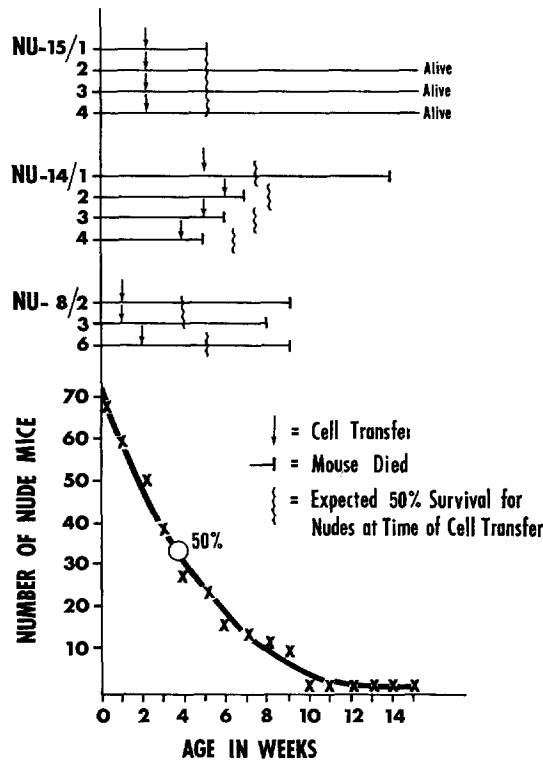


FIG. 9. During a 6 month period, 70 nude mice were born. Their age (in weeks) at death is shown in the lower portion of the figure. Half the mice died before they reached 4 wk of age and none survived 15 wk. In the upper portion of the figure is shown the data from an experiment in which nude mice received a normal thymus graft (NU-15) and two experiments (NU-8, NU-14) in which nude mice were given normal fetal liver. The vertical arrow indicates the time of graft or cell transfer. The vertical bar shows the time of death. The shaded bar show the 50% life expectancy for a mouse at the time of graft or cell transfer.

the mouse. The 50% expected survival age for an untreated nude mouse of the same age as the experimental mouse is also shown.

These fetal liver cell-repopulated nude mice did not have a significant lymphocytosis (Table II) and had no thymocytes in their thymic rudiments (Fig. 5). Therefore, normal fetal liver cannot restore nude mice, and, by implication, the nude mouse may have normal thymocyte precursors. This possibility was tested in the next experiment.

*Transfer of Bone Marrow from Nude Mice to Lethally Irradiated Normal Mice.*—After irradiation the thymus becomes rapidly depleted of thymocytes. Repopulation is accomplished by cells derived from bone marrow or fetal liver (3). If the bone marrow of nude mice has normal thymocyte precursors, they should repopulate the thymus of an irradiated but otherwise normal recipient. Since 70% of circulating lymphocytes are thymus derived (4), and since nude mice have severe lymphopenia (9), the circulating lymphocyte count was used as an index of thymic function.

TABLE I  
*Peripheral White Blood Cell Counts in Three Nude Mice Bearing Normal Thymus Grafts\**

Mice	Age	Total wbc/mm <sup>3</sup>	Lymphocytes	Polymorphs	Monocytes	Lymphocytes /mm <sup>3</sup>
	(days)		%	%	%	
15.2	60	6080	39	57	4	2371
15.3	60	8080	41	46	13	3313
15.4	60	3760	29	65	6	1090
15.2	74	5600	37	52	11	2072
15.3	74	5800	53	41	6	3074
15.4	74	5200	29	67	4	1508

\* Comparable figures for untreated nude and +/- mice are given in Table II.

TABLE II  
*Comparison of Relative and Absolute Lymphocyte Counts in Peripheral Blood of Untreated Nude Mice and Nude Mice Given Fetal Liver Cells\**

	Number	Age range	Lym- phocytes	Lym- phocytes
		days	%	mm
Untreated nude mice	10	32-60	20 (8-28)	359 ± 152
Nude mice given fetal liver	4	23-66	22 (12-32)‡	580 ± 242§
Littermates of nude mice	10	32-60	58 (24-72)	3461 ± 1359

\* Three additional nude mice given fetal liver died before a lymphocyte count was made.

‡ 10 determinations on four mice.

§ Six determinations on four mice.

In experiment NU-10 normal CBA male mice were given 1100 R. 18 hr later four mice were given  $10 \times 10^6$  cells from the pooled bone marrow of five nude mice aged 31-40 days. Four mice were given  $10 \times 10^6$  cells from the pooled bone marrow of six normal littermates of the nude mice. Two mice given no bone marrow cells died within 10 days of cell transfer.

In experiment NU-13 normal CBA mice received the cell transfer 4 hr after irradiation. In this experiment the mice were given either  $8 \times 10^6$  nude bone marrow cells or  $8 \times 10^6$  littermate bone marrow cells. The donor mice were

11-13 days old. Four mice given no bone marrow cells died within 11 days of cell transfer.

The circulating lymphocyte counts of these repopulated mice are shown in Fig. 10. There is no difference between the counts of the mice repopulated with nude bone marrow and the mice repopulated with normal littermate bone marrow. At 75 days after transfer one mouse from each group was sacrificed and its thymus and lymph nodes were examined. Each has a thymus with

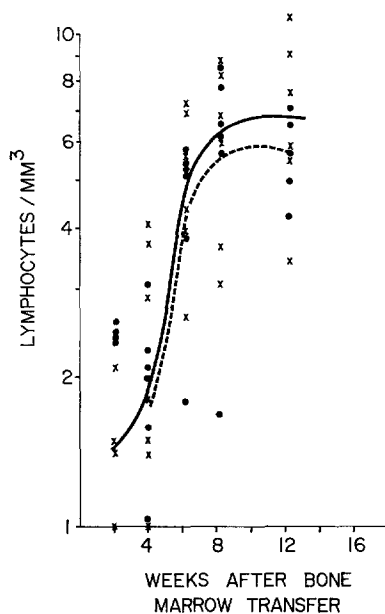


FIG. 10. Peripheral blood lymphocytes/mm<sup>3</sup>  $\times 10^{-3}$  in lethally irradiated CBA mice reconstituted with nude (x—x) or +/? (●—●) bone marrow. Data from two experiments have been combined. One mouse from each group died before the completion of the experiment.

normal cortex and medulla and each had normal paracortical areas in their lymph nodes (Figs. 11, 12).

*Chromosome Studies of Mice Repopulated with Bone Marrow from Nude Mice.*—In order to make certain that the thymocytes of these repopulated mice were indeed donor derived, the experiment described above was repeated with recipient mice (CBA/H) bearing the chromosome markers T6T6 (15, 16).

4 hr after irradiation, six CBA/H T6T6 mice were given  $10 \times 10^6$  bone marrow cells from six nude mice (10-19 days old). Two mice survived until 36 days. On microscopic examination each had a normal thymus with well-defined cortex and medulla, and their lymph nodes had lymphocyte populated thymus-



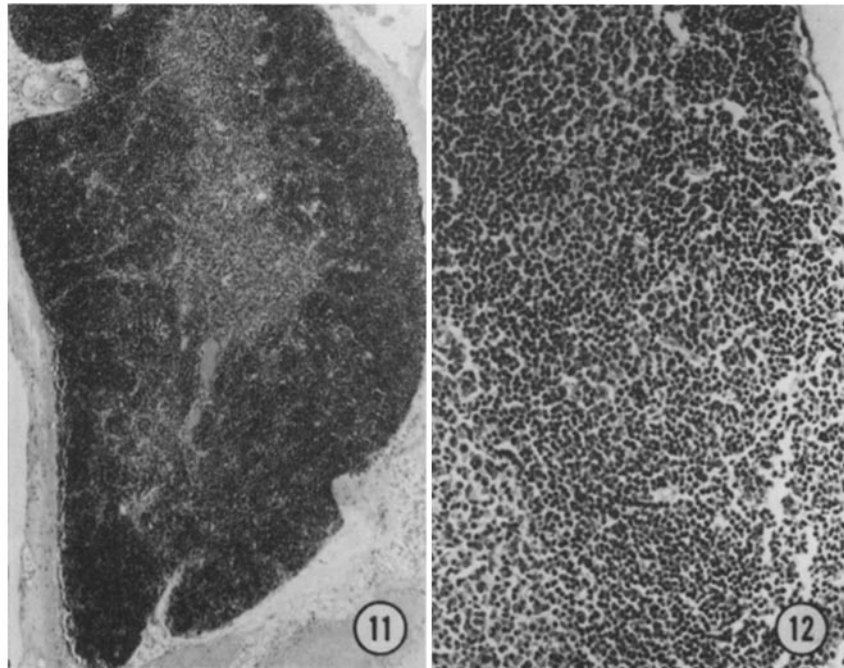


FIG. 11. Thymus of a lethally irradiated CBA mouse reconstituted with bone marrow of a nude mouse (NU-10/1). There is a clearly demarcated medulla and thymocyte-rich cortex.  $\times 38$ .

FIG. 12. Lymph node of a lethally irradiated CBA mouse reconstituted with bone marrow of a nude mouse (NU-10/1). The paracortical region has many lymphocytes.  $\times 176$ .

TABLE III

*Summary of Eight Attempts to Graft Nude Thymic Rudiments to Phenotypically Normal Mice\**

Age of donor†	Recipient	Age of recipients	Duration of graft	Microscopic appearance
			<i>days</i>	
4, 4	Sibs	22 days	9, 92	Alymphoid
0, 0, 0	3rd back-cross generation	4 months	7, 21, 92	Alymphoid
1	3rd back-cross generation	4 months	21	Alymphoid
25, 25	Sibs	25 days	82, 82	Alymphoid

\* All the grafted rudiments were identified microscopically and none had developed lymphocytes.

† Day of birth = 0.

dependent areas. In each mouse 10 thymus cells in metaphase with 40 clear chromosomes were counted. Only one cell had a chromosome which could be considered typical for T6. In contrast, 10 thymus cells in each of two normal T6T6 mice were similarly examined, and they all showed typical T6 chromo-

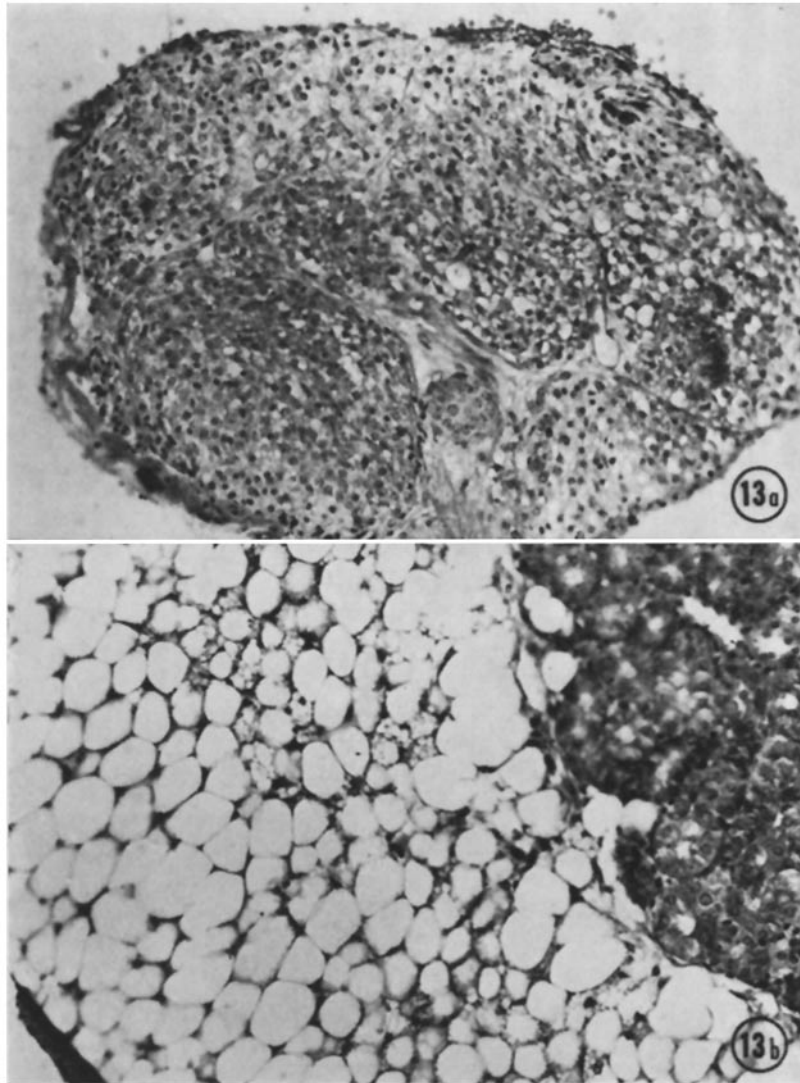


FIG. 13. (a) One lobe of thymic rudiment of a 4 day old nude mouse. (b) The other lobe 92 days after grafting to a kidney in a normal mouse. No thymocytes are seen, and the cells are highly vacuolated.  $\times 360$ .

somes. The probability that the cells in the thymus of the mice repopulated with nude bone marrow were drawn from a population of T6T6 cells was  $< 0.005$ . Therefore, the thymocytes in the irradiated, repopulated mice were donor derived.

*Fate of Nude Thymic Rudiments Grafted to Normal Mice.*—Thymic rudiments were grafted to phenotypically normal mice from the same backcross generation. At various times after grafting the recipients were sacrificed and the graft sites examined microscopically. At 9 days after grafting, the lobulated structure of the tissue was still evident, but the cytoplasm of the cells was more vacuolated. The smaller body of cysts (or tubules) was also present and unchanged. There were no lymphocytes in or near the graft. By 21 days, the cytoplasm was highly vacuolated. The smaller body was unchanged. At 92 days the grafts showed no signs of rejection or of lymphopoiesis (Table III and Fig. 13).

#### DISCUSSION

A normal thymus can function when grafted to a nude mouse. This confirms the experiments of Pantelouris (14) and suggests that nude mice are not producing a substance toxic to either thymocyte precursors or thymic epithelium. The lymphocytosis and skin graft rejection observed in these thymus-grafted mice could have been due to the proliferation of donor thymocytes from the original graft. However, by 4–5 wk a normal thymic graft will be entirely repopulated by host derived thymocytes (Raff, M. C., personal communication).

The failure of normal fetal liver to restore thymus function is inconsistent with the conclusion that nude mice have a defect of thymocyte precursors. However, the failure of a putative nude thymus rudiment to support thymocyte proliferation when placed in a normal environment suggests that the fault lies not in the precursors but in the rudiment. A note of caution is necessary since this is negative evidence and these mice are not derived from an inbred line and are not histocompatible. Nevertheless, nude bone marrow precursors can repopulate a CBA thymus. With the development of the congenic pair CBA, CBA·nu this question should be resolved.

Previously it was shown that nude spleen cells have the ability to cooperate with normal thymus cells to produce a normal immune response to sheep red blood cells (9). That is, they have the precursors of antibody-forming cells.

The ability of nude bone marrow to successfully restore peripheral lymphocytes and to repopulate the thymus and thymus-dependent areas of lethally irradiated normal mice demonstrates the presence of normal thymocyte precursor cells in nude mice.

Taken together, these results suggest strongly that nude mice suffer from a defect of their thymic epithelium and that the absence of thymocytes is secondary. The nature of this defect and the possibility that it might itself be secondary to a lesion of an inducing tissue is yet to be explored.

## SUMMARY

Nude mice bearing grafts of normal thymus reject skin grafts and have low, but higher than usual, lymphocyte counts. Nude bone marrow can successfully repopulate the thymus and thymus-derived areas of lethally irradiated recipient mice. Attempts to reconstitute nude mice with normal fetal liver failed. The so-called thymic rudiment of nude mice when grafted to normal mice did not develop thymocytes. These experiments show that nude mice suffer from a defect of the epithelial portion of the thymus rather than of the precursors of thymocytes.

## REFERENCES

1. Miller, J. F. A. P., and G. T. Mitchell. 1969. Thymus and antigen-reactive cells. *Transplant. Rev.* **1**:92.
2. Owen, J. J. T., and M. A. Ritter. 1969. Tissue interaction in the development of thymus lymphocytes. *J. Exp. Med.* **129**:431.
3. Owen, J. J. T., and M. C. Raff. 1970. Studies on the differentiation of thymus-derived lymphocytes. *J. Exp. Med.* **132**:1216.
4. Maximow, A. 1909. Untersuchungen über Blut und Bindegewebe. II. Über die Histogenese der thymus bei Säugetieren. *Arch. Mikrosk. Anat. Entwicklungsmech.* **74**:525.
5. Flanagan, S. P. 1966. 'Nude,' a new hairless gene with pleiotropic effects in the mouse. *Genet. Res.* **8**:295.
6. Pantelouris, E. M. 1968. Absence of thymus in a mouse mutant. *Nature (London)*. **217**:370.
7. de Sousa, Maria A. B., Delphine M. V. Parrott, and E. M. Pantelouris. 1969. The lymphoid tissues in mice with congenital aplasia of the thymus. *Clin. Exp. Immunol.* **4**:637.
8. Raff, M. C., and H. H. Wortis. 1970. Thymus dependence of  $\theta$  bearing cells in the peripheral lymphoid tissues of mice. *Immunology*. **18**:931.
9. Wortis, H. H. 1971. Immunological responses of 'nude' mice. *Clin. Exp. Immunol.* **8**:305.
10. Fox, M., and I. M. Zeiss. 1961. Chromosome preparation from fresh and cultured tissues using a modification of the drying technique. *Nature (London)*. **192**:1213.
11. Croft, C. J. 1969. A reinvestigation of the origin of cells in grafted tumors, using the mouse T6 chromosome. *Int. J. Cancer*. **4**:86.
12. Billingham, R. E., and P. B. Medawar. 1951. The technique of free skin grafting in mammals. *J. Exp. Biol.* **28**:385.
13. Pantelouris, E. M., and J. Hair. 1970. Thymus dysgenesis in *nude (nu nu)* mice. *J. Embryol. Exp. Morphol.* **24**:615.
14. Pantelouris, E. M. 1971. Observations on the immunobiology of 'nude' mice. *Immunology*. **20**:247.
15. Ford, C. E., J. L. Hamerton, D. W. H. Barnes, and J. F. Loutit. 1956. Cytological identification of radiation chimaeras. *Nature (London)*. **177**:452.
16. Eicklem, H. S., J. F. Loutit, and C. E. Ford. 1966. The use of chromosome markers. In *Tissue Grafting and Radiation*. Academic Press, New York. 197.