

Available online at [www.sciencedirect.com](http://www.sciencedirect.com)

ScienceDirect

journal homepage: <http://Elsevier.com/locate/radcr>

## Musculoskeletal

# Hot shoulder PET/CT lesion: Unusual presentation of tenosynovial giant cell tumor

Steven Lewis MD\*, Lance Edmonds MD, Ely Wolin MD

Department of Radiology, David Grant Medical Center, Travis AFB, CA, USA

### ARTICLE INFO

#### Article history:

Received 15 December 2017

Accepted 3 February 2018

Available online

#### Keywords:

PET

Shoulder

Tenosynovial giant cell tumor

### ABSTRACT

We present a case of a tenosynovial giant cell tumor (TGCT) incidentally discovered at the shoulder on PET/CT, in a patient with history of thyroid cancer. Many documented cases of TGCT have been incidentally imaged by PET/CT and have been found to have varying levels of metabolic activity, however the shoulder location is unusual. This type of musculoskeletal lesion often has MRI characteristics, such as gradient echo blooming, which can render a confident diagnosis without need for biopsy.

© 2018 the Authors. Published by Elsevier Inc. under copyright license from the University of Washington. This is an open access article under the CC BY-NC-ND license (<http://creativecommons.org/licenses/by-nc-nd/4.0/>).

## Introduction

Tenosynovial giant cell tumors (TGCTs) are benign lesions arising from tendon sheath, bursa, or synovium. Although referred to as TGCT in this report, interchangeable terms include “pigmented villonodular tenosynovitis” and “giant cell tumor of the tendon sheath” [1]. This process is histologically identical to pigmented villonodular synovitis (PVNS), and pathology typically demonstrates hypertrophy of the synovium with hemosiderin deposition [1]. PVNS occurs most commonly in the large joints (predominantly knee), whereas TGCT occurs in the distal extremities such as wrist, hand, ankle, and foot [1]. Typical magnetic resonance imaging (MRI) appearances of PVNS and TGCT feature a hyperenhancing soft tissue mass with adjacent bone erosions and associated hemosiderin gradient echo sequence blooming. Radiologic evidence of hemosiderin deposition (blooming) is a key feature that can help distinguish TGCT from tendon sheath fibroma, a similar entity [2]. Overall,

imaging characteristics of TGCT taken together with an appropriate patient history are fairly specific; however, they cannot entirely exclude unrelated lesions such as hemorrhagic soft tissue sarcoma.

Although the TGCT and PVNS are histologically identical, their workup and management are different. TGCT suggests a localized extra-articular discrete tumor in a distal extremity, whereas PVNS is a diffuse, symptomatic, and sometimes aggressive process which is generally managed with wide local excision and synovectomy. PVNS is considered neoplastic but not malignant, although rarely undergoes malignant transformation to sarcoma [1]. The classic presentation of PVNS is within the intra-articular knee, although it can also present at other large joints such as the shoulder. TGCT is commonly found in the distal extremities such as hand-wrist or ankle-foot. It is unusual to present at the proximal limbs or within larger muscles.

Positron emission tomography (PET) is a nuclear medicine modality that takes advantage of glucose metabolism physiology

Competing Interests: The authors have declared that no competing interests exist.

\* Corresponding author.

E-mail address: [steven.lewis7@gmail.com](mailto:steven.lewis7@gmail.com) (S. Lewis).

<https://doi.org/10.1016/j.radcr.2018.02.006>

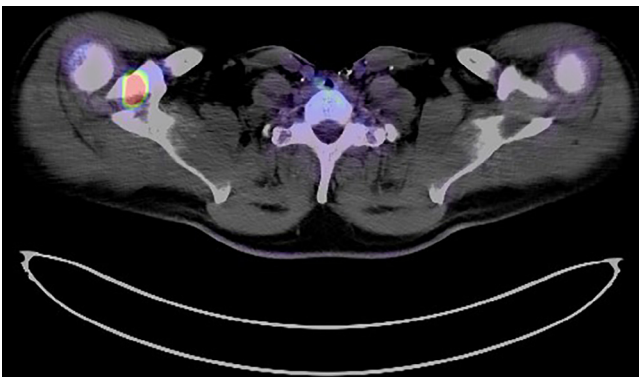
1930-0433/© 2018 the Authors. Published by Elsevier Inc. under copyright license from the University of Washington. This is an open access article under the CC BY-NC-ND license (<http://creativecommons.org/licenses/by-nc-nd/4.0/>).

for medical imaging. This imaging study is often performed to search for and measure metabolic activity of malignant lesions. Briefly, fluorodeoxyglucose (FDG) is radiolabeled with radioactive fluorine-18 and injected intravenously. This radiotracer accumulates in any structure with significant glucose metabolism. The distribution of this radiotracer is assessed by the detection and computer-aided localization of positrons emitting in opposite directions from the source of radioactive decay. The positional data from these positrons are usually merged to a simultaneously acquired computed tomography (CT) scan, thus providing excellent anatomic localization of suspicious areas of glucose metabolism. The merged imaging data, a PET/CT, are very useful for such tasks as staging malignant disease, assessing response to chemotherapy, and identifying biopsy targets.

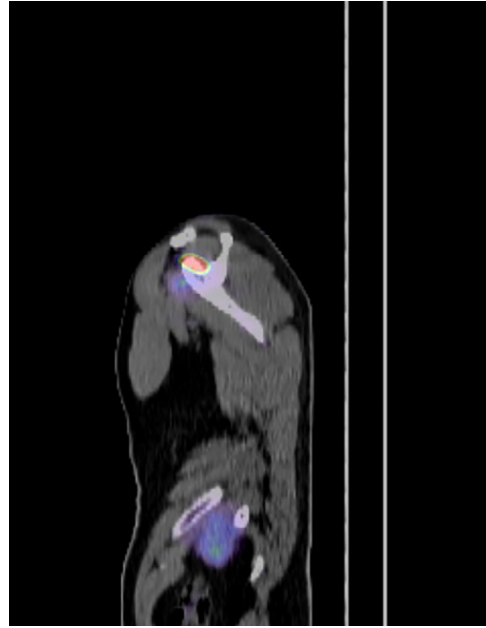### Case report

We present a case of a 58-year-old man with a history of papillary thyroid cancer, tall cell variant, who is status post thyroid resection. The patient underwent a PET/CT examination for surveillance, which demonstrated no suspicious abnormality except for high level metabolic activity localized to the right shoulder between the base of the coracoid process and the anterior aspect of the supraspinatus muscle (Figs. 1 and 2). Maximum standardized uptake value (SUV) in this area was 12. On corresponding CT, no abnormality was identified to correlate with this abnormal focal metabolic activity. This focus at the shoulder was considered suspicious for metastatic disease, given the history of thyroid cancer.

A contrast-enhanced shoulder MRI was performed to better assess the anatomy of the underlying lesion, and revealed a circumscribed enhancing mass measuring  $2.4 \times 0.9 \times 1.6$  cm positioned at the base of the coracoid process adjacent to the neurovascular bundle near the spinoglenoid notch (Figs. 3-5.). This mass appeared likely separated from the supraspinatus muscle, although this distinction could not be made on the prior PET/CT. No supraspinatus or infraspinatus muscle atrophy was present to suggest long-standing supraspinatus nerve impingement.

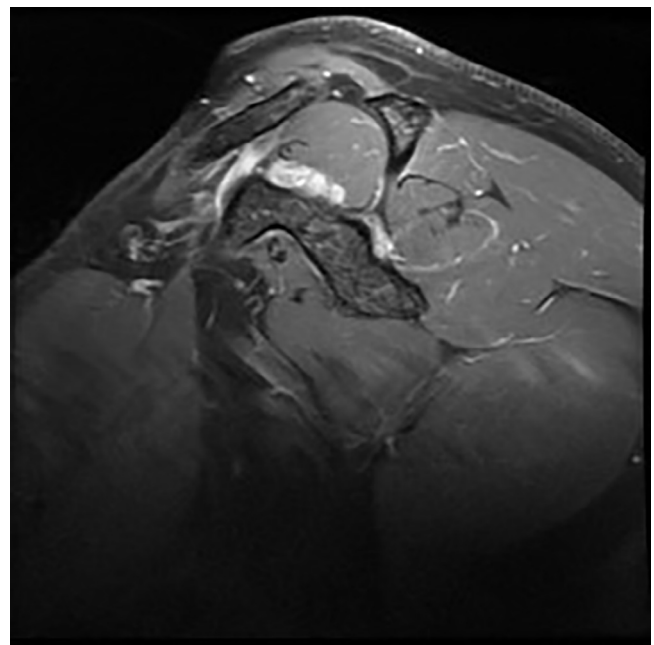


**Fig. 1 – Axial PET/CT demonstrates significant increased metabolic activity at the right shoulder.**

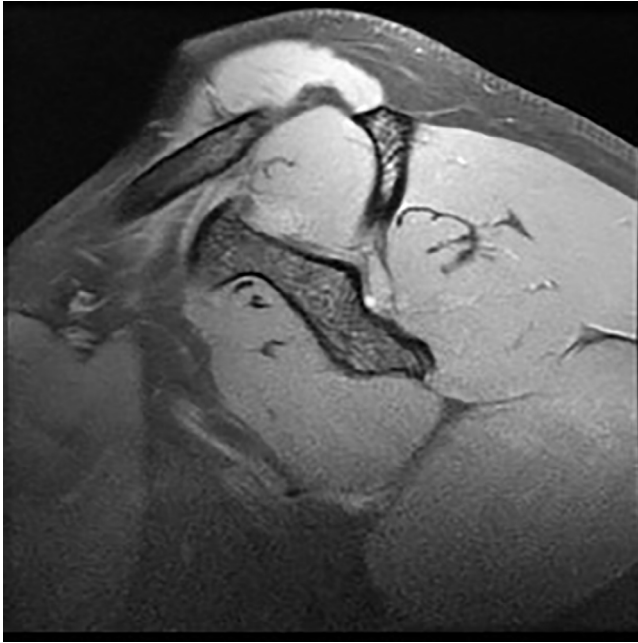


**Fig. 2 – Sagittal positron emission tomography/computed tomography image with metabolic activity corresponding to known lesion.**

Given the suspicion for metastatic thyroid cancer, this mass was biopsied. Initial biopsy attempt with fine-needle aspiration was essentially inconclusive, could not rule out thyroid cancer metastatic lesion. The patient was referred for a core biopsy. The core biopsy demonstrated benign fibrous tissue with chronic inflammation and foamy macrophages, consistent with tenosynovial giant cell tumor and was negative for any findings suggesting malignancy. A repeat MRI was performed with



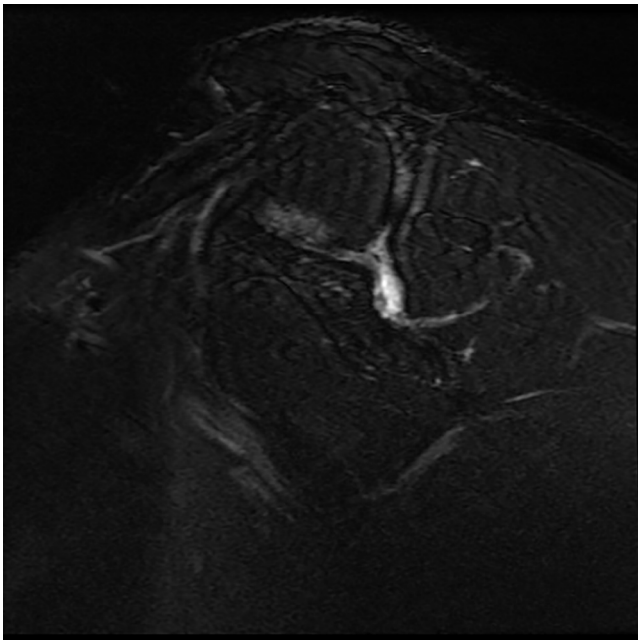
**Fig. 3 – Sagittal T1FS postcontrast image demonstrates avid enhancement within the tenosynovial giant cell tumor.**



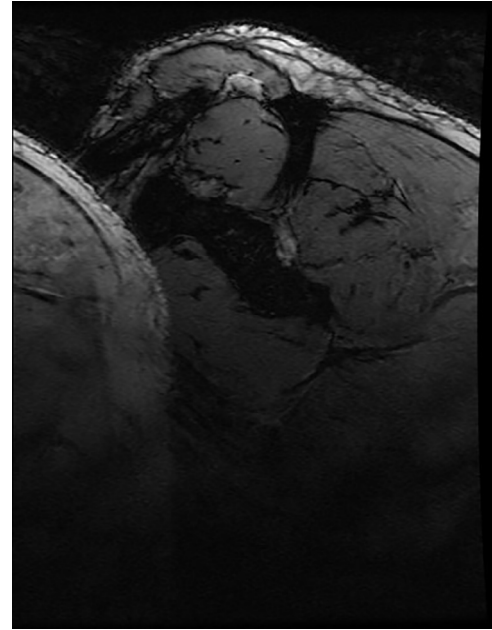
**Fig. 4 – Sagittal T1FS image demonstrates mild T1 hyperintensity within the tenosynovial giant cell tumor.**

an added gradient echo sequence, which demonstrated mild gradient echo susceptibility consistent with the diagnosis of TGCT (Fig. 6).

The patient was asymptomatic, with no mass or motion limitation at the right shoulder. On evaluation by orthopedic surgery, the decision was made to pursue clinical follow-up rather than immediate surgical management.



**Fig. 5 – Sagittal T2FS image demonstrates mild to moderate heterogeneous T2 hyperintensity within known tenosynovial giant cell tumor.**



**Fig. 6 – Sagittal gradient echo image demonstrates no significant blooming within the tenosynovial giant cell tumor, unexpected given known pathology.**

## Discussion

In a patient with cancer, the discovery of a metabolically active lesion within or adjacent to skeletal muscle but not clearly involving bone should raise suspicion for a coexistent process. It should not be conclusively diagnosed as a metastatic lesion solely by PET imaging. Distant metastatic lesions to skeletal muscle as the sole suspicious abnormality would be unusual in thyroid cancer or in any cancer. The differential diagnosis must include soft tissue sarcoma or malignant nerve sheath tumor, among other entities. Additional imaging and tissue diagnosis should be pursued in such a situation, as they were in our case. If equivocal, a larger bore biopsy device or an excisional biopsy of the lesion should be considered. In our case, a multidisciplinary team had the appropriate index of suspicion to obtain a larger biopsy sample and then to confirm the results with gradient echo MRI sequence. Had the lesion had been misdiagnosed on PET/CT as metastatic thyroid cancer, the patient could have received an unindicated high-dose radioiodine ablation. Our approach also helped avoid the potential morbidity of a surgical excision for this benign and asymptomatic lesion.

This case study highlights the occurrence of PET/CT incidental discovery of TGCTs in particular and metabolically active soft tissue lesions in general. Although our lesion was conspicuous and suspicious, the foamy macrophages on biopsy were suggestive of inflammation and consistent with TGCT pathology. It has been suggested that the increased presence of monocytes and macrophages, due to TGCT tumor cell  $t(1:2)(p13;q37)$  translocation and resulting in increased colony stimulating factor 1 (CSF1) expression, is directly responsible for the increased FDG uptake [3]. The increased expression of

GLUT-1 and hexokinase II within macrophage-containing lesions has been reported in the literature to correlate with SUVmax and is thought to explain the mechanism of the increased FDG uptake [3]. Any known case reports of non-PET-avid TGCT, particularly with biopsy findings describing macrophage content, would be a welcome addition to the literature.

A 2016 study in *Clinical Nuclear Medicine* assessed 14 patients with cancer using PET/CT imaging and coexistent PVNS [4]. Six of the patients had at least 1 comparison PET/CT and 5 of the patients received chemotherapy for their target malignancies [4]. Fluctuations in PVNS lesion SUVmax were present and often pronounced but there was no statistical relationship between PVNS SUVmax with either time or with the presence or absence of chemotherapy treatment [4]. That study also found no statistical difference in SUVmax values between subtypes of PVNS to include intra-articular PVNS, diffuse PVNS, or giant cell tumor of the tendon sheath [4]. All 6 patients with serial PET/CT were asymptomatic from their PVNS, thus no correlation could be attempted between SUVmax and patient symptoms [4]. In our case, the patient was also asymptomatic. It may be reasonable to infer that symptomatic TGCT lesions would be subject to greater inflammation, more macrophage involvement, and therefore higher SUVmax values. However, to our knowledge, this relationship has yet to be explored.

Literature review also suggests that the supraspinatus compartment of the shoulder in our case was an extremely unusual location for a tenosynovial giant cell tumor. One case series from the University of Louisville School of Medicine examined 65 TGCT cases, all of which were located in the hand [5]. Multiple additional case series and literature reviews also suggested that the vast majority of these lesions occur in the hand [6,7]. One case series from Japan discussed 2 separate cases of PET hot soft tissue TGCTs, which were located adjacent to a cervical vertebral body lamina and in the extra articular hip joint [8].

The presence of biopsy-proven TGCT in our case, unusual in location, raises the question of tumor origin. A case report from Korea describes a TGCT that arose within the thigh and was presumed to represent a sarcoma or nodular fasciitis before resection [9]. In that case, as in our case, pathology demonstrated polygonal mononuclear cells, foamy macrophages, and multinucleated giant cells. The Korean case pathologic specimen

also revealed local hemosiderin deposition, which in our case was diagnosed by MRI features. The Korean case proved to be entirely intramuscular and had no association to a tendon sheath or bursa [9]. Such an origin is difficult to explain, given conventional knowledge of TGCT etiology. In our case, the TGCT could arise from the supraspinatus tendon sheath, the subacromial subdeltoid bursa, or simply be associated with the supraspinatus muscle. In the previously referenced study from *Clinical Nuclear Medicine*, 7 of 14 PVNS type lesions were TGCTs associated with tendon sheaths and 1 was associated with the shoulder (teres major tendon sheath) [4]. This suggests that our case of TGCT at the shoulder, while rare, is not unheard of.

#### REFERENCES

- [1] Murphey MD, Rhee JH, Lewis RB, Fanburg-Smith JC, Flemming DJ, Walker EA. Pigmented villonodular synovitis: radiologic-pathologic correlation. *Radiographics* 2008;5:1493–518.
- [2] Dinauer PA, Brixey CJ, Moncur JT, Fanburg-Smith JC, Murphey MD. Pathologic and MR imaging features of benign fibrous soft-tissue tumors in adults. *Radiographics* 2007;1:173–87.
- [3] Pallas A, Hagge R, Borys D, Hunter J. Intense FDG uptake in an intra-articular giant cell tumor of the tendon sheath (pigmented villonodular synovitis) mimics metastatic melanoma. *Radiology Case Reports*, Volume 4, Issue 4, 2009.
- [4] Broski SM, Murdoch NM, Skinner JA, Wenger DE. Pigmented villonodular synovitis: potential pitfall on oncologic 18F-FDG PET/CT. *Clinical Nuclear Medicine*, Vol 41, Number 1, Jan 2016.
- [5] Adams EL, Yoder EM, Kasdan ML. Giant cell tumor of the tendon sheath: experience with 65 cases. *Eplasty* 2012;12:e50.
- [6] Di Grazia S, Succi G, Graggetta F, Perrotta RE. Giant cell tumor of tendon sheath: study of 64 cases and review of literature. *G Chir* 2013;34(5–6):149–52. doi:10.11138/gchir/2013.34.5.149.
- [7] Suresh SS, Zaki H. Giant cell tumor of tendon sheath: case series and review of literature. *J Hand Microsurg* 2010;2(2):67–71. doi:10.1007/s12593-010-0020-9.
- [8] Takeuchi A, Yamamoto N, Hayashi K, Miwa S, Takahira M, Fukui K, et al. Tenosynovial giant cell tumors in unusual locations detected by positron emission tomography imaging confused with malignant tumors: report of two cases. *BMC Musculoskelet Disord* 2016;17:180. doi:10.1186/s12891-016-1050-7.
- [9] Lee YJ, Kang Y, Jung J, Kim S, Kim CH. Intramuscular tenosynovial giant cell tumor, diffuse-type. *J Pathol Transl Med* 2016;50(4):306–8. doi:10.4132/jptm.2015.11.15.