



# Arthroscopic Repair of the Lateral Ulnar Collateral Ligament of the Elbow Using a Knotless Suture Anchor

Eugene T. Ek, M.B.B.S., Ph.D., F.R.A.C.S., and Kemble K. Wang, M.B.B.S., F.R.A.C.S.

**Abstract:** The lateral collateral ligament (LCL) complex of the elbow plays a crucial role in the stability of the elbow joint, especially to varus loads. Deficiency of particularly the lateral ulnar collateral component of the LCL can lead to chronic posterolateral rotatory instability, which can be functionally debilitating and can lead to a rapid onset of early degenerative arthritis. Commonly, in the setting of acute rupture of the LCL, the ligament is repaired using an open technique with suture anchor fixation to the lateral epicondyle insertion point. However, with advancing arthroscopic techniques, it has become possible to repair the LCL arthroscopically. We present a relatively simple method for an all-arthroscopic repair of the LCL to the humerus using a knotless suture anchor technique.

The lateral collateral ligament (LCL) complex of the elbow comprises 4 major components: radial collateral ligament, lateral ulnar collateral ligament (LUCL), accessory LCL, and annular ligament.<sup>1</sup> Elbow dislocations often lead to disruption of the LCL complex, with or without associated fractures. In a proportion of these patients, chronic instability of the elbow, known as posterolateral rotatory instability,<sup>2</sup> can develop, which is attributed in particular to damage to the LUCL part of the LCL. Because of its importance in elbow stability, it is generally accepted that the LCL should be repaired if the elbow is being treated surgically or if instability symptoms persist in the chronic setting.<sup>3,4</sup> Although primary repair is favored for acute injuries, both repair and reconstruction have been advocated in the chronic setting.<sup>5,6</sup>

When injured, the LCL is usually avulsed from its humeral origin, the fibers of which consist of the radial collateral ligament and LUCL.<sup>7</sup> Various repair techniques have been described for repairing the humeral attachment, although the optimal method remains controversial.<sup>8</sup> The purpose of this article is to describe an all-arthroscopic technique for repairing the humeral origin of the avulsed LCL using a knotless suture anchor.

## Surgical Technique

### Patient Setup and Preparation

The patient is placed on the operating table in the lateral decubitus position with the arm secured on an arm holder. The elbow is positioned at 90° of flexion with the forearm allowed to hang free. A nonsterile tourniquet is placed high on the axilla and inflated to 250 mm Hg after limb exsanguination. The bony and soft-tissue landmarks are identified before commencement of the procedure (Fig 1), and 20 mL of normal saline solution is injected to distend the elbow capsule using a 19-gauge needle through the “soft spot,” as determined by the center of a triangle between the olecranon tip, lateral epicondyle, and radial head.

### Arthroscopic Assessment

The sequence of elbow arthroscopy in terms of whether to enter the anterior or posterior compartment first is dependent on individual surgeon preference. It is the preference of the senior author (E.T.E.) to perform the posterior-compartment arthroscopy first. The viewing portal is established at the soft spot, with an accessory posterolateral working portal established

From the Melbourne Orthopaedic Group (E.T.E.), Windsor; and Department of Surgery, Monash Medical Centre, Monash University (E.T.E., K.K.W.), Melbourne, Australia.

The authors report the following potential conflict of interest or source of funding: E.T.E. receives support from Zimmer, Device Technologies. Full ICMJE author disclosure forms are available for this article online, as supplementary material.

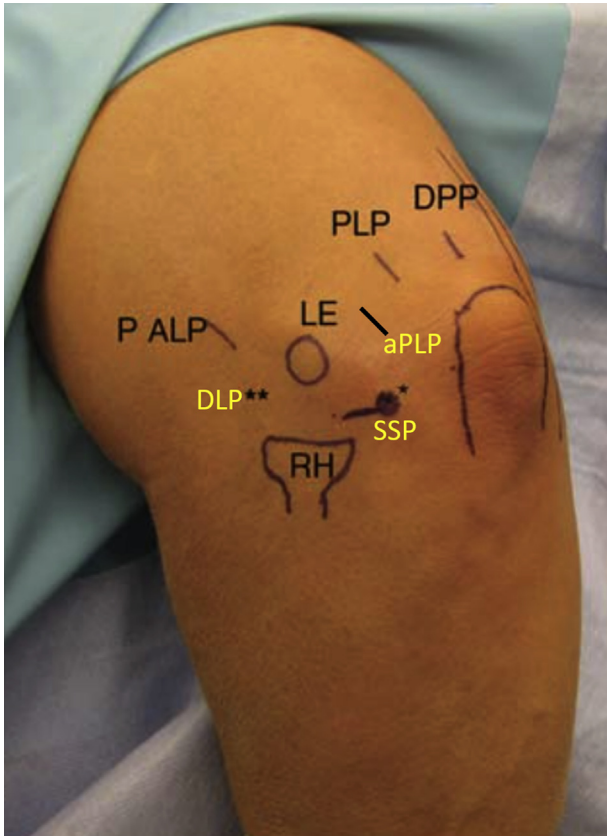
Received May 21, 2017; accepted August 10, 2017.

Address correspondence to Eugene T. Ek, M.B.B.S., Ph.D., F.R.A.C.S., Melbourne Orthopaedic Group, 33 The Avenue, Windsor, Melbourne, VIC 3181, Australia. E-mail: [eugene.ek@mog.com.au](mailto:eugene.ek@mog.com.au)

© 2017 by the Arthroscopy Association of North America. Published by Elsevier. This is an open access article under the CC BY-NC-ND license (<http://creativecommons.org/licenses/by-nc-nd/4.0/>).

2212-6287/17698

<https://doi.org/10.1016/j.eats.2017.08.057>



**Fig 1.** Setup and portals for arthroscopy. The patient is in the lateral decubitus position, with the right arm on an arm holder and the elbow at 90°. \* indicates the DLP. \*\* indicates the SSP. (aPLP, accessory posterolateral portal; DLP, direct lateral portal; DPP, direct posterior portal; LE, lateral epicondyle, P ALP, proximal anterolateral portal; PLP, posterolateral portal; RH, radial head; SSP, soft spot portal.)

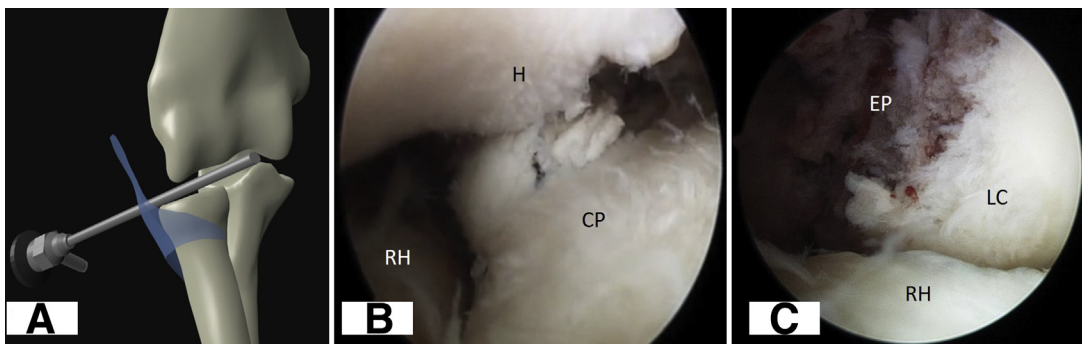
approximately 2 cm proximally. Commonly, in the acute setting, a hemarthrosis is present, which needs to be cleared with a shaver for adequate visualization. Depending on the experience of the surgeon, other concomitant injuries can be addressed arthroscopically, such as radial head fracture requiring fixation. All bony

internal fixation should be performed before repair of the LCL, as would be the case in open surgery.

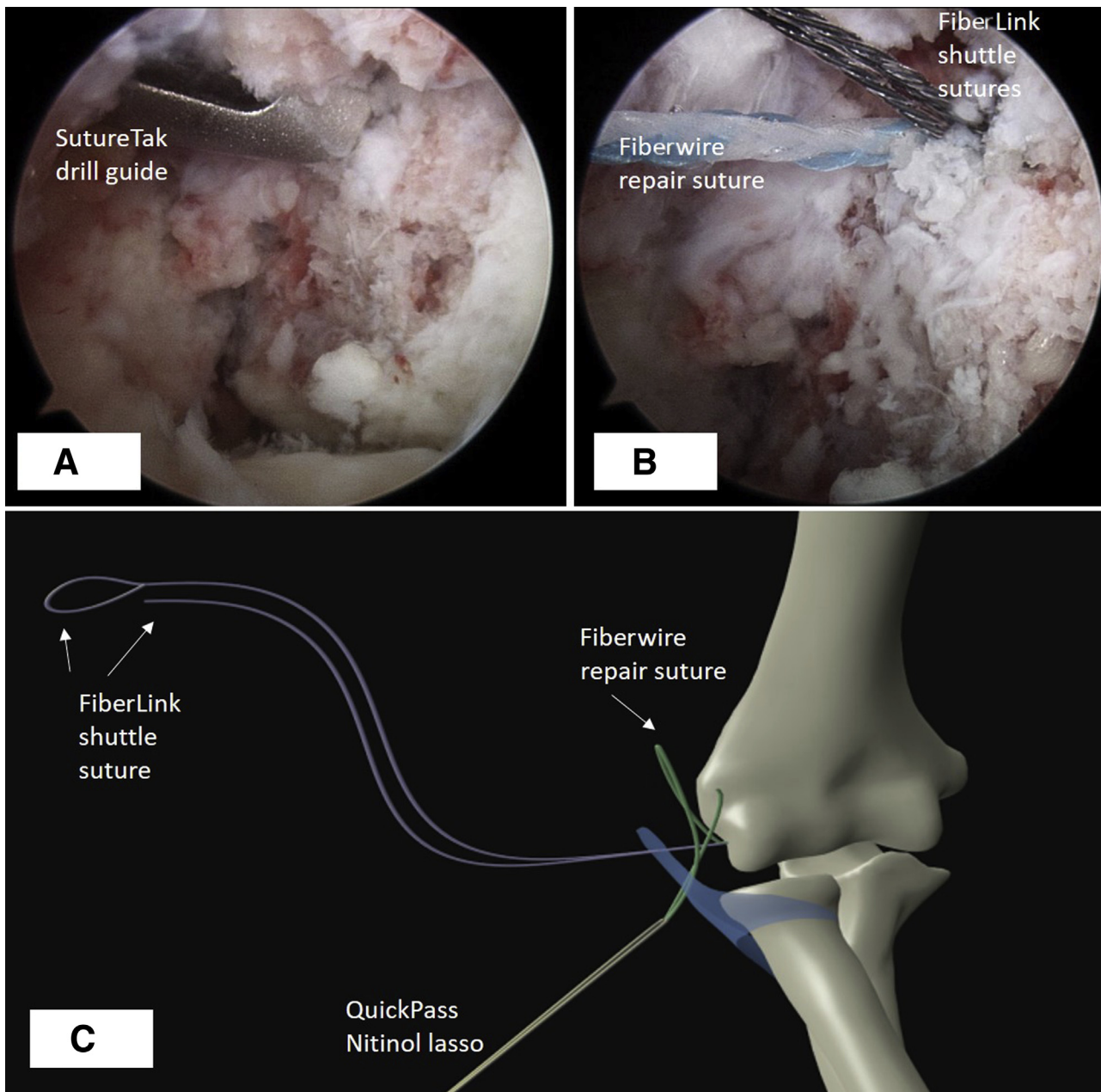
With significant disruption of the LCL, a clear “drive-through” sign may be observed, whereby the arthroscope will be able to be advanced all the way to the anterior compartment through the radiocapitellar joint (Fig 2A). In other cases one may see features of posterolateral rotatory instability, with increased gapping of the ulnohumeral joint when the elbow is placed in extension, supination, and slight valgus, resulting in incongruity of the ulnohumeral joint (Fig 2B). By advancing the arthroscope to the lateral side of the radiocapitellar joint, one will be able to see the loss of the humeral attachment of the LCL to the lateral epicondyle, which will become more evident with varus stress on the elbow (Fig 2C).

### Arthroscopic Repair of LCL

The LCL repair is primarily performed through the posterolateral compartment of the elbow, using a knotless suture anchor (Video 1). First, the lateral epicondyle, where the LCL inserts, is debrided with a shaver, removing scar tissue and any debris. Gentle burring of the lateral epicondyle can be performed to the subchondral bone to allow for enhanced ligament-to-bone healing. A localizing needle is then inserted over the lateral side of the elbow, in line with the insertion point of the lateral epicondyle, and a direct lateral portal is established. A 3.0-mm knotless bioabsorbable suture anchor (SutureTak; Arthrex, Naples, FL) is inserted into the isometric point on the lateral epicondyle (Fig 3A). This point should be clearly visualized before insertion of the anchor. A drill guide is inserted first through the direct lateral portal, and a 2.4-mm drill hole is made. The SutureTak is then inserted through the guide into the prepared hole and impacted with a mallet. The single-strand No. 2-0 FiberWire repair suture (Arthrex) attached to the anchor is separated from the double-strand FiberLink shuttling suture (Arthrex) (Fig 3B). The aim is to pass the FiberWire repair suture through the substance of the proximal LCL. This is performed with the QuickPass 90° SutureLasso (Arthrex), which is inserted through the



**Fig 2.** Arthroscopic assessment of posterolateral rotatory instability and avulsed lateral collateral ligament. The viewing portal is through the soft spot portal. (A) Positive drive-through sign. (B) Incongruity of left ulnohumeral joint space. (C) Bare wall of lateral epicondyle where lateral collateral had been avulsed. (CP, coronoid process; EP, lateral epicondyle; H, humerus; LC, lateral condyle; RH, radial head.)

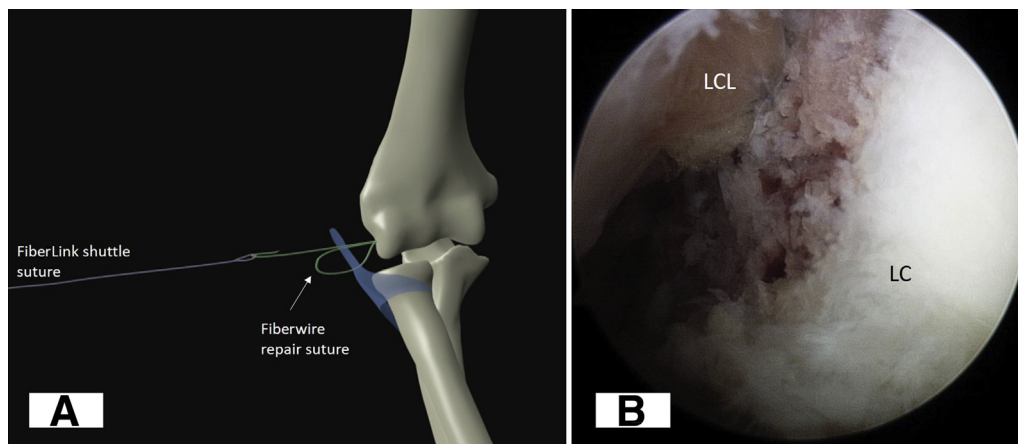


**Fig 3.** Arthroscopic lateral collateral ligament repair process, with the viewing portal through the soft spot portal. (A) The drill guide is placed through the direct lateral portal onto the isometric point of the lateral surface of the left lateral condyle. (B) The FiberWire repair suture is separated from the 2 strands of the FiberLink shuttling suture. (C) The FiberWire repair suture is shuttled through the lateral collateral ligament approximately 1 cm more distal (but through the same skin incision) using the QuickPass nitinol SutureLasso.

common extensor tendon and the LCL substance through the same lateral skin incision but approximately 10 mm distal to the already made portal to capture a sufficient amount of the LCL for the repair. Elevation of the subcutaneous tissue overlying this portal is necessary to allow for an adequate tissue bridge. The SutureLasso is then passed through the ligament, and the nitinol loop of the lasso is retrieved through the accessory posterolateral portal. The FiberWire repair suture from the anchor is also retrieved through the accessory posterolateral portal, and the suture

is passed through the nitinol loop. The nitinol loop is then withdrawn out of the direct lateral portal, thus shuttling the FiberWire suture through the LCL (Fig 3C).

The FiberWire suture is passed through the loop of the FiberLink shuttling suture. The nonlooped end of the FiberLink shuttling suture is then pulled, which shuttles the FiberWire repair suture through the SutureTak anchor (Fig 4A). The FiberWire repair suture is gently pulled, thus bringing the ligament to the lateral epicondyle. Because of the “finger-trap” locking mechanism within the suture, the



**Fig 4.** Tightening of suture repair. (A) The FiberWire repair suture is shuttled through the finger-trap mechanism of the SutureTak anchor using the FiberLink shuttling suture. (B) Arthroscopic view through the soft spot portal showing the left lateral collateral ligament (LCL) being tightened onto the lateral epicondyle. (LC, lateral condyle.)

repair can be securely tensioned, which can be visualized arthroscopically and further adjusted if necessary (Fig 4B). The radiocapitellar joint is then reassessed, and if the LCL is adequately repaired, the drive-through test should be absent and stability of the ulnohumeral joint restored.

### Rehabilitation

Postoperatively, the arm is placed in a posterior splint with the elbow flexed to 90° and the forearm pronated to 80° to maintain stability of the elbow and minimize tension on the LCL repair. At 2 weeks after surgery, the arm is placed into a resting thermoplastic posterior elbow shell in the same position. The patient is encouraged at this time to commence supine range-of-motion exercises with active-assisted extension of the elbow to 30°. Full flexion and rotation are permitted. After 6 weeks, the brace is removed and active range-of-motion exercises are commenced, with strengthening beginning at 12 weeks.

### Discussion

Several advantages exist for an arthroscopic approach to LCL repair. First, it allows for better visualization of the joint and the opportunity to address any associated

pathology, such as radial head fractures and osteochondral loose fragments. Second, after the repair, confirmation of restoration of elbow stability can be accurately assessed, with the ability to assess for the drive-through sign and congruity of the proximal radiocapitellar and ulnohumeral joints. Finally, arthroscopic repair allows smaller incisions, less dissection, and a potentially quicker rehabilitation.

In the particular case shown in Video 1, a single anchor was sufficient in restoring the ligament and stabilizing the elbow joint. However, in cases with more significant instability, 2 anchors could easily be placed to increase the footprint of the repair. One downside to our technique is the potential difficulty in determining the isometric point on the lateral condyle. We have found that a 70° arthroscope can be useful in obtaining a better appreciation of the dimensions of the lateral condyle before anchor insertion.

The risks of this method of repair are the standard risks of all elbow arthroscopic procedures (Table 1). They are mostly related to portal management and iatrogenic neurovascular injury. The direct lateral portal over the lateral epicondyle can cause further injury to the LCL

**Table 1.** Pearls and Pitfalls

#### Pearls

- Obtain adequate visualization of the posterior radiocapitellar joint.
- Ensure that the elbow can be reduced anatomically with flexion and forearm pronation; if not, examine the rest of the joint for incarcerated fragments.
- Adequately debride the scar tissue from the LCL footprint on the lateral epicondyle to promote ligament-to-bone healing.
- When passing the shuttling sutures, ensure careful suture management to prevent tangling.
- Make sure a sufficient tissue bridge of approximately 1 cm is obtained through the ligament.
- When tensioning the ligament repair, place the elbow in a reduced position (flexion and pronation), which can be visualized arthroscopically.

#### Pitfalls

- Poor visualization: The surgeon should spend the time to clear all hematomas and synovitis to visualize the lateral epicondyle and the proximal radioulnar joint.
- Elbow joint not reducible: There may be an incarcerated fragment within the joint that needs to be retrieved, or there may be a concomitant medial collateral ligament injury that needs to be addressed.
- Suture entanglement: Careful separation and placement of sutures are essential.
- Joint remains unstable after repair: An open lateral ligament repair may be necessary.

LCL, lateral collateral ligament.

**Table 2.** Advantages and Disadvantages

## Advantages

The technique is minimally invasive.

The technique allows intra-articular visualization and treatment of concomitant pathology (e.g., removal of loose bodies, arthroscopic internal fixation of radial head fracture, or assessment of chondral injury)

The surgeon has the ability to arthroscopically visualize the reduction of the elbow joint and assess stability after the ligament repair.

## Disadvantages

The technique is technically challenging.

The technique requires good integrity of the avulsed lateral collateral ligament. If the ligament is of poor quality and frayed, an open technique is recommended to allow multiple passes of the suture through the ligament.

complex and common extensor origin, so the skin incision and size of the portal should be kept to a minimum. It must be noted, however, that not all LCL tears are amenable to arthroscopic repair. Unlike in the open approach, if the humeral insertion of the LCL is frayed and of poor quality, repairing the common extensor origin insertion (which is intimately related superiorly) is usually sufficient in restoring elbow stability. Therefore, intraoperative assessment is necessary to determine the appropriateness of an arthroscopic ligament repair, and if not amenable, conversion to open repair or reconstruction may be required. Using the described technique, we believe that it is possible to successfully perform an all-arthroscopic repair of the LCL avulsion back to its anatomic humeral origin using knotless suture anchor fixation (Table 2).

### References

1. King GJ, Morrey BF, An KN. Stabilizers of the elbow. *J Shoulder Elbow Surg* 1993;2:165-174.
2. O'Driscoll SW, Bell DF, Morrey BF. Posterolateral rotatory instability of the elbow. *J Bone Joint Surg Am* 1991;73:440-446.
3. Morrey BF, Sanchez-Sotelo J. *The elbow and its disorders*. Amsterdam: Elsevier Health Sciences, 2009.
4. Nestor BJ, O'Driscoll SW, Morrey BF. Ligamentous reconstruction for posterolateral rotatory instability of the elbow. *J Bone Joint Surg Am* 1992;74:1235-1241.
5. Savoie FH III, O'Brien MJ, Field LD, Gurley DJ. Arthroscopic and open radial ulnohumeral ligament reconstruction for posterolateral rotatory instability of the elbow. *Clin Sports Med* 2010;29:611-618.
6. Daluiski A, Schrupf MA, Schreiber JJ, Nguyen JT, Hotchkiss RN. Direct repair for managing acute and chronic lateral ulnar collateral ligament disruptions. *J Hand Surg Am* 2014;39:1125-1129.
7. Dunning CE, Zarzour ZD, Patterson SD, Johnson JA, King GJ. Ligamentous stabilizers against posterolateral rotatory instability of the elbow. *J Bone Joint Surg Am* 2001;83:1823-1828.
8. Anakwenze OA, Kwon D, O'Donnell E, Levine WN, Ahmad CS. Surgical treatment of posterolateral rotatory instability of the elbow. *Arthroscopy* 2014;30:866-871.