

# Multidisciplinary Treatment of a Pediatric Orbital Roof Fracture: Case Report and Literature Review

Hanaa Shihadeh, BS\*  
Thomas D. Willson, MD\*†

**Summary:** Pediatric orbital roof fractures are a relatively rare trauma. In children, fractures of the facial skeleton can be associated with significant morbidity. Potential complications of orbital roof fracture include both neurosurgical complications such as frontal lobe injury, dural tears, or herniation, and ophthalmologic and reconstructive surgery problems such as proptosis, diplopia, and extraocular muscle entrapment. In most cases, surgical intervention is unnecessary, as these fractures are minimally displaced. When surgery is warranted, however, for displaced fractures or those associated with complications, a multidisciplinary approach is often indicated. Here, we report a case of a 10-year-old boy with a superiorly displaced orbital roof fracture resulting from a bicycle brake handle injury. The primary fragment was intracranially displaced and embedded in the inferior frontal lobe, causing frontal lobe herniation and left globe proptosis. A transcranial approach was performed using an autologous bone graft. In our case, a multidisciplinary surgical approach facilitated repair of both the dural and orbital injuries and multi-layer separation of the 2 spaces. (*Plast Reconstr Surg Glob Open* 2021;9:e3347; doi: [10.1097/GOX.0000000000003347](https://doi.org/10.1097/GOX.0000000000003347); Published online 22 January 2021.)

In the pediatric population, it is estimated that 1%–9% of all facial bone fractures involve the orbital roof.<sup>1,2</sup> Most pediatric orbital fractures are minimally displaced and require no surgical intervention (53%–93%); therefore, there is no specific consensus on the treatment of orbital fractures in this population.<sup>2–4</sup> In this report, we present a case of a 10-year-old boy who sustained a superiorly displaced orbital roof fracture that was embedded in the inferior frontal lobe, with resultant proptosis and frontal lobe herniation. The surgical repair was performed with the collaboration of plastic surgery, neurosurgery, and ophthalmology, highlighting the utility of a multidisciplinary approach for these injuries.

## CASE PRESENTATION

A 10-year-old boy presented after a bicycle accident during which his brake handlebar struck his left eye. His

examination revealed periorbital ecchymosis and proptosis of the left eye, with a complex laceration involving the left medial canthus. His globe was intact and uninjured. A computerized tomography scan demonstrated a comminuted fracture of the left superior orbital wall with a superiorly displaced fragment in the left frontal lobe, left frontal lobe herniation through the defect, and proptosis of the left globe with retrobulbar hematoma (Fig. 1).

A combined craniofacial approach for removal of the bone fragment from the frontal lobe and repair of the superior orbital roof was recommended because there was a clear dural injury and need for orbital decompression. A coronal incision allowed development of a pericranial flap between the temporal crests before the left frontal craniotomy (Fig. 2). A large fragment of the orbital roof was embedded in the frontal lobe along with several other smaller fragments. There were substantial dural tears that were not amenable to primary repair. The orbital roof defect was 1 × 4 cm; however, none of the bone fragments were sufficient to bridge the defect and prevent frontal lobe and periorbital tissue herniation. A 4 × 2 cm split calvarial bone graft was therefore taken from the inner table of the frontal craniotomy. The dural rents were patched with Duragen. The bone flap was placed and covered with the pericranial flap along the anterior fossa floor as far as possible, well beyond the edge of the fracture and the dural tears. The craniotomy bone flap was replaced, and

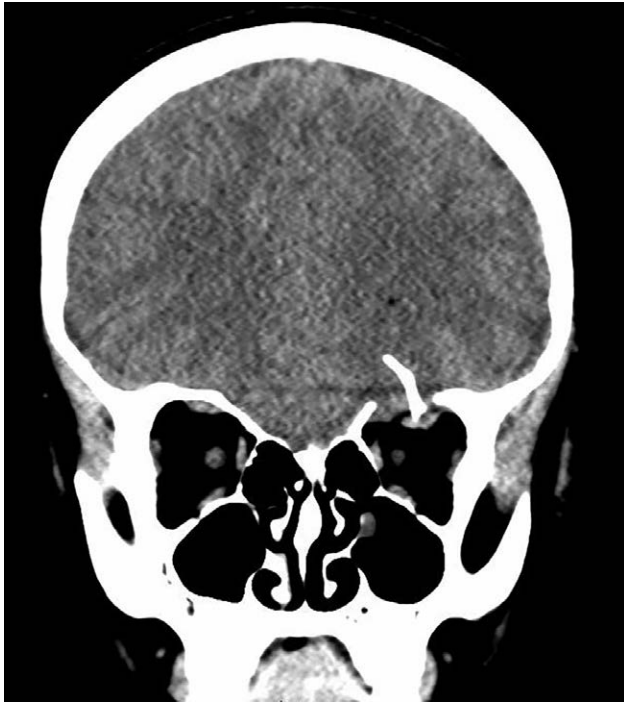
From the \*Larner College of Medicine at the University of Vermont; and †Departments of Surgery and Pediatrics, University of Vermont Medical Center.

Received for publication October 19, 2020; accepted November 13, 2020.

Copyright © 2021 The Authors. Published by Wolters Kluwer Health, Inc. on behalf of The American Society of Plastic Surgeons. This is an open-access article distributed under the terms of the [Creative Commons Attribution-Non Commercial-No Derivatives License 4.0 \(CCBY-NC-ND\)](https://creativecommons.org/licenses/by-nc-nd/4.0/), where it is permissible to download and share the work provided it is properly cited. The work cannot be changed in any way or used commercially without permission from the journal.

DOI: [10.1097/GOX.0000000000003347](https://doi.org/10.1097/GOX.0000000000003347)

**Disclosure:** The authors have no financial interest to declare in relation to the content of this article.



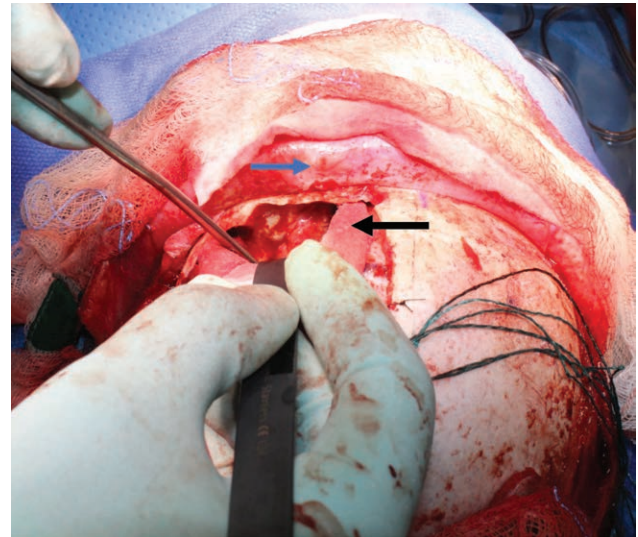
**Fig. 1.** Preoperative maxillofacial computerized tomography imaging.

the scalp closed. The patient recovered well, but has some restrictions in left globe movement due to the injuries to his extraocular muscles; he is scheduled for strabismus surgery (Fig. 3).

## DISCUSSION

Orbital roof injuries typically occur secondary to high-impact blunt craniofacial trauma.<sup>1</sup> Young children have a high cranium-to-face ratio of 8:1 compared with 2.5:1 in adults, which may serve to protect the midfacial skeleton but increases the risk of skull and orbital roof fractures.<sup>2</sup> Because of its location, significant concomitant neurologic and ophthalmic injury can occur with orbital roof injuries, which requires collaboration of several specialties to coordinate surgical management. Despite the high morbidity associated with these injuries, only limited data exist on multidisciplinary management, especially in the pediatric population.

Our case highlights the importance of early evaluation by a multidisciplinary team, as suggested by prior studies.<sup>5-8</sup> Cossman et al performed a retrospective review assessing the management of patients with traumatic orbital roof fractures. Of the 60 patients identified, 10% required surgical repair, all of which had a dural laceration and a CSF leak. The complexity of this type of trauma described in this study highlights the need for a multidisciplinary team to ensure sufficient care for these patients. The majority of patients (90%) in this study had minimal displacement with no evidence of a CSF leak and were therefore treated supportively with no complications.<sup>6</sup> Ha et al emphasized the importance of early

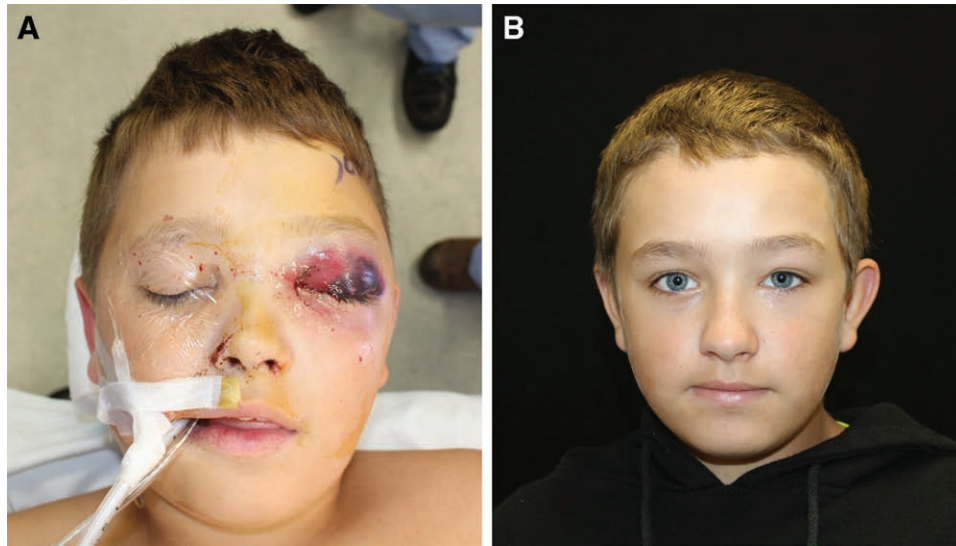


**Fig. 2.** Intraoperative image post-craniotomy. Pericranial flap is partially covered with moist sponge (blue arrow). The floor of anterior cranial fossa is visible (black arrow).

multidisciplinary evaluation and observation in their case series when patients with minimally displaced but comminuted orbital roof fractures later developed pulsatile exophthalmos and orbital meningoencephalocele, requiring surgery. They developed an algorithm to evaluate these patients, which begins with standard Advanced Trauma Life Support, followed by computerized tomography of the face, and consulting plastic surgery, neurosurgery, and ophthalmology. They suggest surgery if an orbital roof fracture is found to be displaced and there are signs of neurologic or ophthalmologic compromise. Admission and close monitoring is suggested for minimally displaced fractures.<sup>8</sup>

Early diagnosis and surgical intervention has been reported to decrease incidence of intracranial and ocular complications, and minimize postoperative morbidity and long-term sequelae in displaced orbital roof fractures.<sup>7</sup> Messinger et al. concluded if largely displaced fracture segments are not treated promptly, orbital encephalocele can occur.<sup>9</sup> Other benefits of early intervention include improved cosmetic and functional results, which decreases the need for secondary operations to correct eye motility, and decreased risk of infection, as described by Piotrowski and Beck-Mannagetta.<sup>5</sup>

Our patient underwent a transcranial approach to allow for adequate exposure because his injuries required debridement of the frontal lobe, and dural and orbital roof repairs. The vascularized pericranial flap was used to fill anatomical dead space, to provide a vascularized bed for the open areas of dura to scar onto, and to separate the dural patch from the orbital reconstruction. To reconstruct the roof, we used a calvarial bone graft because the available bone fragments from the fracture did not cover the defect and there was observed herniation of the periorbital. In addition, calvarial bone grafts in the pediatric age are known to be malleable, allowing better shaping of desired contour.<sup>10</sup>



**Fig. 3.** A 10-year-old boy presenting with an orbital roof fracture following a bicycle handlebar collision. A, Immediately before surgery. B, One year postoperative.

### CONCLUSIONS

We present a case of a successful multidisciplinary surgical approach for treating a 10-year-old boy with an orbital roof fracture caused by a collision with a bicycle handlebar. The orbital roof fracture was superiorly displaced into the inferior frontal lobe, with resultant frontal lobe herniation, and proptosis of the left globe. Due to its size, the defect in the orbital roof was repaired with the a split calvarial bone graft and pericranial flap. Our report highlights the importance of the use of a multidisciplinary team of plastic surgeons, neurosurgeons, and ophthalmologists to recognize and treat orbital roof fractures in the pediatric population.

**Hanaa Shihadeh, BS**

University of Vermont Medical Center

111 Colchester Ave

Burlington, VT, 05401

E-mail: [Hanaa.Shihadeh@med.uvm.edu](mailto:Hanaa.Shihadeh@med.uvm.edu)

### PATIENT CONSENT

*Parents or guardians provided written consent for the use of the patient's image.*

### REFERENCES

1. O-Lee TJ, Koltai PJ. Pediatric orbital roof fractures. *Oper Tech Otolaryngol Head Neck Surg.* 2008;19:98–107.
2. Haug RH, Van Sickels JE, Jenkins WS. Demographics and treatment options for orbital roof fractures. *Oral Surg Oral Med Oral Pathol Oral Radiol Endod.* 2002;93:238–246.
3. Jones AL, Jones KE. Orbital roof “blow-in” fracture: a case report and review. *J Radiol Case Rep.* 2009;3:25–30.
4. Moriwaki Y, Tomioka Y, Imai H, et al. Treating pulsatile exophthalmos in child with minimally invasive approach and custom-made titanium mesh plate. *Plast Reconstr Surg Glob Open.* 2019;7:E2070.
5. Piotrowski WP, Beck-Mannagetta J. Surgical techniques in orbital roof fractures: early treatment and results. *J Cranio-Maxillofac Surg.* 1995;23:6–11.
6. Cossman JP, Morrison CS, Taylor HO, et al. Traumatic orbital roof fractures: interdisciplinary evaluation and management. *Plast Reconstr Surg.* 2014;133:335e–343e.
7. Kim HK, Kim JW, Bae TH, et al. Early reconstruction of orbital roof fractures. *Arch Plast Surg.* 2012;39:31–35.
8. Ha A, Mangham W, Frommer S, et al. Interdisciplinary management of minimally displaced orbital roof fractures: delayed pulsatile exophthalmos and orbital encephalocele. *Cranio-Maxillofac Trauma Reconstr.* 2017;10:11–15.
9. Messinger AA, Radkowski MJ, Greenwald MM, et al. Orbital roof fractures in the pediatric population. *Plast Reconstr Surg.* 1989;84:217–218.
10. Agrawal A, Garg LN. Split calvarial bone graft for the reconstruction of skull defects. *J Surg Tech Case Rep.* 2011;3:13–16.