



# Perioperative Considerations in a Patient with Kleine–Levin Syndrome Undergoing a Neurosurgical Procedure under General Anesthesia

Wesley Rajaleelan<sup>1,2</sup> Tumul Chowdhury<sup>1,2</sup> Rebecca Moga<sup>1,2</sup> Carla Todaro<sup>1,2</sup> Gelareh Zadeh<sup>3</sup>  
Justin Wang<sup>3</sup> Mandeep Singh<sup>1,2,4</sup>

<sup>1</sup> Department of Anesthesia and Pain Management, University Health Network, University of Toronto, Toronto Western Hospital, Toronto, Ontario, Canada

<sup>2</sup> Department of Anesthesia and Pain Management, Women's College Hospital, Toronto, Ontario, Canada

<sup>3</sup> Department of Neurosurgery, University Health Network, University of Toronto, Toronto Western Hospital, Toronto, Ontario, Canada

<sup>4</sup> Toronto Sleep and Pulmonary Centre, Toronto, Ontario, Canada

Address for correspondence Mandeep Singh, MBBS, MD, MSc, FRCPC, Department of Anesthesia and Pain Management, University of Toronto, University Health Network, Toronto Western Hospital, 399 Bathurst St., MCL 2-405, Toronto, ON M5T 2S8, Canada (e-mail: mandeep.singh@uhn.ca).

AJNS 2022;17:480–484.

## Abstract

Kleine–Levin syndrome (KLS) is a rare central disorder of daytime hypersomnolence and is often characterized by a relapsing and remitting course, recurrent episodes of excessive sleep lasting from 12 to 20 hours a day, and symptoms including hyperphagia, hallucinations, derealization, disorientation, and hypersexuality. There are numerous perioperative considerations in dealing with KLS that include challenges during induction of anesthesia, delayed emergence, postoperative sleep disorders, and delirium. However, due to its rare occurrence, the anesthetic considerations of KLS remain poorly described. This case report outlines the anesthetic considerations and management of a young female patient with KLS who underwent transnasal excision of a trigeminal schwannoma under general anesthesia.

## Keywords

- ▶ Kleine–Levin syndrome
- ▶ narcolepsy
- ▶ sleep disorders

## Introduction

We present a 27-year-old female patient (weight 54 kgs, height 166 cm, body mass index 19.6 kg/m<sup>2</sup>) with a known history of Kleine–Levin syndrome (KLS) who underwent an endoscopic skull base surgery under general anesthesia.

## Preoperative Characteristics

The patient was diagnosed to have KLS based on frequent episodes of hypersomnolence alternating with insomnia (▶ **Table 1**). Her sleep evaluation and overnight polysomnography tests were within normal limits, with no evidence of

clinically significant sleep-related breathing or movement disorders. During the evaluation, the patient slept for 398 minutes with a sleep efficiency of 93.5%. The sleep onset latency was normal at 17.7 minutes and the rapid eye movement (REM) sleep onset latency was prolonged at 194.5 minutes. The apnea–hypopnea index was 0.9 events per hour, the minimum oxygen saturation was 90.3%, and 0% of total sleep time was spent at oxygen saturation levels below 90%. A multiple sleep latency test was performed the following day. The mean sleep onset latency was 3.0 minutes (severely reduced), and no sleep onset REM periods (SOREMPs) were observed, which implied that she did not have narcolepsy (▶ **Table 2**). She was started on lisdexamfetamine,

DOI <https://doi.org/10.1055/s-0042-1756624>.  
ISSN 2248-9614.

© 2022. Asian Congress of Neurological Surgeons. All rights reserved.

This is an open access article published by Thieme under the terms of the Creative Commons Attribution-NonDerivative-NonCommercial-License, permitting copying and reproduction so long as the original work is given appropriate credit. Contents may not be used for commercial purposes, or adapted, remixed, transformed or built upon. (<https://creativecommons.org/licenses/by-nc-nd/4.0/>)

Thieme Medical and Scientific Publishers Pvt. Ltd., A-12, 2nd Floor, Sector 2, Noida-201301 UP, India

**Table 1** Diagnostic criteria for Kleine–Levin Syndrome (Third International Classification of Sleep Disorders Diagnostic [ICSD-3]). Criteria A–E must be met

A	The patient experiences at least two recurrent episodes of excessive sleepiness of 2 days to 5 weeks duration.
B	Episodes recur usually more than once a year and at least once every 18 months.
C	The patient exhibits normal alertness, cognitive function, behavior, and moods between episodes.
D	The patient must demonstrate at least one of the following during episodes: altered perception, eating disorder, disinhibited behavior such as hypersexuality.
E	The patient must demonstrate at least one of the following during episodes: altered perception, eating disorder, disinhibited behavior such as hypersexuality.

counseled about regular sleep habits, and was maintained on regular follow-up with her sleep physician. She later presented with a 6-month duration of right-sided facial pain and numbness, migraine, and vertigo. A preoperative magnetic resonance imaging (MRI) was performed and it revealed a 6 × 5 × 5 cm<sup>3</sup> extra-axial mass (trigeminal schwannoma) centered in the right middle cranial fossa. The mass extended into the right cavernous sinus with mild compression of the temporal lobe anteriorly and indented the transverse sinus.

At the time of the preoperative anesthesia consult, her symptoms related to KLS had considerably decreased and she reported no daytime sleepiness. Her Epworth Sleepiness Score was 3. She denied recent exacerbations of hypersomnolence or symptoms of autonomic dysregulation (such as orthostatic presyncope, temperature dysregulation, or Raynaud’s symptoms). Her medications included lisdexamfetamine 30 mgs once daily, oxycodone 5 mgs as needed (rarely used), gabapentin 300 mgs twice daily, and mirtazapine 1.5 mgs in the evenings for anxiety. The patient reported recreational marijuana use in the remote past. She was advised to continue her stimulant medications until the day of surgery.

**Intraoperative Management**

General anesthesia was induced with fentanyl at a dose of 2 µg/kg, propofol at 2.5 mg/kg, and remifentanyl at 1 µg/kg.

Paralysis was achieved with rocuronium at a dose of 0.9 mg/kg. General anesthesia was maintained with a 50% air-oxygen mixture, a minimum alveolar concentration of sevoflurane at 0.8, and an infusion of remifentanyl at 0.25 µg/kg/min. The depth of anesthesia was monitored using Entropy and the target value was between 40 and 60. The intraoperative period was unremarkable. The mean arterial blood pressure was maintained within 20% of baseline and phenylephrine was administered as needed based on intra-arterial measurements. The procedure lasted 7 hours with an estimated blood loss of 600 mL, and the urine output was 600 mL. She was extubated when fully awake and could follow verbal commands. She had no evidence of residual neuromuscular blockade and we confirmed recovery with a train-of-four test that demonstrated four twitches and no fade.

**Surgical Technique**

Following orotracheal intubation, the patient was placed in a supine position in a headframe with stereotactic frameless navigation for intraoperative navigation. The tumor extended from the middle cranial fossa to the posterior maxillary wall and was accessed through an endonasal, endoscopic approach. It was resected almost completely but a small, thin layer of the tumor capsule that was attached to the cavernous carotid was left behind to avoid injury.

**Table 2** Details of diagnostic sleep study and the multiple sleep latency test (MSLT) report

	Nap 1	Nap 2	Nap 3	Nap 4	Average
Lights off	9:22 AM	11:15 AM	1:19 PM	3:17 PM	
Lights on	9:42 AM	11:34 AM	1:45 PM	3:37 PM	
Time in bed	20.2	18.9	25.6	20.2	21.2
Sleep time (min)	18.5	17.4	16.5	18.6	17.7
Sleep efficiency %	91.6	92	64.4	91.6	
Sleep latency (min)	1.1	0.5	8.7	1.7	3.0

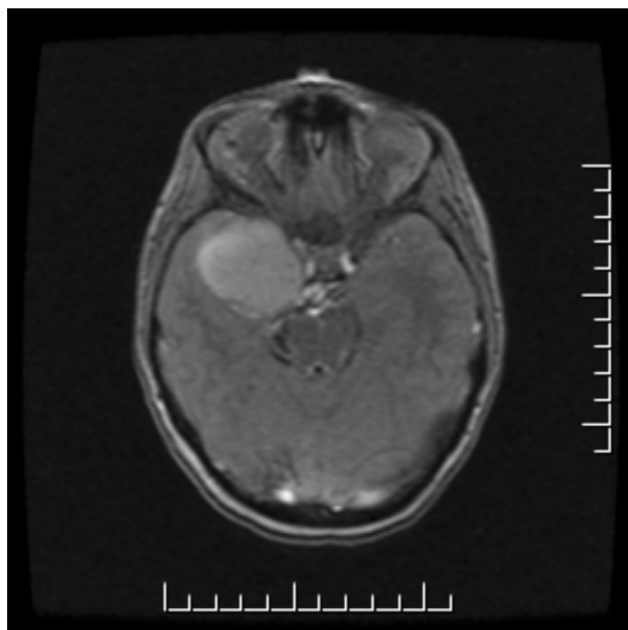
Lights out time—Time at the start of recording.  
 Lights on time—Time at the end of recording.  
 Total sleep time—Time spent Nap 1–3 and rapid eye movement (REM) sleep.  
 Total recording time (TRT)—Time from lights-out to lights-on (in minutes).  
 Total sleep time (TST)—Time spent in stage N1–3 and REM sleep.  
 Sleep efficiency %—TST/TRT × 100.  
 Sleep latency in minutes—Time from lights-out to first epoch of any sleep (in minutes).

## Postoperative Management

Following successful extubation, the patient was transferred to the postanesthesia care unit (PACU). Long-acting opioids were not prescribed. She was reassessed by the anesthesiology team before discharge from the recovery room to the ward. The ward staff were advised to cautiously monitor her for delayed hypersomnolence. The patient was advised to continue lisdexamfetamine in the postoperative period. She was assessed 4 weeks after the surgery and did not report any daytime sleepiness or worsening of KLS symptoms. She also did not report any awareness during the procedure. A repeat MRI did not indicate any tumor recurrence.

## Discussion

KLS is a rare disease of unknown origin.<sup>1,2</sup> It is characterized by a relapsing and remitting course, recurrent episodes of hypersomnia (with more than 18 hours of sleep a day), and episodes last from one to several weeks. It is associated with cognitive impairment, derealization, apathy, and behavioral changes. It occurs in adolescents, with a predominance in males, and is associated a history of birth or developmental problems<sup>3</sup> (►Fig. 1). The inter-episode periods last from one to several months, and are associated with normal sleep, mood, cognition, and behavior. Episodes might be triggered by infection, alcohol intake, or sleep deprivation, and usually



**Fig. 1** MRI brain demonstrates large extra-axial cystic and peripherally enhancing mass in the right middle cranial fossa, unchanged in morphology and size with stable degree of mass effect on the surrounding structures, and bony remodelling of the right maxillary sinus and sphenoid sinus. There was no hydrocephalus, midline shift, restricted diffusion or any other intracranial lesions. Peripherally enhancing cystic structure along the trajectory of the right trigeminal nerve most likely representing a cystic schwannoma with stable mass effect on the surrounding structures and chronic osseous remodelling of the maxillary and sphenoid sinuses. There was no involvement of the hypothalamus, or the third or fourth ventricle.

reduce in frequency and severity by middle age.<sup>1-3</sup> During an episode, the patient could exhibit excessive sleep, hallucinations, delusions, hyperphagia, derealization (a striking feeling of unreality), irritability, and hypersexuality<sup>3,4</sup> (►Table 3).

Our patient's overnight polysomnography report was normal with no sleep-related breathing disorders. However, her multiple sleep latency test demonstrated a severely reduced sleep onset latency, indicating severe daytime hypersomnolence. However, polysomnography studies are often difficult to interpret, and the results depend on the duration and the timing of the recording.<sup>4,5</sup> Twenty-four-hour polysomnograms in patients with KLS often demonstrate prolonged total sleep time of 12 to 14 hours a day, or 18 hours or more a day in severe cases. Other sleep-related breathing or movement disorders could be ruled out with an overnight polysomnogram. The results of the multiple sleep latency test depend on the subject's willingness to comply with the procedure and could be normal or abnormal. They could potentially demonstrate short sleep onset latency or multiple SOREMPs.<sup>4,5</sup>

Treatment of KLS generally involves behavioral interventions and supportive management. It is important to counsel the patient and family to let the patient sleep at home under supervision during episodes, to reduce anxiety, and to prevent possible embarrassing behavior in public. Driving or operating heavy machinery should be avoided, as sleepiness, automatic behavior, and altered perception could increase the risk of accidents during episodes.<sup>3-5</sup> Stimulants (modafinil, methylphenidate, amphetamine) might improve alertness, but have no effect on apathy, derealization, or cognitive symptoms.<sup>4,5</sup> Risperidone or anxiolytic medications could be used to treat psychosis and anxiety.<sup>4,5</sup> Gabapentin, valproate, and lithium have been used to prevent frequent or severe episodes, and to impede or halt the progression of the disease.<sup>5,6</sup> However, while using lithium, it is important to maintain its therapeutic concentrations between 0–8 and 1.2 mmol/L, to monitor for thyroid and renal insufficiency, and to maintain adequate hydration. Combinations of estrogen and progesterone have been used in patients with menstrual-related KLS to prevent episodes of hypersomnia and unwanted pregnancies.<sup>6,7</sup>

Preoperative recommendations for patients with KLS include assessment of symptom control, postponement of elective, nonurgent surgery during active episodes, sleep specialist referrals for uncontrolled symptoms, monitoring for potential drug–drug interactions, and counseling regarding specific medication use in the perioperative period.<sup>7,8</sup> A differential diagnosis of narcolepsy (cataplexy, sleep paralysis, hypnagogic hallucinations) should be ruled out.<sup>8-10</sup> It is important to assess for autonomic dysregulation associated with KLS and for potential drug interactions during the intraoperative period.<sup>11,12</sup> Autonomic dysfunctions such as headache, photophobia, phonophobia, temperature dysregulation, and orthostatic presyncope are common and require careful hemodynamic monitoring.<sup>13,14</sup> It is imperative that the stimulant medications used for the treatment of KLS are continued preoperatively until the day of surgery.<sup>15</sup>

**Table 3** Perioperative considerations of Kleine–Levin syndrome

Preoperative considerations	Intraoperative considerations	Postoperative considerations
<ol style="list-style-type: none"> <li>Elicitation of symptoms:                             <ul style="list-style-type: none"> <li>Hypersomnolence</li> <li>Recurrence of symptoms and symptomatic control</li> <li>Identify triggers: Viral infection, stress</li> </ul> </li> <li>Autonomic symptoms (headache, photophobia, orthostatic hypotension, hypertension, bradycardia, tachycardia, and ataxic or rapid ventilation)</li> <li>Consider postponing elective, nonurgent surgery during an elective episode of hypersomnolence</li> <li>Referral to sleep medicine specialist if uncontrolled symptoms or change in symptoms</li> <li>Counselling regarding specific medications                             <ul style="list-style-type: none"> <li>Stimulant medications should be continued</li> <li>Considerations for lithium including serum levels, and lithium toxicity</li> </ul> </li> </ol>	<ol style="list-style-type: none"> <li>Vigilance for intraoperative awareness or inadequate depth of anesthesia related to modafinil or stimulant use</li> <li>Vigilance for potential drug interactions                             <ul style="list-style-type: none"> <li>Amphetamines and ephedrine</li> <li>Methylphenidate and ketamine</li> <li>Modafinil may inhibit CYP450 enzymes (particularly CYP2C9)</li> <li>Valproate:</li> </ul> </li> <li>Vigilance for delayed emergence                             <ul style="list-style-type: none"> <li>Ensure patient is fully awake and all anesthetic and neuromuscular agents are reversed at time of extubation</li> </ul> </li> </ol>	<ol style="list-style-type: none"> <li>Close monitoring in the for-symptom exacerbation or over-sedation</li> <li>Limiting the use of medications with sedating effects when possible                             <ul style="list-style-type: none"> <li>Limit long-acting opioids</li> <li>Supplement with regional anesthesia when possible (opioid sparing effect)</li> <li>Optimize multimodal analgesic options</li> </ul> </li> <li>Counseling the patient regarding postanesthetic care prior to discharge</li> <li>Advising the patient and caregivers to monitor for exacerbation of symptoms and arrange a sleep physician follow-up following discharge, if worsened</li> </ol>

Specific intraoperative recommendations in KLS include the use of short-acting anesthetic agents and opioid medications in conjunction with regional anesthetic techniques. Neuraxial techniques could result in exaggerated hemodynamic changes due to autonomic dysregulation in patients with KLS. Monitoring the depth of anesthesia, especially with the use of total intravenous techniques, allows for judicious dosing of drugs.<sup>1,2</sup> Surgery for intracranial lesions might exacerbate KLS symptoms, especially hypersomnia. This is because hypersomnia has been associated with the dysfunction of the thalamus, hypothalamus, and forebrain. Lesions in the thalamus, hypothalamus, right prefrontal cortex, and right parieto-temporal junction have been associated with symptoms like KLS, such as apathy and derealization. Symptoms of primary disorders of hypersomnolence could overlap; hence, it is important to rule out symptoms of narcolepsy such as cataplexy, sleep paralysis, hypnagogic hallucinations, and daytime sleepiness.<sup>1,2</sup> Interestingly, new-onset narcolepsy has been reported in neurosurgical patients with lesions involving the third and fourth ventricles.<sup>10</sup>

Specific postoperative considerations related to KLS include (1) close monitoring in the PACU for symptom exacerbations, (2) limiting the use of sedative medications when possible, (3) optimizing multimodal analgesia, and (4) counseling the patient regarding postanesthetic care prior to discharge.<sup>3</sup>

### Conclusion

This is the first case report to focus on anesthetic considerations for patients with KLS undergoing neurosurgical procedures. Effective preoperative evaluation, continuation of preoperative medications, depth of anesthesia monitoring, use of multimodal analgesia with short-acting agents, and regional anesthetic techniques should be considered to deliver safe and uneventful anesthesia. Postoperatively patients should be counseled to watch for symptom recurrence, to continue medications, and to follow up with sleep medicine.

#### Author’s Contributions

WR collected data, drafted the article, and revised it critically for important intellectual content. TC and MD revised the article critically for important intellectual content. RM revised the article critically for important intellectual content. All authors read and approved the final manuscript.

#### Informed Consent

The patient provided written and informed consent for publication of this case report and the consent is available upon request.

#### Funding

Support was provided solely from institutional and/or departmental sources. MS is supported by the Canadian Anesthesiologists Society Career Scientist Award, as well

as the Merit Awards Program from the Department of Anesthesia at the University of Toronto.

#### Conflict of Interest

MS serves on the Medical Advisory Board of Hypersomnia Foundation (Atlanta, GA) at a voluntary basis. All the other authors report no conflict of interest.

#### References

- 1 Arnulf I. Kleine Levin Syndrome. In: Kryger M, Roth T, Dement W, eds. Principles and Practice of Sleep Medicine, 6th edition. Elsevier Inc.; 2016:96-97. e4
- 2 Rosenow F, Kotagal P, Cohen BH, Green C, Wyllie E. Multiple sleep latency test and polysomnography in diagnosing Kleine-Levin syndrome and periodic hypersomnia. *J Clin Neurophysiol* 2000; 17(05):519-522
- 3 Aflaki S, Hu S, Kamel RA, Chung F, Singh M. Case report of a patient with idiopathic hypersomnia and a family history of malignant hyperthermia undergoing general anesthesia: an overview of the anesthetic considerations. *A A Case Rep* 2017; 8(09):238-241
- 4 Itokawa K, Fukui M, Ninomiya M, et al. Gabapentin for Kleine-Levin syndrome. *Intern Med* 2009;48(13):1183-1185
- 5 Abe K. Lithium prophylaxis of periodic hypersomnia. *Br J Psychiatry* 1977;130:312-313
- 6 Severus WE, Kleindienst N, Seemüller F, Frangou S, Möller HJ, Greil W. What is the optimal serum lithium level in the long-term treatment of bipolar disorder—a review? *Bipolar Disord* 2008;10(02):231-237
- 7 McKnight RF, Adida M, Budge K, Stockton S, Goodwin GM, Geddes JR. Lithium toxicity profile: a systematic review and meta-analysis. *Lancet* 2012;379(9817):721-728
- 8 Kas A, Lavault S, Habert MO, Arnulf I. Feeling unreal: a functional imaging study in patients with Kleine-Levin syndrome. *Brain* 2014;137(Pt 7):2077-2087
- 9 Landtblom AM, Dige N, Schwerdt K, Säfström P, Granérus G. A case of Kleine-Levin syndrome examined with SPECT and neuropsychological testing. *Acta Neurol Scand* 2002;105(04):318-321
- 10 Arnulf I, Zeitzer JM, File J, Farber N, Mignot E. Kleine-Levin syndrome: a systematic review of 186 cases in the literature. *Brain* 2005;128(Pt 12):2763-2776
- 11 Khan Z, Trotti LM. Central disorders of hypersomnolence: focus on the narcolepsies and idiopathic hypersomnia. *Chest* 2015;148(01):262-273
- 12 Billiard M, Bassetti C, Dauvilliers Y, et al; EFNS Task Force. EFNS guidelines on management of narcolepsy. *Eur J Neurol* 2006;13(10):1035-1048
- 13 Fischer SP, Schmiesing CA, Guta CG, Brock-Utne JG. General anesthesia and chronic amphetamine use: should the drug be stopped preoperatively? *Anesth Analg* 2006;103(01):203-206
- 14 Hershner S, Dauvilliers Y, Chung F, et al. Knowledge gaps in the perioperative management of adults with narcolepsy: a call for further research. *Anesth Analg* 2019;129(01):204-211
- 15 Hu S, Singh M, Wong J, et al. Anesthetic management of narcolepsy patients during surgery: a systematic review. *Anesth Analg* 2018;126(01):233-246