

Heel Suturing on the Donor Vessel prior to Arteriotomy for End-to-side Cerebrovascular Anastomoses

Abstract

Microvascular anastomosis is a common procedure in cerebrovascular surgery. End-to-side anastomoses were the most common procedure for extracranial-to-intracranial bypass. Many techniques were used to reduce clamping time of the recipient vessel. The authors innovated heel suturing on the donor vessel prior to arteriotomy (HSDA) technique from the previously described double sutures on the toe and heel of the donor vessel before arteriotomy technique for end-to-side anastomosis. Forty-three end-to-side anastomoses using the HSDA technique were collected from 32 patients.

Keywords: Arteriotomy, bypass, cerebrovascular anastomosis, end-to-side anastomosis, heel suturing

Introduction

Microvascular anastomosis is a common procedure in cerebrovascular surgery, especially the end-to-side anastomosis which is performed for superficial temporal artery (STA)-middle cerebral artery bypass.^[1,2] Several techniques have been used to reduce the clamping time of the recipient vessel. The classic two-anchoring stitch technique, which prevents rotation of the donor on the recipient vessel, is widely used for end-to-side cerebrovascular anastomosis.^[1-4]

In general, for the two-anchoring stitch technique, the suturing on the heel and the toe sites of the donor vessel starts after the arteriotomy of the recipient vessel. These sutures, which can be performed before the clamping of the recipient artery for arteriotomy, may prolong the clamping time of the recipient vessel possibly causing ischemic complications.^[1,2]

The later developed technique of making double sutures on the toe and heel of the donor vessel before arteriotomy was first described by Ishishita *et al.*^[5-11] [Figure 1a and b]. After the double suturing on the donor vessel in the outside-in fashion is finished, clamping and arteriotomy are performed on the recipient vessel, then the

needles pierce both ends of the arteriotomy aperture in the inside-out direction. The advantage of this technique seems to be shorter clamping time of the recipient vessel.

The authors used the double-suture technique in seven cases (nine anastomoses). Because tangle of threads usually occurs, especially after arteriotomy [Figure 1c], we sometimes wasted time identifying the needle and its thread before making the first suture and tying the knot, especially in deep operative field. Hence, we modified the technique to make only one suture on the heel donor vessel before the arteriotomy, called the heel suturing on the donor vessel prior to arteriotomy (HSDA) technique [Figure 1d and e]. We made the suture on the heel donor vessel first because the heel site was more difficult to suture,^[12] and toe site suturing was easier and required less time. We describe and review our experience and evaluate the patency rate and safety of this technique. An illustrative case is also demonstrated.

Surgical technique

Heel suturing on the donor vessel prior to arteriotomy technique

After dissection and preparation of donor and recipient vessels by cleaning off their loose adventitial tissue, fishmouth

**Somkiat
Wongsuriyanan,
Kitiporn
Sriamornrattanakul**

Department of Surgery, Division of Neurosurgery, Faculty of Medicine Vajira Hospital, Navamindradhiraj University, Bangkok, Thailand

Address for correspondence:
Dr. Kitiporn Sriamornrattanakul,
Department of Surgery,
Division of Neurosurgery,
Faculty of Medicine Vajira
Hospital, Navamindradhiraj
University, Bangkok, Thailand.
E-mail: kitiporn6823@gmail.
com

Access this article online

Website: www.asianjns.org

DOI: 10.4103/ajns.AJNS_241_19

Quick Response Code:



This is an open access journal, and articles are distributed under the terms of the Creative Commons Attribution-NonCommercial-ShareAlike 4.0 License, which allows others to remix, tweak, and build upon the work non-commercially, as long as appropriate credit is given and the new creations are licensed under the identical terms.

For reprints contact: reprints@medknow.com

How to cite this article: Wongsuriyanan S, Sriamornrattanakul K. Heel suturing on the donor vessel prior to arteriotomy for end-to-side cerebrovascular anastomoses. *Asian J Neurosurg* 2020;15:230-5.

Submission: 29-07-2019 **Accepted:** 20-12-2019
Published: 25-02-2020

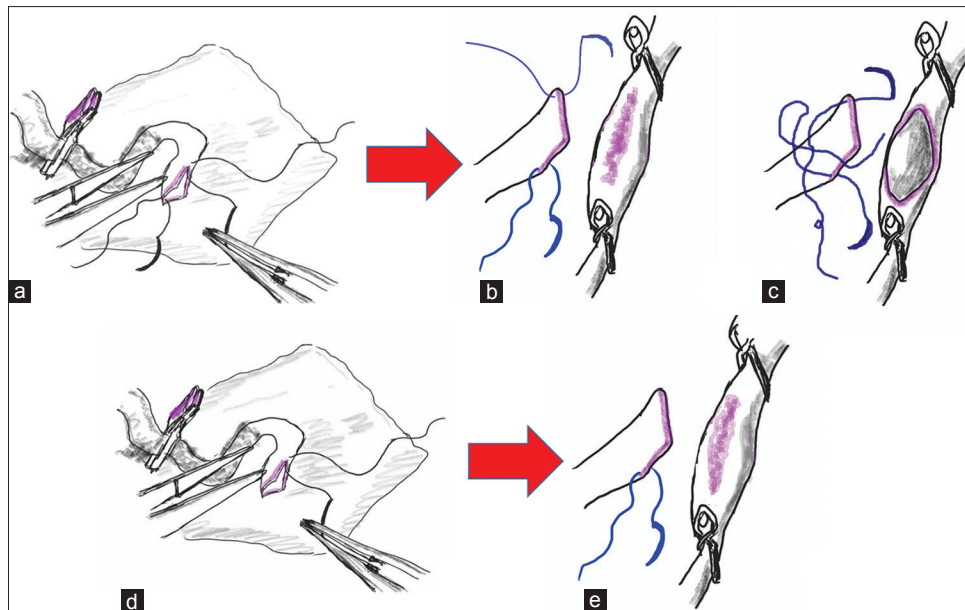


Figure 1: (a and b) The double sutures on the toe and heel of the donor vessel before arteriotomy. (c) After arteriotomy, both threads may tangled. (d and e) The heel suturing on the donor vessel prior to arteriotomy technique

trimming of the recipient artery was completed, as shown in Figures 2a, 3a and 4a. Gentian violet was used to color the edge of the trimming.^[1] A needle of nylon 10/0 or 11/0 was pierced at the heel of the donor vessel in outside-in direction [Figures 1d, 2a, b and 3b], and then the donor vessel with the suture was brought to the recipient artery. Gentian violet was used to color the anastomotic site of the recipient artery in the same length to the fish-mouthed donor's length.^[13] Two temporary clips were placed at the proximal and distal parts of the recipient artery, respectively [Figures 1e, 2c and e], and then arteriotomy was performed [Figures 2d, f and 3c]. Heparinized saline was irrigated into the arteriotomy opening to wash out blood from the lumen. The previous needle was pierced through the apex of the arteriotomy opening with inside-out direction [Figure 3d], and then the knot was tied. After the toe of the donor vessel was identified at the apex of the rhomboid [Figure 4], the needle was pierced through with outside-in direction and then pierced the other apex of the arteriotomy opening with inside-out fashion [Figure 3e], and the knot was tied. After the completion of both anchoring sutures [Figure 3f] and before the first side of the donor vessel suturing, the opposite side of the graft wall was inserted into the recipient lumen [Figure 5a and b] to prevent suturing the opposite wall of the recipient artery (through stitching).^[5] The first side of the graft wall was sutured to the recipient wall with the interrupted technique, and then the other side was sutured after flipping the donor vessel. The length of the suture bite and the interval between each stitch were two times the recipient wall thickness except the stitch next to the anchoring suture; the length of

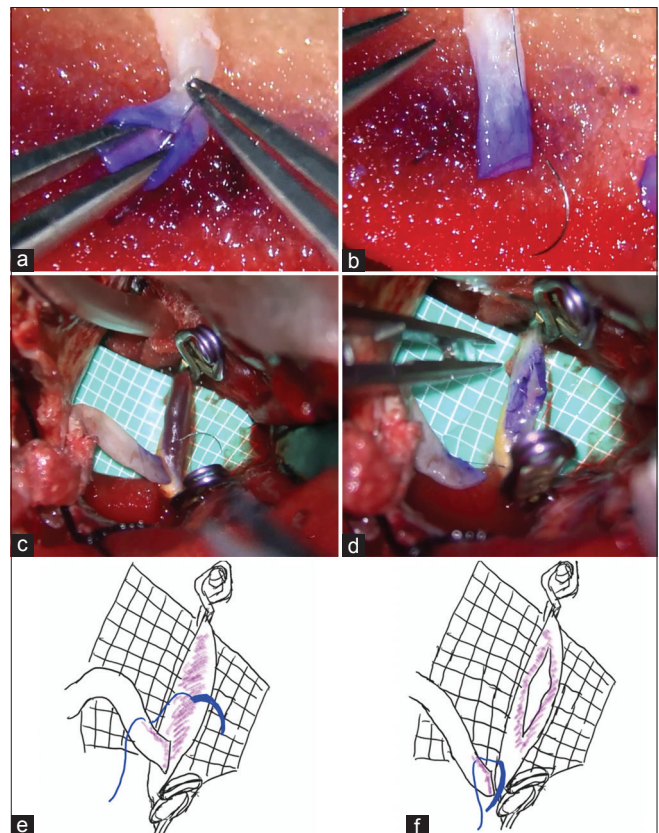


Figure 2: Photographs of the heel suturing on the donor vessel prior to the arteriotomy technique. (a) The technique for suturing the heel donor vessel. (b) After finishing the heel donor suturing. Operative field (c) before and (d) after arteriotomy. (e) Drawings of Figure 2c and (f) 2d

suture bite on the recipient side should be the same as the recipient wall thickness [Figure 5c]. For reliable patency of the anastomosis, the wall of the donor and

the recipient vessels need to be sutured in an everting pattern [Figure 5c], making both vessel walls attach to each other with the intima-to-intima architecture.^[14]

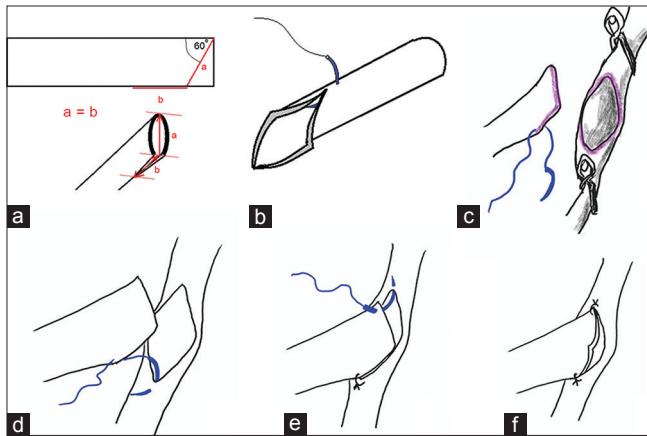


Figure 3: (a) Fishmouth trimming. (b) Suturing of the heel donor vessel with the outside-in direction. (c) The donor and recipient artery were prepared before the anastomosis began. (d) The first stitching to the recipient artery. (e) The toe stitching. (f) Two-anchoring sutures were completed

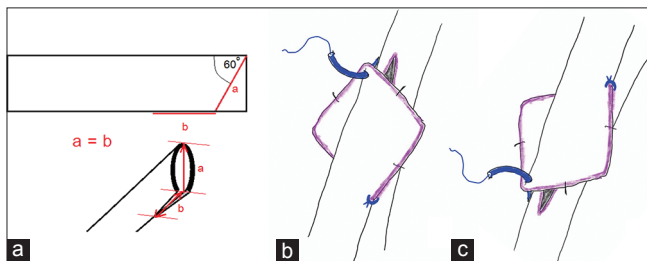


Figure 4: The method to identify the proper site for toe suturing. Because of fishmouth trimming (a), the end of the donor became a rhomboid. (b and c) After the heel stitching and tying were finished, the toe suturing was made at the apex of the rhomboid opposite to the heel with backhand (b) and forehand technique (c)

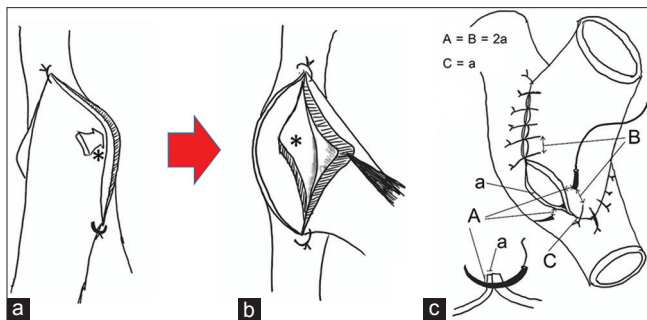


Figure 5: (a and b) To prevent the through stitch, after the completion of both anchoring sutures and before the first (left) side of the vessel suturing, the opposite (right) side of the graft wall (*) was inserted into the recipient lumen to prevent suturing the opposite wall of the recipient artery. (c) The length of the suture bite, the interval between each stitch and everting suture, were demonstrated

Case Report [Table 1]

Forty-three end-to-side anastomoses using the HSDA technique for low-flow bypass were collected from 32 patients. The indications for bypass surgery were the flow augmentation for chronic cerebrovascular insufficiency (16 anastomoses, 37.2%) and the flow preservation for cerebral aneurysm (27 anastomoses, 62.8%). STA and occipital artery (OA) were used in 33 (76.7%) and 10 (23.3%) anastomoses, respectively.

For all low-flow bypass cases, the mean occlusion times were 35.9 min, ranging from 25 to 55 min. The mean occlusion times for STA-graft bypass and OA-graft bypass were 34.2 and 41.7 min, respectively. Patency rates were 86%, 81.8%, and 100% for the overall low-flow bypass, STA-graft bypass, and OA-graft bypass, respectively. In cases of good patency of bypass graft, no ischemic symptoms in the recipient artery territory were detected after the operation.

Illustrative case

A 75-year-old female was diagnosed with ruptured atherosclerotic fusiform aneurysm of left vertebral artery (VA), from which left posterior inferior cerebellar artery (PICA) originates [Figure 6a-d]. The initial world federation of neurosurgical societies (WFNS) grade and Fisher's grade were 4 and 4, respectively. The left transcondylar fossa approach was performed with OA harvesting and V3 segment of left VA exposure. After posterior medullary segment of left PICA was prepared, OA-PICA anastomosis was performed in end-to-side fashion using the HSDA technique [Figure 7a-f]. The occlusion time was 41 min. After the bypass patency was confirmed using microdoppler and indocyanine green injection, double ligations of V3 segment of left VA and clip occlusion of PICA origin were completed. Postoperative computed tomography angiography showed good patency of bypass graft and complete obliteration of the aneurysm without any hypodensity area of the PICA territory [Figure 6e-h]. No new neurological deficit was detected in the postoperative course. The patient died of severe sepsis 1 month after the operation.

Discussion

Several techniques have been proposed to facilitate the end-to-side microvascular anastomosis. The classic two-anchoring stitch technique, which is the most widely used, prevents rotation of the donor on the recipient vessel. However,

Table 1: Type of bypass graft, number of anastomoses, outcomes and complications

Type of bypass	Number of anastomoses	Mean occlusion time (minutes)	Bypass patency rate (%)	Complications
Low-flow	43	35.9	86	0
STA graft	33	34.2	81.8	0
OA graft	10	41.7	100	0

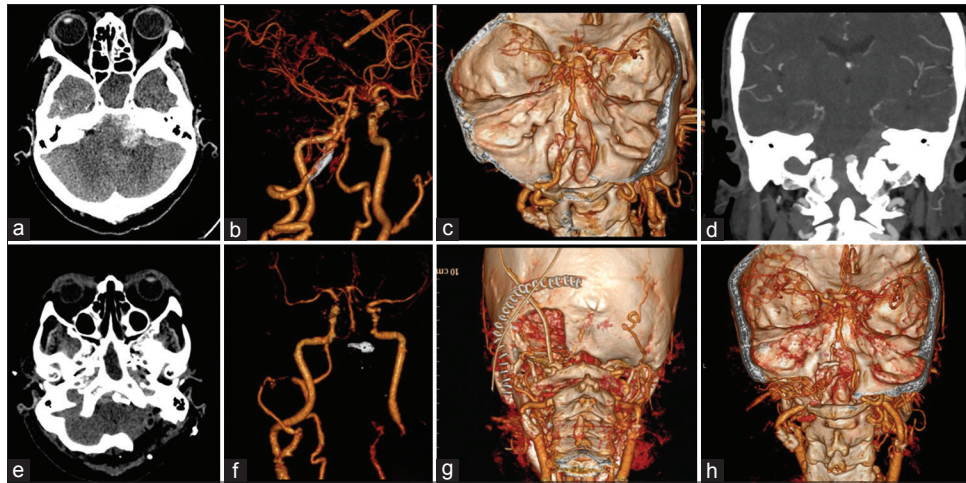


Figure 6: Illustrative case. (a-d) Preoperative computed tomography and computed tomography angiography revealed subarachnoid hemorrhage and atherosclerotic fusiform aneurysm of left vertebral artery from which left posterior inferior cerebellar artery originates. (e-h) Postoperative computed tomography and computed tomography angiography showed complete obliteration of the aneurysm and good patency of bypass graft

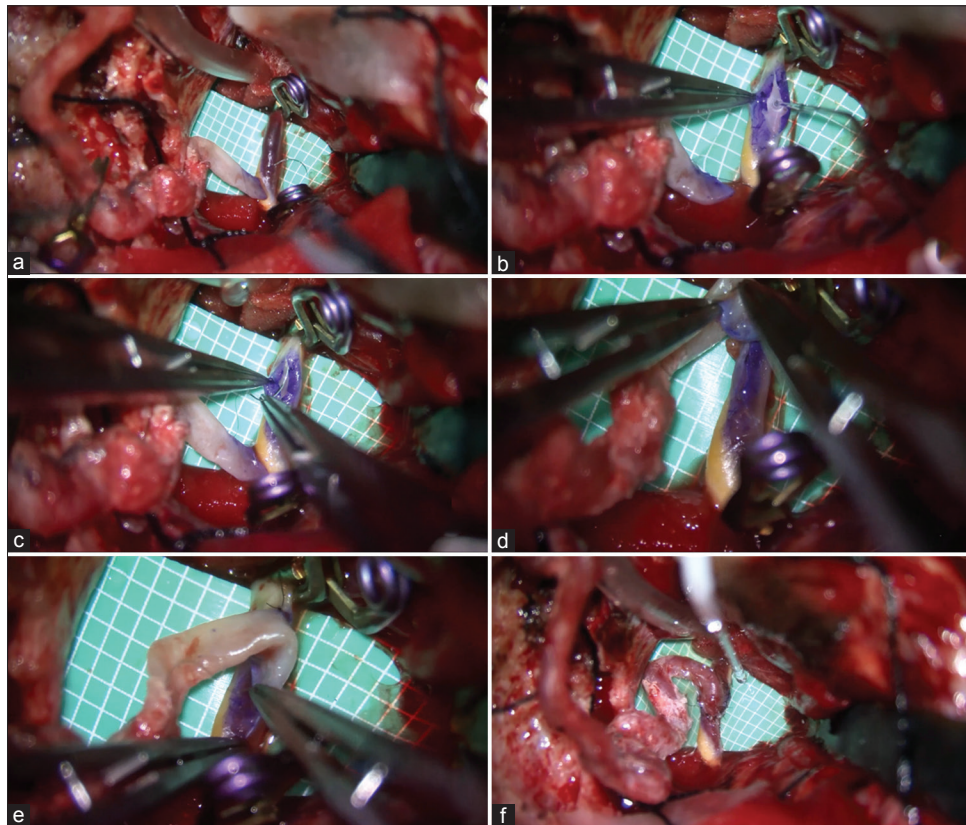


Figure 7: Intraoperative photographs of the occipital artery–posterior inferior cerebellar artery bypass of the illustrative case in sequence. (a) Heel donor vessel was sutured and recipient artery was clamped and prepared for arteriotomy. (b) After arteriotomy was completed. (c) One apex of the arteriotomy opening was sutured to the heel donor vessel. (d) Toe donor vessel was pierced in outside-in direction. (e) The other apex of the arteriotomy opening was sutured. (f) The end-to-side anastomosis was completed

it prevents visualization inside the lumen, which makes it highly likely to bite the back wall resulting in a through stitch.^[1,2]

In general, suturing on the heel and the toe sites was started after the arteriotomy of the recipient vessel. This suturing can be made before the clamping and arteriotomy of the recipient artery, which may prolong the clamping time.^[1,2]

The technique of making double sutures on the toe and heel of donor vessel before arteriotomy has been described by Ishishita *et al.* and seems to shorten clamping time of the recipient vessel.^[5-10] In our experience, the tangle of the two threads sometimes prolongs the clamping time. Therefore, we modified the

double suturing technique to the single one. Because the heel site of the anastomosis is the most difficult part of an end-to-side microvascular anastomosis,^[12] the heel suturing of the donor vessel was selected to be the first. The toe suturing of the donor vessel is not difficult to perform. After the fishmouth trimming, the donor vessel becomes a rhomboid shape. By identification of the apex of rhomboid, the toe suturing can be made at the correct site in the outside-in direction, and then the apex of the arteriotomy opening was sutured in the inside-out direction.

For the problem of the through stitch, many techniques have been proposed. Hegazy *et al.* concluded that the stitch at the 11 O'clock location is the most common site for a through stitch due to the surgeon's inability to see inside the lumen while putting in this one stitch and because of the proximity of both walls of the donor vessel to each other in this area.^[12] They presented a new technique that aims at starting the anastomosis with the stitch at the 11 O'clock position first, and in the meantime, allowing an opportunity to place all the other stitches in an inside-to-outside fashion on the donor vessel. After an arteriotomy of the recipient artery, a stent was placed inside to help keep the vessel patent and maintain good visualization inside the lumen while performing the anastomosis. Yazici *et al.* presented the triangulation method to decrease the risk of passing through sutures from the back wall by supporting the vessel ends to stay open in order to visualize and manipulate ostia of the vessel ends.^[15] Ishishita *et al.* and Katsuno *et al.* described a simple technique to prevent the through stitch. Before suturing the first side, the graft wall of the opposite side was inserted into the recipient lumen to prevent suturing the opposite wall of the recipient artery. We routinely used this technique for end-to-side anastomosis.^[5,16]

This study had several limitations: (1) the study was just a descriptive one which did not compare other techniques; therefore, we are unable to confirm the benefits of shortening the clamping time and (2) the occlusion time depended on many factors such as the size of vessel, number of stitches, the suturing technique (running or interrupted), depth of the operative field, and the experience of surgeons.

In this study, we did not include the high-flow bypass because the patency rate also depended on two anastomoses (the extracranial and intracranial anastomoses), which made it difficult to interpret the results.

Conclusion

The HSDA technique is safe and effective for end-to-side anastomoses. To the authors' knowledge, this is the first article that has described this technique.

Declaration of patient consent

The authors certify that they have obtained all appropriate patient consent forms. In the form the patient(s) has/have given his/her/their consent for his/her/their images and other clinical information to be reported in the journal. The patients understand that their names and initials will not be published and due efforts will be made to conceal their identity, but anonymity cannot be guaranteed.

Financial support and sponsorship

Nil.

Conflicts of interest

There are no conflicts of interest.

References

1. Wanebo JE, Zabramski JM, Spetzler RF. Superficial temporal artery-to-middle cerebral artery bypass grafting for cerebral revascularization. *Neurosurgery* 2004;55:395-8.
2. Charbel FT, Meglio G, Amin-Hanjani S. Superficial temporal artery-to-middle cerebral artery bypass. *Neurosurgery* 2005;56:186-90.
3. Bisson EF, Visioni AJ, Tranmer B, Horgan MA. External carotid artery to middle cerebral artery bypass with the saphenous vein graft. *Neurosurgery* 2008;62:134-8.
4. Ramanathan D, Temkin N, Kim LJ, Ghodke B, Sekhar LN. Cerebral bypasses for complex aneurysms and tumors: Long-term results and graft management strategies. *Neurosurgery* 2012;70:1442-57.
5. Ishishita Y, Tanikawa R, Noda K, Kubota H, Izumi N, Katsuno M, *et al.* Universal extracranial-intracranial graft bypass for large or giant internal carotid aneurysms: Techniques and results in 38 consecutive patients. *World Neurosurg* 2014;82:130-9.
6. Ota N, Tanikawa R, Tsuboi T, Noda K, Miyazaki T, Klinoshita Y, *et al.* Principle and tips for cerebral vascular reconstruction. *Surg Cereb Stroke* 2017;45:425-31.
7. Gandhi S, Mascitelli JR, Zhao X, Chen T, Hardesty DA, Wright EJ, *et al.* Two-stage revascularization and clip reconstruction of a giant ophthalmic artery aneurysm: 3-dimensional operative video. *Oper Neurosurg (Hagerstown)* 2019;17:E110-1.
8. Tayebi Meybodi A, Belykh EG, Aklinski J, Kaur P, Preul MC, Lawton MT. The End-to-Side Anastomosis: A Comparative Analysis of Arterial Models in the Rat. *World Neurosurg* 2018;119:e809-17.
9. Bot GM, Gandhi S, Tabani H, Burkhardt JK, Benet A, Lawton MT. Superficial Temporal Artery to Middle Cerebral Artery Bypass in a 1-Year-Old Moyamoya Patient: 2-Dimensional Operative Video. *Oper Neurosurg (Hagerstown)* 2018;15:E60.
10. Matano F, Tanikawa R, Kamiyama H, Ota N, Tsuboi T, Noda K, *et al.* Surgical Treatment of 127 Paraclinoid Aneurysms with Multifarious Strategy: Factors Related with Outcome. *World Neurosurg* 2016;85:169-76.
11. Sacak B, Tosun U, Egemen O, Sucu DO, Ozcelik IB, Ugurlu K. Two-suture fish-mouth end-to-side microvascular anastomosis with fibrin glue. *J Craniofac Surg* 2012;23:1120-4.
12. Hegazy A, Adel MF, Abd-Allah F, Al-Shamy H, Elbassiouny A, Amin SM, *et al.* The "11 O'clock Heel First" technique for microvascular end-to-side anastomosis. *Neurol India*

2017;65:69-72.

13. Kamiyama H, Takahashi A, Houkin K, Mabuchi S, Abe H. Visualization of the ostium of an arteriotomy in bypass surgery. *Neurosurgery* 1993;33:1109-10.
14. Kubota H, Tanikawa R, Katsuno M, Izumi N, Noda K, Ota N, *et al.* Vertebral artery-to-vertebral artery bypass with interposed radial artery or occipital artery grafts: Surgical technique and report of three cases. *World Neurosurg* 2014;81:202.e1-8.
15. Yazici I, Cavusoglu T, Comert A, Vural AC. Use of triangulation method in end-to-side arterial microvascular anastomosis. *J Craniofac Surg* 2009;20:2225.
16. Katsuno M, Tanikawa R, Izumi N, Hashimoto M. The preparation of anastomosis site at the insular segment of middle cerebral artery. *Surg Neurol Int* 2014;5:85.