

Management of radicular cyst in deciduous molar: A case report

Manjaree Talukdar¹, Abhinav Kumar², Shachi Goenka³, Monica Mahajani⁴,
Milind Prabhakar Ambhore³, Vivek Dilip Tattu³

¹Department of Pediatric Dentistry, Suncity Layout, JP Nagar, 7th Phase, Bengaluru, Karnataka, ²Departments of Oral and Maxillofacial Surgery, ³Conservative Dentistry and Endodontics, ⁴Periodontics, Dr. H.S.R.S.M Dental College and Hospital, Hingoli, Maharashtra, India

ABSTRACT

Radicular cysts associated with deciduous teeth are very rare. They constitute 0.5–3.3% of the total number of cysts in primary dentition. Radicular cysts involving deciduous teeth occur mostly in 3–19 years of age and has a male predominance. Enucleation with extensive removal of bone and vital teeth is preferred treatment for large radicular cysts and marsupialization can be preferred as a conservative approach to reduce morbidity. This paper presents a case report of a radicular cyst associated with a mandibular left deciduous first molar of a 7-year-old male child. The first premolar was displaced and the path of eruption was disturbed, horizontally placed below the first primary molar. The management comprised enucleation of the cystic sac and extraction of the involved permanent and primary teeth under general anesthesia.

Keywords: Enucleation, primary molar, radicular cyst

Introduction

Radicular cyst is the most common inflammatory odontogenic cyst originating from the epithelial remnants of periodontal ligament (epithelial cell rests of Malassez) following pulp necrosis.^[1] Radicular cysts are rare in the primary dentition, representing only 0.5–3.3% of the total number in both primary and permanent dentitions.^[2] Most of the radicular cysts are discovered when periapical radiographs are taken as they are asymptomatic. Radiographically, radicular cyst appears as a well-defined round or oval unilocular radiolucency with radiopaque sclerotic margin in the periapical region of involved tooth.^[3] A review of the literature shows the total cases reportable through 2004, to be about 112 and attributes 56% of them to be in response to pulp therapy.^[4]

Address for correspondence: Dr. Manjaree Talukdar,
Suncity Layout, JP Nagar, 7th Phase, Bengaluru, Karnataka, India.
E-mail: manjareetalukdar@gmail.com

Received: 13-12-2019

Revised: 13-01-2020

Accepted: 03-02-2020

Published: 28-02-2020

Cyst formation in children may cause bony expansion and resorption, delayed eruption, malposition, enamel defects, or damaging of the developing permanent successors. Complete enucleation of the cyst with extraction of the associated primary teeth and preservation of the permanent teeth is one among the foremost appropriate treatment choices for these cases. Even if the initial position of the permanent teeth are very unfavorable in most cases normal alignment of the teeth will occur spontaneously.^[5] Hence, the purpose of this article is to report a rare case of a radicular cyst associated with mandibular left first primary molar and its enucleation under general anesthesia.

Case Report

A 7-year-old male patient reported to the Department of Pedodontics with the chief complaint of swelling in the lower left back tooth region since 11 days. Past dental history revealed that swelling was initially small, which gradually increased to the present size. There was no history of pus discharge and ulceration

This is an open access journal, and articles are distributed under the terms of the Creative Commons Attribution-NonCommercial-ShareAlike 4.0 License, which allows others to remix, tweak, and build upon the work non-commercially, as long as appropriate credit is given and the new creations are licensed under the identical terms.

For reprints contact: reprints@medknow.com

How to cite this article: Talukdar M, Kumar A, Goenka S, Mahajani M, Ambhore MP, Tattu VD. Management of radicular cyst in deciduous molar: A case report. J Family Med Prim Care 2020;9:1222-5.

Access this article online

Quick Response Code:



Website:
www.jfmpc.com

DOI:
10.4103/jfmpc.jfmpc_1147_19

and the swelling was associated with pain, which was continuous, dull, and mild in nature. On extraoral examination, swelling was appreciable in lower left side of face [Figure 1] extending from corner of mouth to the body of the mandible, tenderness present over swelling region and raised temperature over that area.

Intraoral examination revealed grossly decayed left primary first molar with buccal cortical plate expansion [Figure 1]. Grade 1 mobility with respect to 31, 32, and Grade 2 mobility with respect to 33 was observed.

Orthopantomogram revealed radiolucency involving enamel, dentine, and approximating pulp in relation to 74 and deviation in the path of eruption of 34 [Figure 2a]. Periapical radiolucency of about 8 × 5 cm in dimension, involving both the mesial and distal roots of 74 along with a thin radiopaque border was noticed,

suggesting a cystic lesion. Radiolucency was clearly appreciated in CT scan views [Figure 2b, c].

On aspiration, there was blood mixed with fluid suggestive of infected radicular cyst [Figure 3a].

Clinical, radiographic examination, and excisional biopsy reports were suggestive of radicular cyst associated with mandibular left first primary molar. The histopathological examination confirmed the provisional diagnosis of a radicular cyst. It showed the presence of stratified squamous epithelium with sub-adjacent granular tissue and inflammatory infiltration. Considering the age of the patient and the size of the lesion, cyst enucleation was planned under general anesthesia.

Procedure

Consent was taken from the patient's parents and surgery was scheduled. The involved teeth were planned to be extracted during the procedure. General anesthesia was induced with nasal intubation. Local anesthetic agent lignocaine 2% with adrenaline (1:80000) was injected in the vestibular area with relation to 41,42,31,32,33,74,36.

Creviceular incision given from 31 to 36 and vertical releasing incision given distal to 31 and 36. Mucoperiosteal flap was raised and the surgical site was exposed. Now, with the help of round bur a window was created just below the apices of lower anterior teeth. Window size was slightly increased with the help of bone nibbler and cystic lining was seen [Figure 3b].

Cystic lining was separated from bone and removed completely. A decision was made to extract the primary molar and permanent tooth bud of first permanent premolar as it was involved in the cystic cavity. Irrigation was done with normal saline. Surgical site closed with help of 3.0 silk suture [Figure 3c].

Pressure dressing given extraorally over that area with help of dynaplast. Postoperative medication given and patient recalled after 7 days.

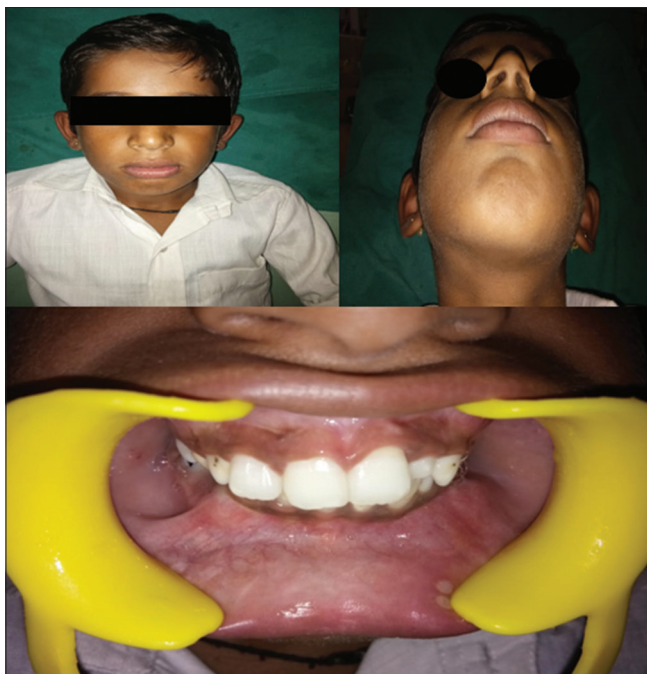

Figure 1: Extraoral view and Intraoral view showing vestibular obliteration

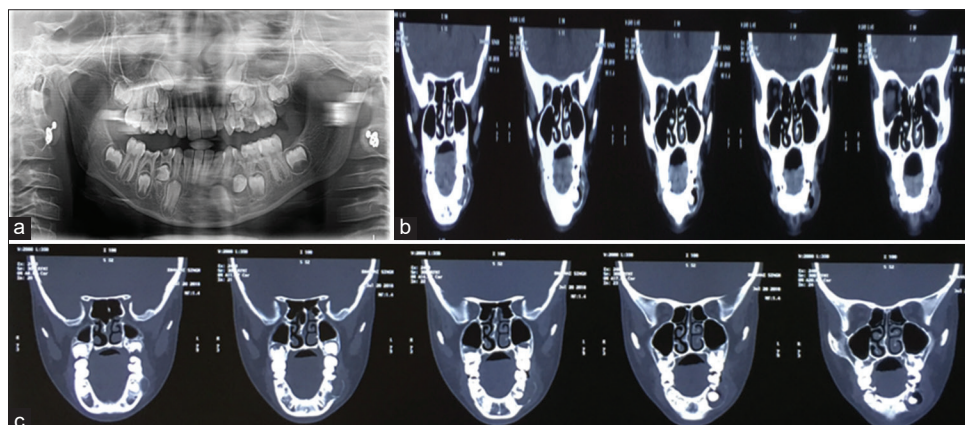


Figure 2: (a) OPG revealed grossly decayed left mandibular first primary molar. (b and c): CT scan views where the cystic cavity can be seen

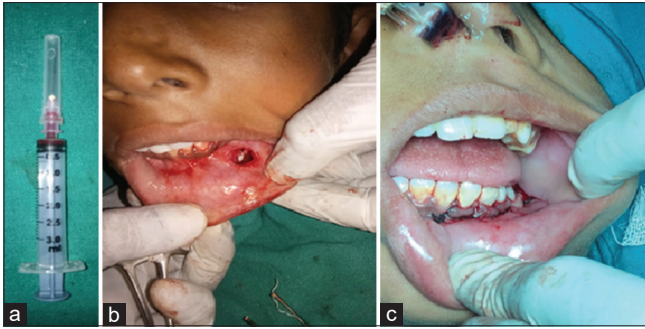

Figure 3: (a) Aspiration fluid. (b): Window created in the buccal cortical plate. (c): Postoperative photo showing closure of surgical site with sutures

Discussion

Radicular cysts originating from primary teeth are very rare and only a few cases have been published.^[6] Usually periapical radiolucencies related to primary teeth are neglected and in many cases they resolve after tooth extraction. Radicular cysts are mostly asymptomatic and are only discovered when periapical radiographs are taken. In primary teeth, pulp and inter-radicular infections have a tendency to drainage more than permanent teeth.^[5] This case was diagnosed as radicular cyst because of the presence of a large and painless radiolucent lesion in relation to the roots of a non-vital primary tooth, predominant mandibular buccal cortical plate expansion, and histological confirmation of cystic epithelial lining.

A series of radicular cysts associated with endodontically treated deciduous teeth with material containing formocresol which, in combination with tissue protein, is antigenic and has been shown to elicit a humoral and cell-mediated immune response was reported by Grundy, Adkins, and Savage.^[7] The present case reports a radicular cyst associated with primary molar which was non-endodontically treated.

Usually radicular cysts are unilocular similar to the one seen in this case. Radicular cysts arising from deciduous teeth may mimic dentigerous cyst radiographically, especially when they are multilocular.^[8] That possibility was ruled out in the present case as the lesion was associated with a grossly decayed non-vital primary molar.

Since, in the present case the first premolar was displaced, away from its normal path of eruption, with loss of its follicular space, it had high chance of being impacted; therefore, it was extracted^[9] in a similar case. Also, the tooth bud was in the cystic cavity in the present case. However, reported cases of normal alignment of the permanent teeth occurring spontaneously even though the initial positions were highly unfavorable.^[10]

Radicular cyst in deciduous dentition affects the mandibular teeth (as in this patient) because they are the ones most frequently affected by caries; in contrast, there is maxillary predominance in permanent dentition.^[11] Most authors agree that the treatment

of choice is enucleation of the cyst. Marsupialization is indicated when there is no likelihood of damaging anatomic structures and a more conservative intervention. The major disadvantage of the marsupialization technique is that pathologic tissue is left *in situ* without thorough histologic examination^[12] and multiple visits are required for regular washing of the cavity and follow-up. In the present case enucleation was preferred, because the pathologic cavity was not large and because we wanted to get histopathological confirmation of the diagnosis.^[1]

In children, healing of the postsurgical osseous defects is always good as they have high propensity for bone regeneration.^[6] In this case, we could not notice this because the child was from a distant place and the parents expressed their inability to visit the hospital for regular follow-ups.

Conclusion

More awareness campaigns especially at the primary healthcare centers in order to educate the population about the requirement for early presentation of the dento-alveolar pathologies are recommended. Early diagnosis followed by prompt treatment of any infection in the oral and maxillofacial region by the contemporary protocols in primary healthcare can help to impede the need for invasive surgical treatment and also to prevent the further complication in the jaw bone or in craniofacial region which causes major health problems to patient. To conclude, we present a rare case of radicular cyst associated with deciduous molars. For prevention of adverse effects to the underlying permanent successor teeth, recognition of the potential of radicular cysts in association with deciduous dentition is important.

Declaration of patient consent

The authors certify that they have obtained all appropriate patient consent forms. In the form the patient(s) has/have given his/her/their consent for his/her/their images and other clinical information to be reported in the journal. The patients understand that their names and initials will not be published and due efforts will be made to conceal their identity, but anonymity cannot be guaranteed.

Financial support and sponsorship

Nil.

Conflict of interest

There is no conflict of interest.

References

1. Sevekar S, Subhadra H N, Das V. Radicular cyst associated with primary molar: Surgical intervention and space management. *Indian J Dent Res* 2018;29:836-9.
2. Bhaskar SN. Periapical lesions - types, incidence and clinical features. *Oral Surg Oral Med Oral Pathol* 1966;21:657-72.
3. Mahesh BS, Shastry SP, Murthy SP, Jyotsna TR. Role of cone

- beam computed tomography in evaluation of radicular cyst mimicking dentigerous cyst in a 7-year-old child: A case report and literature review. *Int J Clin Pediatr Dent* 2017;10:213-16.
4. Shivanna V. Bilateral radicular cyst in primary maxillary molars: A case report. *Int J Med Dent Case Rep* 2017;4:1-3.
 5. Toomarian L, Moshref M, Mirkarimi M, Lotfi A, Beheshti M. Radicular cyst associated with a primary first molar: A case report. *J Dent* 2011;8:213-17.
 6. Uloopi KS, Shivaji RU, Vinay C, Pavitra, Shrutha SP, Chandrasekhar R. Conservative management of large radicular cysts associated with non-vital primary teeth: A case series and literature review. *J Indian Soc Pedod Prev Dent* 2015;33:53-6.
 7. Grundy RM, Adkins KF, Savage NW. Cysts associated with deciduous molars following pulp therapy. *Aust Dent J* 1984;29:249-56.
 8. Koju S, Chaurasia NK, Marla V, Niroula D, Poudel P. Radicular cyst of the anterior maxilla: An insight into the most common inflammatory cyst of the jaws. *J Dent Res Rev* 2019;6:26-9.
 9. Bhatt SS, Vidhya M, Sargod S. Radicular cyst associated with endodontically treated deciduous tooth: A case report. *J Indian Soc Pedo Prev Dent* 2003;21:139-41.
 10. Chiu WK, Sham AS, Hung JN. Spontaneous alignment of permanent successors after enucleation of odontogenic cysts associated with primary teeth. *Br J Oral Maxillofac Surg* 2008;46:42-5.
 11. Nilesh K, Dadhich AS, Chandrappa PR. Unusually large radicular cysts of maxilla: Steps in diagnosis and review of management. *J Biol Innov* 2015;4:1-11.
 12. Prakash R, Shyamala K, Girish HC, Murgod S, Singh S, Rani PV. Comparison of components of odontogenic cyst fluids: A review. *J Med Radiol Pathol Surg* 2016;2:15-7.