



Received: 2015.02.15
Accepted: 2015.03.26
Published: 2015.06.19

Authors' Contribution:

- A** Study Design
- B** Data Collection
- C** Statistical Analysis
- D** Data Interpretation
- E** Manuscript Preparation
- F** Literature Search
- G** Funds Collection

Complementary Value of Sonography in Early Evaluation of Necrotizing Enterocolitis

Karmella Kamali^{ABEF}, Say'yed Reza Hosseini^{ADEF},
Say'yed Mostajab Razavi Nedjad Ardakani^{ACEF}, Mohammad Reza Farnoodi^{ABDE}

Medical Imaging Center, Nemazee Hospital, Shiraz University of Medical Sciences, Shiraz, Iran

Author's address: Say'yed Reza Hosseini, Department of Radiology, Nemazee Hospital, Shiraz, Iran,
e-mail: rezagaibi@yahoo.com

Background:

Despite the widespread use of plain films to detect necrotizing enterocolitis (NEC), it is considered a time-consuming method, which exposes patients to radiation. We aimed to assess changes in ultrasonographic variables and to compare sonography and chest radiography in detecting early stages of NEC in suspected premature infants.

Material/Methods:

This case-control study was carried out in the years 2012–2013. We enrolled 67 premature neonates using a simple sampling method and divided them into the study and control groups. All patients underwent plain abdominal radiography, gray-scale and color Doppler sonography.

Results:

34 and 33 neonates were assigned to the study and control groups. No significant gender differences were found between the two groups ($P=0.549$). The mean bowel wall thickness ranged from 1.2 to 3.2 mm in the control group (132 abdominal quadrants) and 1–3.3 mm in the study group (136 abdominal quadrants, $P=0.502$). Intra-mural echogenic dots were seen in one neonate in the study group in favour of pneumatosis intestinalis. The mean \pm SD bowel wall perfusion in the study and control groups were 3.117 ± 0.975 and 2.878 ± 0.538 dots or lines/cm², respectively ($P=0.218$). One neonate in the study group showed internal echoes within the mild amount of free fluid. Twelve neonates in the control group had minimal amounts of intra-abdominal free fluid.

Conclusions:

The two groups differed regarding bowel wall thickness, echogenicity, and perfusion in sonography and color Doppler evaluation. Although those differences were not statistically significant, considering the time-consuming nature of abdominal X-ray, the use of sonography and color Doppler can improve diagnosis and treatment of NEC as a triage method.

MeSH Keywords:

Enterocolitis, Necrotizing • Radiography, Abdominal • Ultrasonography, Doppler, ColorL

PDF file:

<http://www.polradiol.com/abstract/index/idArt/893876>

Background

Necrotizing Enterocolitis (NEC) is one of the most common acute gastrointestinal and abdominal emergencies in neonates. As many as 1–5% of neonates, admitted to neonatal ICUs are affected by this disease and 10% of neonates with birth weight lower than 1500 g may present signs and symptoms attributable to such a disease [1]. Its incidence rate has a reverse correlation with gestational age at birth [2,3]. Neonates with gestational age of less than 28 weeks and very low birth weight (especially less than 1000 g) are more prone to this disease [4]. However, 10% of the patients with NEC are term neonates [5]. Risk factors of the disease

in term neonates include: congenital heart diseases, pre-natal asphyxia, patent ductus arteriosus (PDA) and indomethacin therapy [6]. Although NEC usually occurs during the first 2 weeks of birth, it can be delayed for 3 weeks or later in very premature neonates [7].

Due to non-specific clinical signs and symptoms which resemble neonatal sepsis in many cases, diagnosis of the NEC is very difficult. Although the pathogenesis of NEC is not definitely known, several factors including intestinal trauma and damage caused by sepsis and intestinal ischemia along with colonization of various bacteria can initiate and induce the disease [8]. There is a significantly

high incidence rate of NEC (up to 50%) in neonates with sepsis or septic shock, who are admitted to neonatal ICUs [9].

Early diagnosis and management of NEC is critical and life-saving, because bowel perforations occur in 12–31% of patients with delayed treatment. The mortality rate of this disease varies from 20% to 40% [1]. The most important radiologic findings of plain abdominal radiography to confirm diagnosis of NEC are pneumatosis intestinalis (air in the bowel wall) and pneumoperitoneum (intra-abdominal free air) [10].

Currently, modified Bell's staging criteria (a combination of clinical signs and symptoms, laboratory findings, and plain abdominal X-ray) are used as the diagnostic criteria [11].

Bowel ultrasonography provides an opportunity for evaluating bowel dynamics as well as free intra-abdominal fluid. Many studies have emphasized on higher diagnostic accuracy of gray-scale and Doppler ultrasonography over plain abdominal radiography for detection of some bowel wall changes, especially those which occurred in bowel wall thickness, echogenicity, and perfusion as well as portal venous gas and focal or free intra-abdominal fluid [10,12–18].

In this study, we aimed to evaluate the abdominal and bowel wall (bowel wall thickness, echogenicity, and perfusion) ultrasonographically in premature infants with no definitely diagnosed NEC who were only suspected to have the disease (Stage IA and IB). We aimed to determine whether any significant changes in the mentioned ultrasonographic variables could be observed in such patients in comparison with the control group.

Material and Methods

This case-control study was carried out between June 2012 and April 2013. We enrolled 67 premature neonates (with gestational age of <37 weeks) who were admitted to neonatal intensive care units (NICUs) of Hazrat-e-Zeynab, Hafez, and Namazee hospitals affiliated to Shiraz University of Medical Sciences, Shiraz, Iran.

The participants were recruited using the simple-sampling method. Initially, the neonates were classified into study and control groups and inclusion criteria were specified for each group. The sample size was calculated to be 33 neonates in each group by the statistician who observed the study.

The control group consisted of 33 premature neonates (19 boys and 14 girls) with a mean gestational age of 30.315 weeks (range: 26–35 weeks) who had no clinical, laboratory, or radiological evidence of NEC (as defined by the modified Bell's staging criteria), or any acute systemic, congenital or acquired gastrointestinal disease (such as bowel and abdominal wall defects). Clinical examinations by a neonatologist accompanied by paraclinical evidence confirmed that group's suitable clinical condition and the stability of the neonates' vital signs.

A total of 34 premature neonates (22 boys and 12 girls) with a mean gestational age of 30.029 weeks (ranging from 24 to 35 weeks) were enrolled in the study group. They were in stage I of NEC (suspected to NEC) based on the modified Bell's staging criteria and the diagnosis of a neonatologist. The modified Bell's staging criteria are a diagnostic tool which provides the possibility to diagnose NEC using a combination of clinical signs and symptoms, paraclinical findings, and radiological evidence [11]. They had no radiological, clinical or laboratory evidence of definite NEC including pneumatosis intestinalis (air in the bowel wall) and pneumoperitoneum (intra-abdominal free air), portal venous gas, absence of bowel sounds, thrombocytopenia, neutropenia, metabolic acidosis, or disseminated intravascular coagulation (DIC) to confirm definite diagnosis of the disease.

Exclusion criteria were the presence of the mentioned laboratory or radiological findings in the neonates or the absence of bowel sounds after being examined by a neonatologist. Patients with congenital abnormalities of abdominal or bowel wall, presence of excessive intestinal gas, or hemodynamic instability, were excluded from the study as well.

Initially, all the neonates were examined clinically by a neonatologist and those with temperature instability, lethargy, apnea, bradycardia, abdominal distention, nausea and vomiting, gastric retention, heme-positive stool, and food intolerance were considered as "suspected" to NEC and underwent plain abdominal radiography. The films were examined by a radiologist accurately and comprehensively. The considered radiographic findings included: pneumatosis intestinalis, pneumoperitoneum, and ascites. When establishing that the evaluated neonates who were suspected to have NEC lacked aforementioned radiological findings, we enrolled them in the study group as the patients suspected to have stage I of the disease and they underwent further ultrasonographic assessments.

Demographic characteristics and the laboratory evidence as well as clinical and ultrasonographic findings of all neonates (n=67) were recorded separately in special data collection forms. Ultrasonographic assessments were carried out in the neonates after obtaining informed consent from their parents and informing them about assessment processes as well as aims and methods of performing abdominal ultrasonography.

All patients underwent plain abdominal radiography in a supine position with an anteroposterior direction of the X-ray beam. The films were examined by a radiologist who was experienced in pediatric radiology. The radiographic images were evaluated to detect the presence of pneumatosis intestinalis, pneumoperitoneum, portal venous gas, and ascites.

Both the gray-scale and color Doppler sonography were performed in control and study groups by a senior radiology resident under supervision of a radiologist who was experienced in pediatric ultrasonography. A Mindray M7 Sonography System (Shenzhen Mindray Bio-Medical Electronics) was used for sonographic scans and abdominal

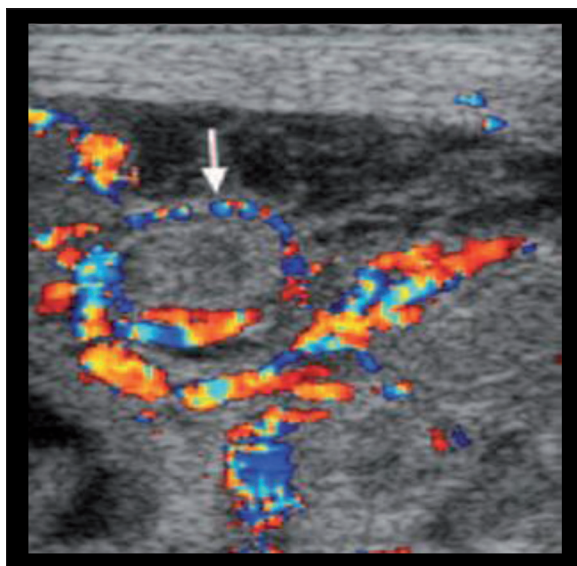


Figure 1. Ring pattern.

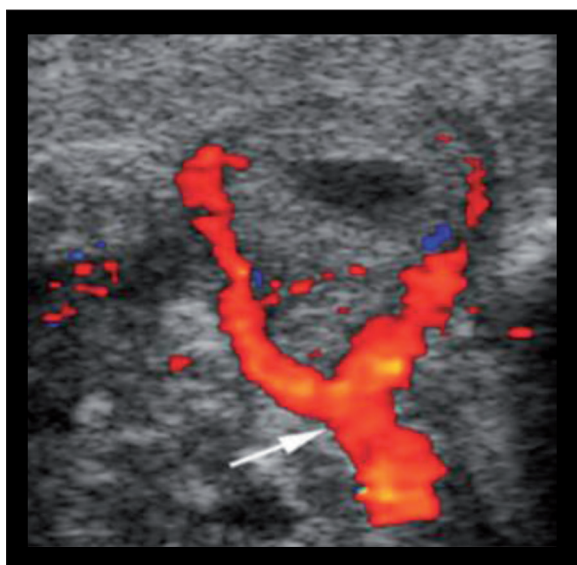


Figure 2. Y-pattern.

sonography was performed in 4 quadrants of the abdomen, using 3.5-MHz curvilinear (C5-2s) and 8.25-MHz phased-array (P12-4s) probes. The examined variables included: bowel wall thickness, echogenicity and perfusion, portal venous gas, and intra-abdominal free fluid (echoic or non-echoic). If any free fluid is observed in the abdominal cavity, its nature should be examined (free fluid, free fluid with internal echoes, localized accumulation of fluid). Bowel wall thickness between 1 and 3 millimeters was considered normal. Values less than 1 mm or more than 3 mm were considered as thinning or thickening of the bowel wall, respectively. Bowel wall echogenicity was considered normal when homogeneous hypoechoic halo was seen, surrounding intra-luminal gas. Bowel wall perfusion was measured by counting the number of colored dots or lines in 1 cm² of a scanned bowel wall. Measurements were performed in all four quadrants of the abdominal cavity. Based on the previous studies, 1 to 9 colored dots or lines/cm² were considered normal. The presence of

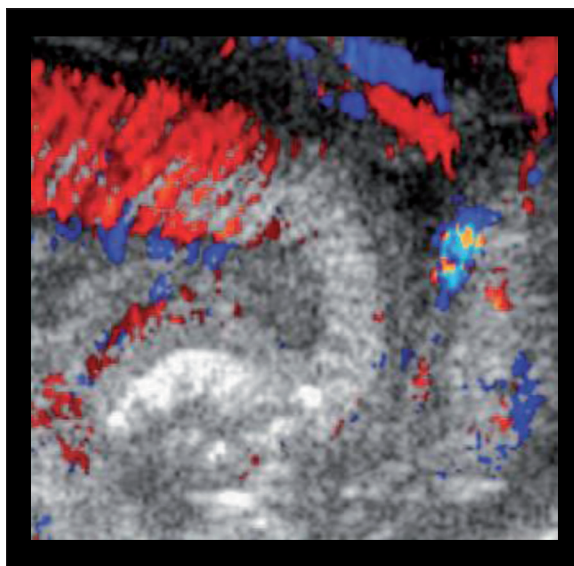


Figure 3. Zebra pattern.

specific color Doppler patterns, including a complete ring of color, Y-shaped pattern or Zebra pattern, were indicative of increased bowel wall perfusion (Figures 1–3). The lack of color Doppler signals was considered as bowel wall necrosis.

A sample size of 33 patients was calculated for each group ($\alpha=40\%$, 85%, and 0.05, power: 0.09) based on the results of similar studies. SPSS software version 15 was used for statistical analysis. Kolmogorov-Smirnov Test (K.S.Test) was applied to confirm a normal value of quantitative variables. Quantitative variables were compared between the study and control groups, using parametric tests (t-test). Then, the results were presented as Mean \pm standard deviation (SD) and P value with 95% confidence interval (CI). Comparison of categorical variables was performed between both groups using Chi-square and Fisher's exact tests, and the results were presented as frequency, percentage and P value.

Results

A total of 67 pre-term neonates were included in the study; 34 in the study and 33 in the control group. A total of 22 (64.7%) neonates in the study group and 19 (57.6%) in the control group were male. Twelve (35.3%) and 14 (42.4%) neonates in the study and in the control groups were female, respectively. The mean \pm SD gestational ages of the neonates in the study and control groups were 30.029 \pm 2.491 and 30.315 \pm 2.467 weeks, respectively ($P=0.638$).

There was no significant difference between the two groups regarding the sex ratio ($P=0.549$). The mean \pm SD birth weights of the neonates in the study and control groups were 1176.746 \pm 99.139 and 1216.969 \pm 115.284 grams, respectively ($P=0.130$).

Of the total 34 neonates in the study group, 32 (94%) were considered to be at stage IA, and 2 neonates (6%) at stage IB of the disease (Stage IB: grossly bloody stool).

Table 1. Comparison between study and control groups in terms of bowel wall thickness.

Groups	Number of neonates	Mean thickness	SD	P value
Control	33	609.1	303.0	502.0
Cases	34	672.1	437.0	

Table 2. Frequency (%) in terms of bowel wall thickness in the two studied groups.

Variable	Group		P value
	Controls	Cases	
Increased bowel wall thickness	1 (3.0)	3 (8.8)	0.613
Normal bowel wall thickness	32 (97.0)	31 (2.91)	
Total	33 (100.0)	34 (100.0)	

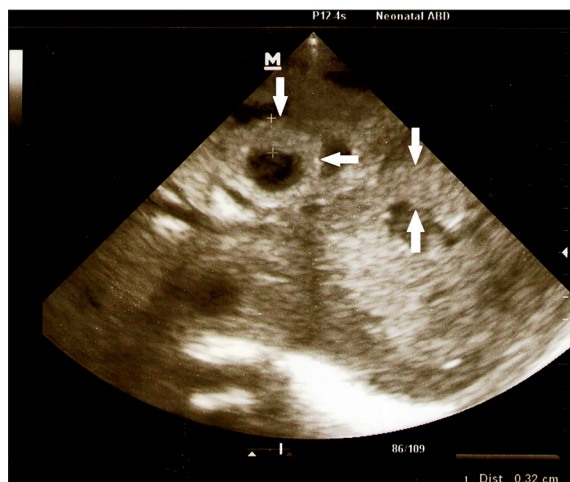
Table 3. Frequency (%) of quadrants with increased bowel wall thickness in the two groups.

Variable	Group		P value
	Controls	Cases	
Increased bowel wall thickness	2 (1.5)	6 (4.4)	0.282
Normal bowel wall thickness	130 (98.5)	130 (95.6)	
Total	132 (100.0)	136 (100.0)	

Mean bowel wall thickness ranged from 1.2 to 3.2 mm (1.609 ± 0.303 mm) in the control group (total of 132 abdominal quadrants) and from 1 to 3.3 mm (1.672 ± 0.437 mm) in the study group (total of 136 abdominal quadrants) (Table 1).

On the other hand, the numbers of neonates with increased bowel wall thickness (<3 mm) and the number of quadrants with evidence of increased bowel wall thickness were compared between the two groups as a categorical variable, using Fisher's exact test. Although thickened bowel wall in the neonates of the study group was three times more frequent, the statistical difference was not significant ($P=0.613$) (Tables 2 and 3, Figure 4).

Bowel wall echogenicity was examined in 136 abdominal quadrants in the study group and 132 quadrants in the control group. Fisher's exact test was also used for comparing two groups. All of the neonates in the control group had normal bowel wall echogenicity and no echogenic dots were observed in their bowel wall. In 1 neonate (2 quadrants of 136 scanned quadrants) in the study group who was at stage IB of the disease (1.47% of total examined quadrants), bowel wall echogenicity was increased due to the presence of echogenic dots which were indicative of intra-mural air (pneumatosis intestinalis) and increased the disease stage to IIA (Figure 5). Although the presence of pneumatosis intestinalis in the bowel wall was confirmed by observing echogenic dots, the difference in the bowel wall echogenicity between the two groups was not statistically significant ($P=0.999$).

**Figure 4.** Sonogram of a 30-week old newborn suspected to NEC shows increased bowel wall thickness (arrows) in association with minimal amount of free fluid.

Neither the control group nor the study group had radiological or sonographical evidence of portal venous gas.

Bowel wall perfusion was also examined in 136 abdominal quadrants in the study group, and 132 quadrants in the control group. Color Doppler signals were 3.12 dots or lines/cm² (ranging from 1 to 7 dots or lines/cm²) in the study group, and 2.88 dots or lines/cm² (ranging from 1 to 5 dots or lines/cm²) in the control group (Figure 6). Neither specific patterns including the ring pattern, Y-shaped pattern or Zebra pattern which were indicative of increased blood pressure, nor the lack of color Doppler signals which

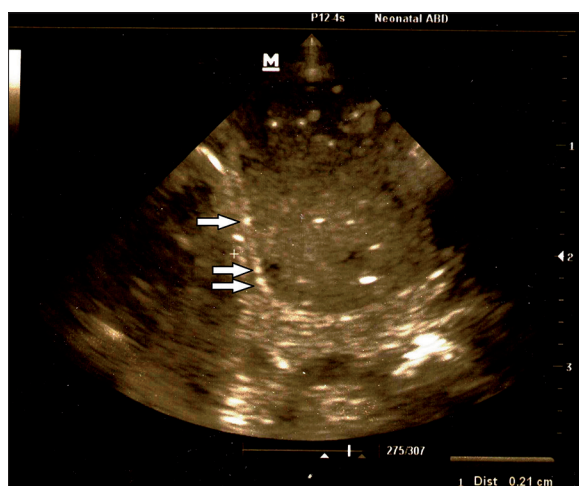


Figure 5. Sonogram of a 27-week old boy with suspected NEC. Multiple echogenic dots (arrows) are seen in the bowel wall associated with borderline thickness of bowel wall (1 mm). These findings are indicative of intra-mural air (Pneumatosis Intestinalis).

were indicative of bowel wall necrosis were observed in the groups (Figures 1–3). The mean \pm SD bowel wall perfusion in the study and control groups was 3.117 ± 0.975 and 2.878 ± 0.538 dots or lines/cm², respectively ($P=0.218$).

Varying amounts of intra-abdominal free fluid were seen in 17 neonates (50%) in the study group according to ultrasonographic estimation. Of those, 13 had minimal amounts of free fluid and 4 had mild amounts. Only in one neonate of the study group, who was at the IB stage of the disease, some internal echoes were seen within the mild amount of free fluid. Twelve neonates in the control group had also minimal amounts of intra-abdominal free fluid (Table 4).

Since the modified Bell's staging criteria and consequently plain abdominal radiography were not able to make a definite diagnosis of stage I NEC, determining the ultrasonographic sensitivity and specificity was impossible.

Table 4. Frequency of ultrasonographic findings in the study and control groups.

Evaluated ultrasonographic features	Control group N=33	Stage IA N=32	Stage IB N=2
Increased bowel wall thickness	1	2	1
Decreased bowel wall thickness	0	0	0***
Increased bowel wall echogenicity	0	0	1**
Increased bowel wall perfusion	0	0	0
Absent bowel wall perfusion	0	0	0
Non-echoic free fluid	12	15*	1
Echoic free fluid	0	0	1
Portal venous gas	0	0	0

* 3 newborns had mild amount of free fluid and minimal amounts of fluid were seen in 12 others; ** bowel wall thickness in one of the patients with stage IB of NEC was 1 mm; *** based on this finding, the patient was reclassified to stage IIA.

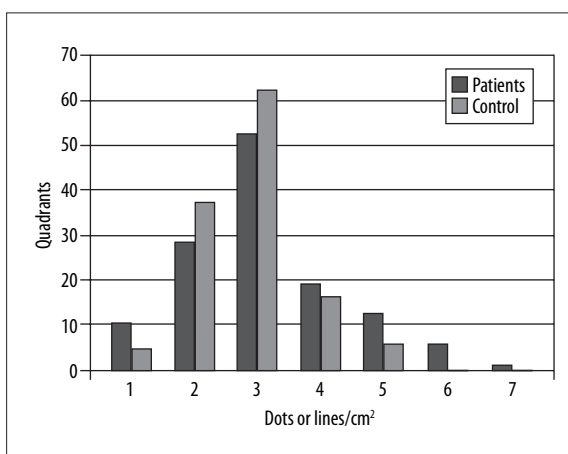


Figure 6. Frequency of bowel wall perfusion in the two groups.

Discussion

This study was a descriptive-analytical one which was performed in a case-control design. The composition and schema of the study group distinguishes this study from the vast majority of case-control studies performed in this field. In most of the mentioned studies, except for the first study of Kim et al. [11], the study group included patients at different stages of NEC (stage IA to IIIB). The ultrasonographic features of such patients, who revealed a different spectrum of pathophysiological and subsequently also ultrasonographic changes, were compared with the control group as a single set [10,13–18].

In our study, of the total neonates recruited in the study group, two (6%) were at stage IB of NEC while the others (94%) were at stage IA, according to the modified Bell's staging criteria. Stage I is the primary stage of the disease in which the occurred pathophysiological, clinical, and radiological changes are mostly minor and non-specific.

On the other hand, many studies have emphasized the superiority of abdominal ultrasonography over plain

abdominal radiography in the diagnosis of complications such as bowel wall thickness, bowel necrosis, echoic free fluid (EFF), focal fluid collections, and portal venous gas (PVG) [10,13–18]. Such complications could only be observed in higher stages of NEC, as visualization of these symptoms at early stages (stage I) is very unlikely and rare. We only investigated the early changes caused by NEC at its early stage (stage I). The occurred changes in the studied variables, due to the minority and mildness of the underlying pathophysiological changes at stage I in comparison with higher stages, should logically be small and often intangible at this stage. However, because early treatment can significantly reduce the morbidity and mortality of the disease, any proof of the superiority of ultrasonography in detecting even small changes in the studied variables could potentially accelerate the process of diagnosis, and ultimately, the treatment.

While radiography can only show evidence of bowel dilatation at stages IA and IB of NEC, it can neither provide any information about bowel dynamics, bowel wall thickness, echogenicity and perfusion or bowel peristalsis, nor can it diagnose minimal amounts of abdominal free fluid and its nature. However, in comparison with radiography, abdominal ultrasonography can provide valuable data about each variable and reveal the last changes in them. Moreover, no exposure to ionizing radiation is one of the most important advantages of this technique over radiography. In the process of diagnosing NEC, most of the neonates repeatedly undergo plain abdominal radiography for detection of pneumatosis intestinalis, and inevitably they receive higher radiation doses gradually. However, performing ultrasonography does not involve the use of ionizing radiation for neonates. Secondly, in NEC patients, as a result of their poor nutritional condition, subcutaneous and intra-abdominal fat, which is an attenuating factor of sound waves, is diminished, and so it provides clearer images with higher quality. Besides, portable ultrasonography machines which meet the highest technological standards in this area can be easily used at the patients' bedside in every condition.

However, no significant statistical difference was observed between the study and control groups regarding the increased mean value of bowel wall thickness and perfusion, and the small existing difference indicated that ultrasonography was able to detect small changes in the values of this variable. Ultrasonographic monitoring and follow-up could help specify changes in the course of the disease quickly. Previous studies also endorsed this fact and emphasized the superiority of ultrasonography over plain abdominal radiography in this field [10,12–18].

Plain abdominal radiography is unable to detect pneumatosis intestinalis in patients with stage I of NEC. However, visualization of echogenic dots in the walls, even in one patient, improved the diagnostic stage – from stage I to IIA. This fact reveals the superiority of ultrasonography in detecting this key finding in the diagnostics of this disease despite the lack of a significant difference between the two groups in terms of bowel wall echogenicity. Other studies also endorsed this fact [10,12–18]. In one study, it was determined that observation of echogenic dots or dense granular echogenicities in sonographic scans of the

bowel wall can be helpful for early diagnosis of NEC [12]. The results of one study showed that an adverse outcome was associated with the sonographic findings of free gas, focal fluid collections, or three or more of the following: increased bowel wall echogenicity, absent bowel perfusion, portal venous gas, bowel wall thinning, bowel wall thickening, free fluid with echoes and intramural gas. Therefore, ultrasonographic findings are useful in predicting the outcome and therefore might help guide the management due to the ability to diagnose changes [13].

Although mean bowel wall perfusion in the study group was only slightly higher than in the control group, it is obvious that NEC causes some changes in bowel wall perfusion and color Doppler patterns, which become more evident as the disease progresses. Other studies proved this fact too [10,12–18].

In our study, none of the patients had portal venous gas. Also the results from other studies indicated that visualization of portal venous gas in early stages of NEC is very unlikely and rare [10,12–18].

Another advantage of ultrasonography over plain abdominal radiography is its ability to detect small amounts of intra-abdominal free fluid and determine its nature. Radiography revealed no evidence of intra-abdominal free fluid in any of the patients enrolled in this study, while ultrasonography showed varying amounts of intra-abdominal free fluid (minimal to mild) in 29 (43.28%) of the total 67 studied neonates. While the presence of very small amounts (minimal) of "intra-abdominal free fluid" could be considered as a normal finding, their relatively significantly higher values in the study group (50%) than in the control group (36.36%) were indicative of higher probability of visualization of that fluid in such a group. This fact can be justified with respect to the existence of inflammatory processes in the bowel and abdominal cavity of the neonates.

Echogenic debris within intra-abdominal free fluid results from the presence of inflammatory or necrotic tissue and cellular components, entering of the intestinal contents into the abdominal cavity, and intra-abdominal bleeding. It is another feature and advantage of ultrasonography in patients suffering from NEC, which can be helpful in predicting both the incidence of intestinal ischemia and necrosis, and other complications associated with such a disease, including bowel perforation. The presence of free fluid containing echogenic debris in one of the patients who was at stage IB of NEC, as well as echogenic dots in his bowel walls (indicative of pneumatosis intestinalis) shows that the neonates were affected by ischemia and necrosis (Figure 7). Moreover, the observed changes in the nature of the secondary free fluid led to the occurrence of such processes and improved the disease stage to stage IIA. The results of one study suggested that portal venous gas (PVG) was merely used for diagnosing NEC in neonates with suspected or definitely diagnosed NEC. Moreover, the sensitivity and specificity of ultrasonography were estimated at 45% and 86%, respectively for diagnosing the PVG stage of \geq II. Therefore, high specificity is suggested as a helpful evaluation method for diagnosis of NEC [15].

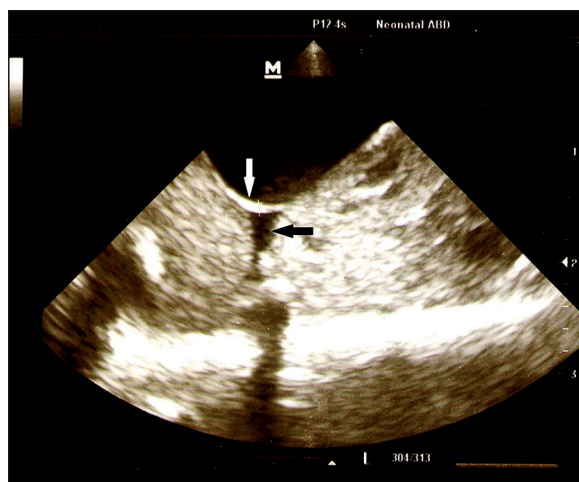


Figure 7. Sonogram of a 27-week old boy suspected to NEC. A dilated bowel loop with increased bowel wall echogenicity (white arrow) is seen, indicative of intra-mural air. Echoic free fluid also is seen adjacent to affected bowel loop (black arrow).

This study had several limitations. The significant decline in the number of patients with NEC in recent years due to the improvements in prenatal and postpartum care and promotion of breastfeeding made the performance of a larger study impossible in the desired timeframe. It is obvious that performing broader studies will be followed by acquiring more accurate quantitative and qualitative information. Due to the fact that our study was merely limited to the patients with suspected stages IA and IB of NEC, and that the mentioned evaluations were impossible in those with a definitely diagnosed disease who revealed quite significant ultrasonographic changes in the mentioned properties in comparison with a normal population, differences between study and control groups were not statistically

significant despite the records of various values of such variables.

Despite the existence of all the mentioned limitations, there are numerous advantages of ultrasonography over plain abdominal radiography. The most important merits of this technique are no exposure to ionizing radiation, no limitation on frequent use, availability, possibility of using at patient's bedside in different clinical conditions, possibility of evaluating indices of bowel dynamics, bowel wall thickness, echogenicity, pneumatosis intestinalis, the rate of bowel wall perfusion, ability of diagnosing various amounts of intra-abdominal free fluid, determining the nature and estimating the amount of liquid. Therefore, using abdominal ultrasonography (both gray-scale and color Doppler) can improve the process of diagnosis and treatment of NEC.

Conclusions

Various differences were observed between the study and control groups with respect to bowel wall thickness, echogenicity, and perfusion in sonography and color Doppler evaluation of the cases suspected to early stages of NEC. Although those differences were not statistically significant, and relatively equal accuracy was observed between sonography and radiography, considering different findings in these two methods and ability of sonography to detect early changes and the fact that serial abdominal X-rays are time-consuming, the use of sonography and color Doppler as a triage method in detecting early stages of NEC can improve the process of diagnosis and treatment of NEC.

Conflict of interest

None.

References:

- Epelman M, Daneman A, Navarro OM et al: Necrotizing enterocolitis: review of state-of-the-art imaging findings with pathologic correlation. *Radiographics*, 2007; 27(2): 285-305
- Balance WA, Dahms BB, Shenker N, Kliegman RM: Pathology of neonatal necrotizing enterocolitis: a ten-year experience. *J Pediatr*, 1990; 117(1): S6-13
- Ostlie DJ, Spilde TL, St Peter SD et al: Necrotizing Enterocolitis in full-term infants. *J Pediatr Surg*, 2003; 38(7): 1039-42
- Rowe MI, Reblock KK, Kurkchubasche AG, Healey PJ. Necrotizing enterocolitis in the extremely low birth weight infant. *J Pediatr Surg*, 1994; 29(8): 987-90
- Martinez-Tallo E, Claire N, Bancalari E: Necrotizing enterocolitis in full-term or near-term infants: Risk factors. *Biol Neonate*, 1997; 71(5): 292-98
- Bolisetty S, Lui K, Oei J, Wojtulewicz J: A regional study of underlying congenital diseases in term neonates with necrotizing enterocolitis. *Acta Paediatr*, 2000; 89(10): 1226-30
- Buonomo C: The radiology of necrotizing enterocolitis. *Radiol Clin North Am*, 1999; 37(6): 1187-98
- Thompson AM, Bizzarro MJ: Necrotizing enterocolitis in newborns: pathogenesis, prevention and management. *Drugs*, 2008; 68(9): 1227-38
- Grosfeld JL, Chaet M, Molinari F et al: Increased risk of necrotizing Enterocolitis in premature infants with patent ductus arteriosus treated with indomethacin. *Ann Surg*, 1996; 224(3): 350-55
- Faingold R, Daneman A, Tomlinson G et al: Necrotizing Enterocolitis: assessment of bowel viability with color Doppler US. *Radiology*, 2005; 235(2): 587-94
- Walsh MC, Kliegman RM: Necrotizing enterocolitis: treatment based on staging criteria. *Pediatr Clin North Am*, 1986; 33(1): 179-201
- Kim WY, Kim WS, Kim IO et al: Sonographic evaluation of neonates with early-stage necrotizing enterocolitis. *Pediatr Radiol*, 2005; 35(11): 1056-61
- Silva CT, Daneman A, Navarro OM et al: Correlation of sonographic findings and outcome in necrotizing enterocolitis. *Pediatr Radiol*, 2007; 37(3): 274-82
- Miranda FC, Sameshima YT, Deutsch ADA et al: Ultrasonography in diagnosis of necrotizing enterocolitis. *Einstein*, 2009; 7(1): 91-95
- Dördelmann M, Rau GA, Bartels D et al: Evaluation of portal venous gas detected by ultrasound examination for diagnosis of necrotising enterocolitis [abstract]. *Arch Dis Child Fetal Neonatal Ed*, 2009; 94(3): F183-87
- Kim WY, Kim WS, Kim IO, Kang GH: Bowel sonography in sepsis with pathological correlation: an experimental study. *Pediatr Radiol*, 2011; 41(7): 237-43
- Dilli D, Suna Oğuz S, Erol R et al: Does abdominal sonography provide additional information over abdominal plain radiography for diagnosis of necrotizing enterocolitis in neonates? [abstract]. *Pediatr Surg Int*, 2011; 27(3): 321-27
- Shebrya NH, Amin SK, El-Shinnawy MA, Imam SS: Abdominal ultrasonography in preterm necrotizing enterocolitis. Is it superior to plain radiography? *The Egyptian Journal of Radiology and Nuclear Medicine*, 2012; 43: 457-63