

## Hybrid Procedure for Pulmonary Atresia with Ventricular Septal Defect in a Low Birth Weight Neonate

Ji Young Park, M.D., Dong-Man Seo, M.D., Hong Ju Shin, M.D., Soo-Jin Kim, M.D., Jae Sung Son, M.D.

Cardiac surgery in neonates with congenital heart disease has progressed dramatically in the past three decades. However, low-birth-weight neonates with congenital heart disease continue to challenge the intellectual and technical skills of healthcare professionals. We present a case of a low-birth-weight neonate with pulmonary atresia and a ventricular septal defect, in whom palliation was achieved with a right ventricular outflow tract stent using a hybrid procedure.

Key words: 1. Stents  
2. Pulmonary atresia  
3. Neonate  
4. Heart septal defect, ventricular

### CASE REPORT

A male infant born at 38 weeks of gestation who had severe cyanosis and tachypnea immediately after birth was transferred to the hospital 1 day after he was born. His body weight was 2,005 g at birth. He showed severe acidosis with 65% of saturation and 6.9-83-95-19 of arterial blood gas analysis at 10 L oxygen. His blood pressure was 60/40 mmHg, heart rate was regular (specifically 150/min), respiratory rate was 50/min, and body temperature was 37.0°C. On chest X-ray, the cardiothoracic ratio was 0.74, indicating that critical cardiomegaly and congestion was not distinctive, but that vascularity was reduced. Grade II systolic murmur was heard in left upper chest. Transthoracic echocardiography showed an atretic pulmonary valve and a ventricular septal defect (Fig. 1). The patient was intubated immediately, had a mechanical ventilator management administered, and was hos-

pitalized at the neonate intensive care unit.

Because the patient's condition was stable following hospitalization, he was extubated on hospital day 8 and the dose of prostaglandin E1 was reduced to 0.001 mcg/kg/min. On hospital day 10, because it was difficult to hear a patent ductus arteriosus murmur and the patient was desaturated down to SaO<sub>2</sub> 60%, the prostaglandin E1 dose was increased to 0.01 mcg/kg/min. The patient showed continued apnea and bradycardia, so there was no time to wait for weight gain. The patient's hybrid operation was performed on postnatal day 17. Cannulas were inserted into the aorta and the right atrium following median sternotomy, and then the cardiopulmonary bypass (CPB) was initiated. The main pulmonary artery was incised vertically. The atretic pulmonary valve (PV) was perforated using a beaver blade and extended by sharp mosquito. A Genesis stent (Cordis, Warren, NJ, USA) was then inserted through the incision into the main

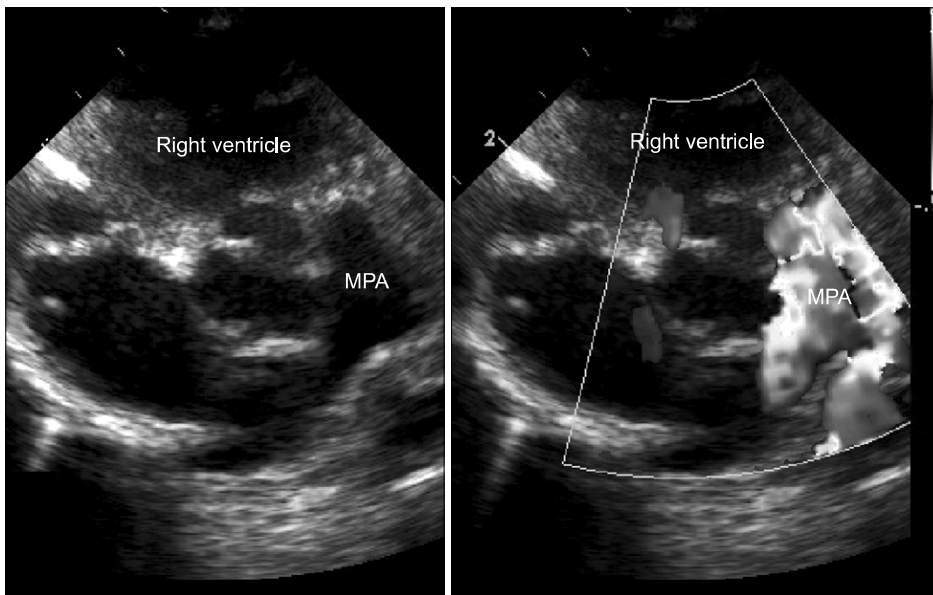
Department of Thoracic and Cardiovascular Surgery, Konkuk University Medical Center, Konkuk University School of Medicine

Received: October 2, 2011, Revised: November 1, 2011, Accepted: November 11, 2011

Corresponding author: Dong-Man Seo, Department of Thoracic and Cardiovascular Surgery, Konkuk University Medical Center, Konkuk University School of Medicine, 120 Neungdong-ro, Gwangjin-gu, Seoul 143-729, Korea  
(Tel) 82-2-2030-7599 (Fax) 82-2-2030-7733 (E-mail) dmseo@kuh.ac.kr

© The Korean Society for Thoracic and Cardiovascular Surgery. 2013. All right reserved.

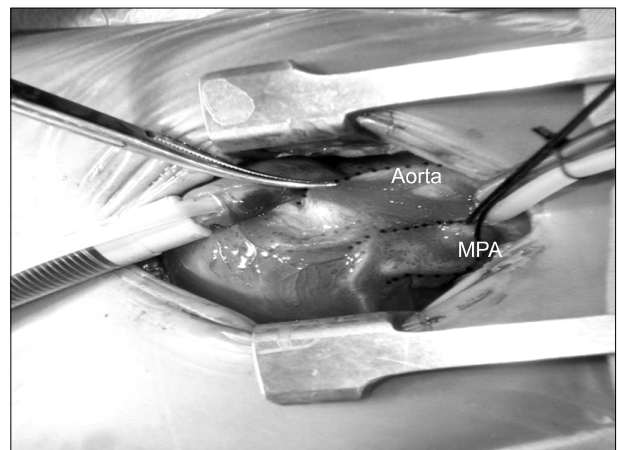
© This is an open access article distributed under the terms of the Creative Commons Attribution Non-Commercial License (<http://creativecommons.org/licenses/by-nc/3.0>) which permits unrestricted non-commercial use, distribution, and reproduction in any medium, provided the original work is properly cited.



**Fig. 1.** The parasternal short axis view, showing the atretic pulmonary valve; there is no outflow from the right ventricle to the main pulmonary artery (MPA).

pulmonary artery, and a guide wire was then inserted into the sheath and used to guide the balloon across the pulmonary valve. Catheter ballooning was immediately conducted. Subsequently, the left anterior descending coronary artery (LAD) was observed across the right ventricular outflow tract (RVOT) (Fig. 2). The balloon was inflated to 8 atm to avoid LAD compression. Transesophageal echocardiography (TEE) was then conducted after the CPB was stopped. Because the patient's weight was so low to apply a usual TEE probe, intracardiac echocardiography (ICE) probe was used as an alternative to decide the final location. On TEE, the stent proximal diameter was measured at 3 mm, and the oxygen saturation at  $\text{FiO}_2$  0.6 was 66%. To increase the blood flow of the main pulmonary artery, ballooning was performed at 12 atm after resuming the CPB. The TEE showed no change in the 3 mm proximal diameter, but an increased blood flow was observed that resulted from a side hole. At that moment the oxygen saturation at  $\text{FiO}_2$  0.3 was at 85%.

The patient underwent extubation on postoperative day 3 and started to feed on day 4. On postoperative day 10, an echocardiogram was performed because saturation was not maintained and tachypnea was observed. There was no sign of stent dislocation or migration, but the proximal stent became narrow due to the right ventricular muscle partially blocking the stent opening. Balloon angioplasty was then applied. Increased blood flow to the RVOT after angioplasty

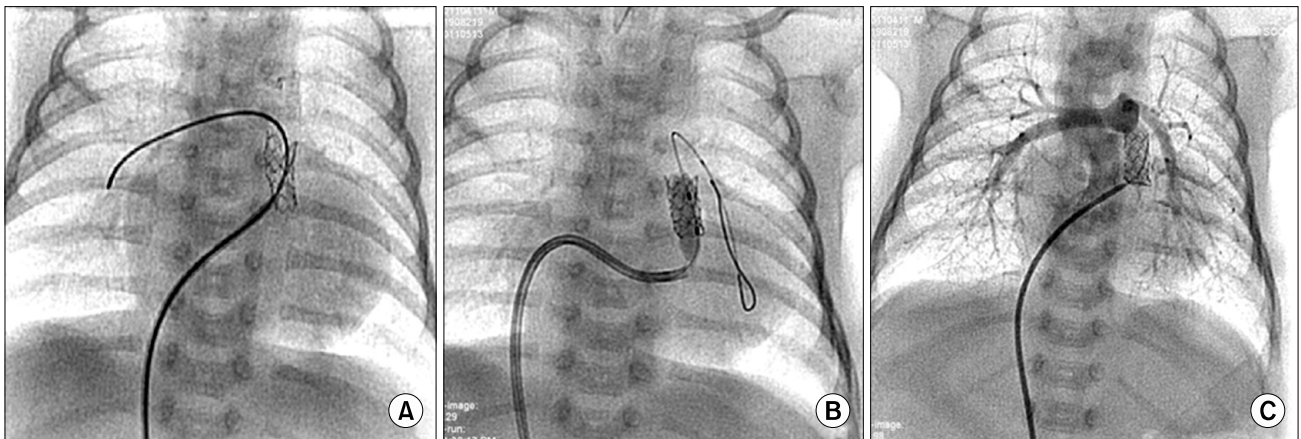


**Fig. 2.** Intraoperative photograph. It shows the left anterior descending coronary artery crossing the right ventricular outflow tract anteriorly. MPA, main pulmonary artery.

was observed (Fig. 3). Since then, the patient gained weight without difficulty and was discharged from the hospital on postoperative day 43, weighing at 3,100 g. The patient was doing well during follow-up at approximately 3 months.

## DISCUSSION

Despite advances in neonatal cardiac surgery, prematurity and low birth weight remain significant risk factors for poor outcome. However, data from previous studies have indicated



**Fig. 3.** (A) Angiography from the main pulmonary artery showed stenosis of the proximal site of the stent. (B) An angioplasty balloon is inflated. (C) Angiography after ballooning, with improvement of blood flow to the main pulmonary artery.

that delay of complete repair in order to achieve weight gain may result in both morbidity and mortality during medical treatment [1]. Patients such as the one in this report thus present difficult management decisions. Other surgical options of pulmonary atresia (PA) with ventricular septal defect (VSD) included early total correction or palliation with a systemic-to-pulmonary shunt. Using right ventricular PA shunt surgery for early total correction or palliation in patients with PA with VSD is still controversial. Early total correction is currently favored over palliation because it can prevent risks such as hemodynamic instability or sudden death due to the thrombus blocking the shunt [2]. Given our patient's weight, we concluded that both of these approaches carried significant risks. Instead, we selected palliation by placement of a stent in the RVOT. This approach successfully provided a controlled increase in the pulmonary blood flow. In comparison with palliation using a systemic-to-pulmonary shunt, the RVOT stent avoided the difficulties of appropriate shunt size selection in a small patient and it also allowed for a period of weight gain, at which time a successful complete repair was carried out. However, percutaneous perforation and ballooning have been associated with higher rates of procedural failure and serious complications. Unfortunately, even after successful percutaneous balloon valvuloplasty, 43% to 51% of neonates need urgent procedures, including Blalock-Taussig shunt placements, RVOT reconstruction, or both [3]. Considering these problems, the percutaneous approach for patients

such as the one in our report can be challenging due to the patient's low weight. In addition, the passage of large delivery catheters in small infants may result in rhythm disturbances and hemodynamic compromise [4]. Schmitz et al. [5] reported that a hybrid procedure that combined the surgical procedure and the percutaneous intervention could reduce the risks of surgery and intervention, which can be a new treatment option for patients with a complex congenital heart defect. In addition, Zhang et al. [6] reported that four neonates that each weighed 3 to 4.5 kg with pulmonary atresia and an intact ventricular septum were managed using a RVOT stent insertion under the condition of a beating heart. Thus, the authors of this report planned an intraoperative RVOT stent insertion.

In this hybrid procedure, the PV was first perforated, and then the balloon was delivered through the main pulmonary artery to the RV free wall. TEE using an ICE probe was utilized not only to guide the procedure but also to evaluate the effectiveness of valvuloplasty with monitoring of the trans-PV flow and the gradient pressure.

Intraoperative stent insertion can be considered in the following cases: if percutaneous access using a catheter is impossible or difficult, if concomitant surgery is required due to a concomitant anomaly, and if hemodynamic instability or complications are expected to increase during percutaneous stent insertion.

Potential complications such as balloon rupture and vas-

cular tear can be avoided or easily recognized. Thus, appropriate action can be taken immediately. In addition, it is important to check for a concomitant coronary artery anomaly during the RVOT stent ballooning. In this study, LAD was traversely located on the RVOT. Such has been the case in approximately 5% to 12% of the patients who belong to the spectrum of tetralogy of Fallot [7]. Hamzeh et al. [8] reported that left main coronary artery compression occurred in right pulmonary artery stent insertion. In particular, the hybrid procedure has the advantage of more easily identifying coronary artery compression via the pulmonary artery.

In conclusion, intraoperative stent insertion for low-birth weight babies with PA and VSD is a new and safe treatment method that reduces complications. It will be an alternative method for PA/VSD patients if objective evidence of its benefits is accumulated from the long-term outcomes of studies of larger patient groups.

#### CONFLICT OF INTEREST

No potential conflict of interest relevant to this article was reported.

#### REFERENCES

1. Wernovsky G, Rubenstein SD, Spray TL. *Cardiac surgery in the low-birth weight neonate: new approaches*. Clin Perinatol 2001;28:249-64.
2. Kwak JG, Lee CH, Lee C, Park CS. *Surgical management of pulmonary atresia with ventricular septal defect: early total correction versus shunt*. Ann Thorac Surg 2011;91:1928-34.
3. McLean KM, Pearl JM. *Pulmonary atresia with intact ventricular septum: initial management*. Ann Thorac Surg 2006;82:2214-9.
4. Bacha EA, Hijazi ZM, Cao QL, et al. *Hybrid pediatric cardiac surgery*. Pediatr Cardiol 2005;26:315-22.
5. Schmitz C, Esmailzadeh B, Herberg U, et al. *Hybrid procedures can reduce the risk of congenital cardiovascular surgery*. Eur J Cardiothorac Surg 2008;34:718-25.
6. Zhang H, Li SJ, Li YQ, Wang H, Hu SS. *Hybrid procedure for the neonatal management of pulmonary atresia with intact ventricular septum*. J Thorac Cardiovasc Surg 2007;133:1654-6.
7. Li J, Soukias ND, Carvalho JS, Ho SY. *Coronary arterial anatomy in tetralogy of Fallot: morphological and clinical correlations*. Heart 1998;80:174-83.
8. Hamzeh RK, El-Said HG, Moore JW. *Left main coronary artery compression from right pulmonary artery stenting*. Catheter Cardiovasc Interv 2009;73:197-202.