

# Complete obliteration of a spontaneous pediatric vertebral arteriovenous fistula with patency of the parent vertebral artery

## A case report

Chang-wei Zhang, MD, PhD<sup>a</sup>, Ting Wang, MD<sup>a</sup>, Seidu A. Richard, MD, PhD<sup>a,b</sup>, Xiao-dong Xie, MD, PhD<sup>a,\*</sup>

### Abstract

**Rationale:** Vertebral arteriovenous fistulas (VAVFs) are depicted with anomalous connections between the vertebral artery, or its branches, and the adjacent venous system. Most VAVFs occur as a result of direct trauma during accidents, whereas others have iatrogenic origin.

**Patient Concerns:** We report a case of 11-year-old male who presented with right limb weakness and walking instability.

**Diagnosis:** Magnetic resonance angiography as well as digital subtraction angiogram (DSA) of the neck demonstrated a right VAVF. The cervical medulla was compressed by a dilated vein in vertebral canal. The blood supply of the fistula was from the right vertebral artery, whereas drainage was via epidural and paraspinal venous plexus.

**Interventions:** We introduced the TransForm Occlusion Balloon Catheter into right vertebral artery, identified the VAVF, and occluded it with the balloon.

**Outcomes:** We successfully obliterated the VAVF with patency of parent vertebral artery with a balloon. The symptoms of the patient were relieved after the procedure. Two years' follow-up revealed no recurrence of the fistula. The patient is currently well.

**Lessons:** Patency of the parent artery following obliteration a VAVF is still a challenge. Obliteration of the VAVF with a balloon while the parent vertebral artery is still patent is very possible.

**Abbreviations:** DSA = digital subtraction angiogram, VAVFs = vertebral arteriovenous fistulas.

**Keywords:** angiography, balloon, endovascular, spontaneous, VAVFs

Editor: N/A.

*Ethics approval and consent to participate:* The ethical committee of West China hospital full approved our case study. The child's parents were informed about our intention to involve him in a case study and they agreed to partake in the study.

*Consent for Publication:* The child's parents were dually informed about our intention to publish his case and they fully consented to the use of these documents. A written informed consent was obtained. A written concern for publication was signed. The hospital also consented to the use of this information for publication.

*The authors report no conflicts of interest.*

*Funding Source:* No funding for this paper.

<sup>a</sup> Department of Neurosurgery, West China Hospital, Sichuan University, 37 Guo Xue Xiang Street, Chengdu, P. R. China, <sup>b</sup> Department of Medicine, Princefield University, Ghana, West Africa.

\* Correspondence: Xiao-dong Xie, Department of Neurosurgery, Postgraduate Training Centre, West China Hospital, Sichuan University, 37 Guo Xue Xiang Road, Chengdu, Sichuan 610041. P. R. China (e-mail: vipneurology@126.com).

Copyright © 2019 the Author(s). Published by Wolters Kluwer Health, Inc. This is an open access article distributed under the Creative Commons Attribution License 4.0 (CCBY), which permits unrestricted use, distribution, and reproduction in any medium, provided the original work is properly cited.

*How to cite this article:* Zhang Cw, Wang T, Richard SA, Xie Xd. Complete obliteration of a spontaneous pediatric vertebral arteriovenous fistula with patency of the parent vertebral artery. *Medicine* 2019;98:41(e17466).

Received: 6 April 2019 / Received in final form: 14 August 2019 / Accepted: 11 September 2019

<http://dx.doi.org/10.1097/MD.00000000000017466>

## 1. Introduction

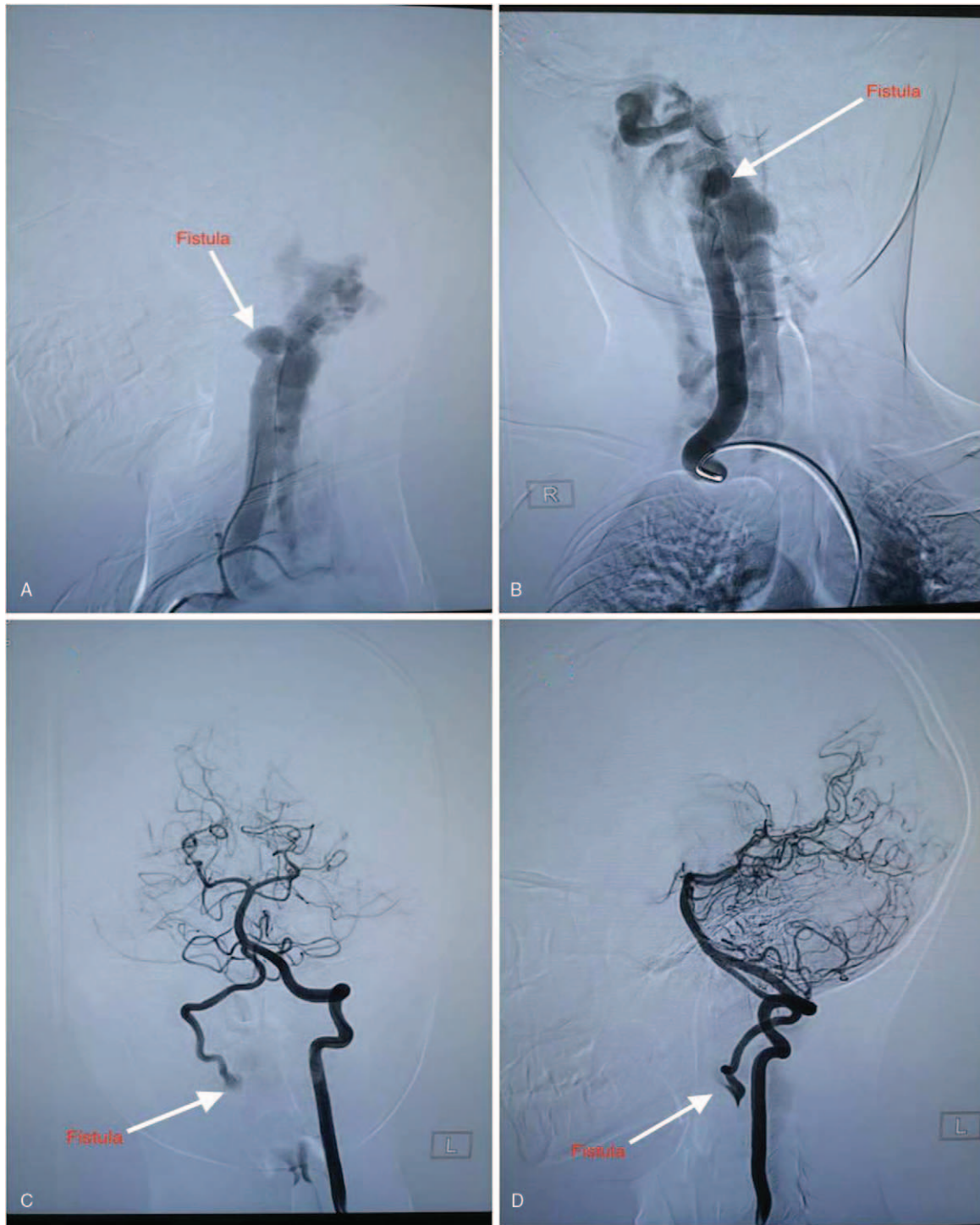Vertebral arteriovenous fistulas (VAVFs) are depicted with anomalous connections between the vertebral artery, or its branches, and the adjacent venous system.<sup>[1,2]</sup> Most VAVFs occur as a result of direct trauma during accidents, whereas others have iatrogenic origin.<sup>[3]</sup> Interesting, VAVFs that do not occur as a result of trauma or iatrogenic origin are either congenital or spontaneous.<sup>[3,4]</sup> The clinical presentations usually vary from asymptomatic to symptomatic with the most cardinal symptom being tinnitus. Also, vertigo and diplopia usually occur as a result of vertebrobasilar ischemia.<sup>[3]</sup> The criterion standard radiological modality used in evaluating VAVFs is conventional catheter angiography.<sup>[1,3,5]</sup> This modality is able to reveal all the anatomic characteristics of the VAVF as well as offer the accurate hemodynamics states, thereby aiding in planning interventional procedures. Nevertheless, computed tomographic angiography is also valuable in evaluating VAVFs.<sup>[3,6]</sup> We present a pediatric case of VAVF in whom we successfully obliterated the VAVF with patency of parent vertebral artery.

## 2. Case presentation

An 11-year-old male presented with right limb weakness and walking instability. We noticed a pulsating swelling on the right lateral side of the neck. The swelling was around the C1 and C2 vertebral levels. Auscultation on the swelling revealed a bruit. There was no history of trauma before this presentation. He has

never had a central line passed before or cannulation of veins in the neck. His medical history was unremarkable. He was initially seen and managed in a local hospital before his referral to our facility. Magnetic resonance angiography done at our facility (West China Hospital) showed a fistula with a wide neck between the right distal vertebral artery and paraspinal venous plexus. This prompted us to do a digital subtraction angiogram (DSA). On DSA, we noticed a high-flow fistula with total antegrade

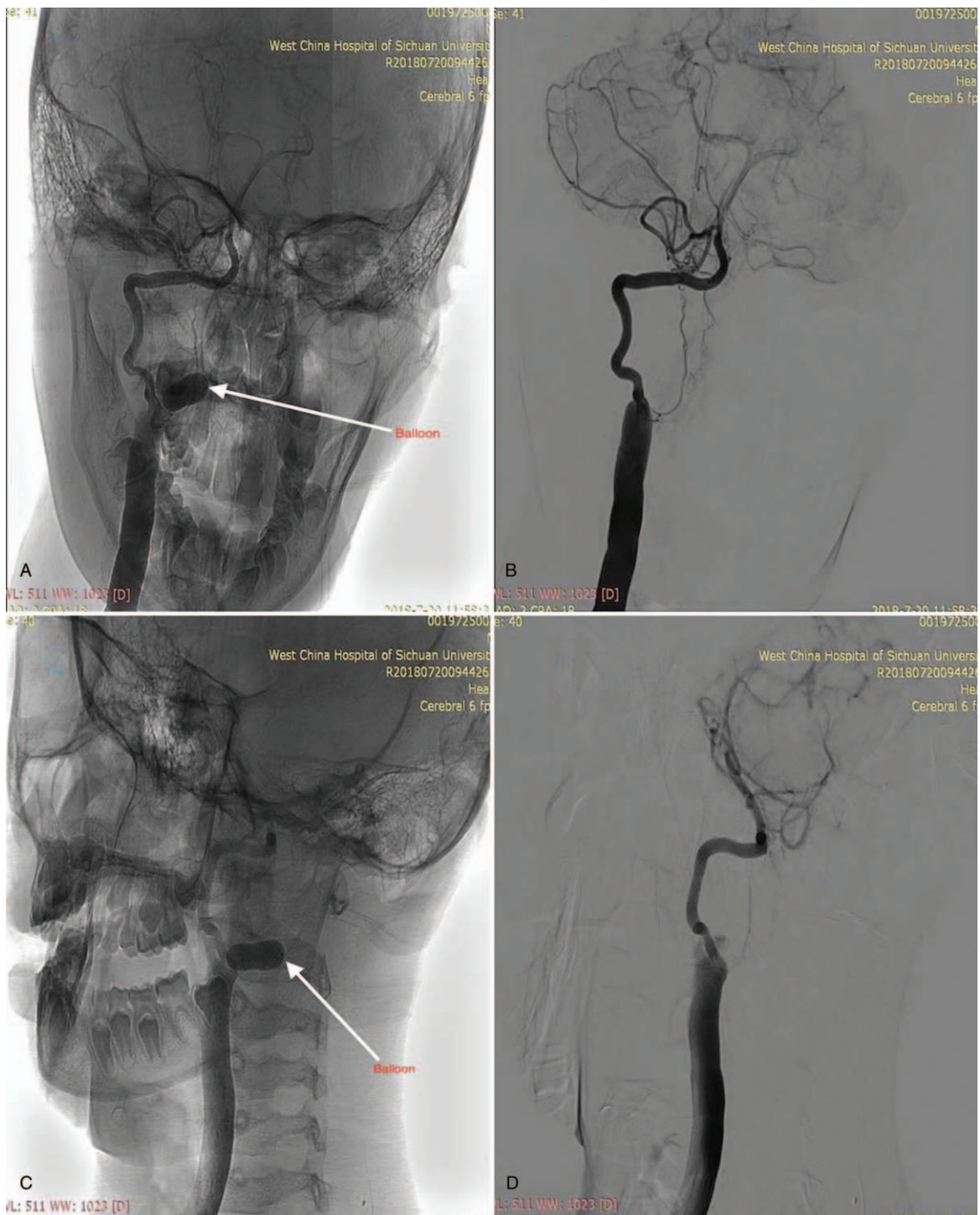
blood flow from the V3 segment of the vertebral artery (Fig. 1A–D). No further arterial supply was found except the vertebral artery. The venous drainage was via a complex venous plexus of epidural and paraspinal veins. We noticed during our evaluation that preservation of both the distal and proximal vertebral artery via endovascular obliteration would not result into severe complications owing to none contrast filling at the right distal vertebral artery. We also observed that the contralateral



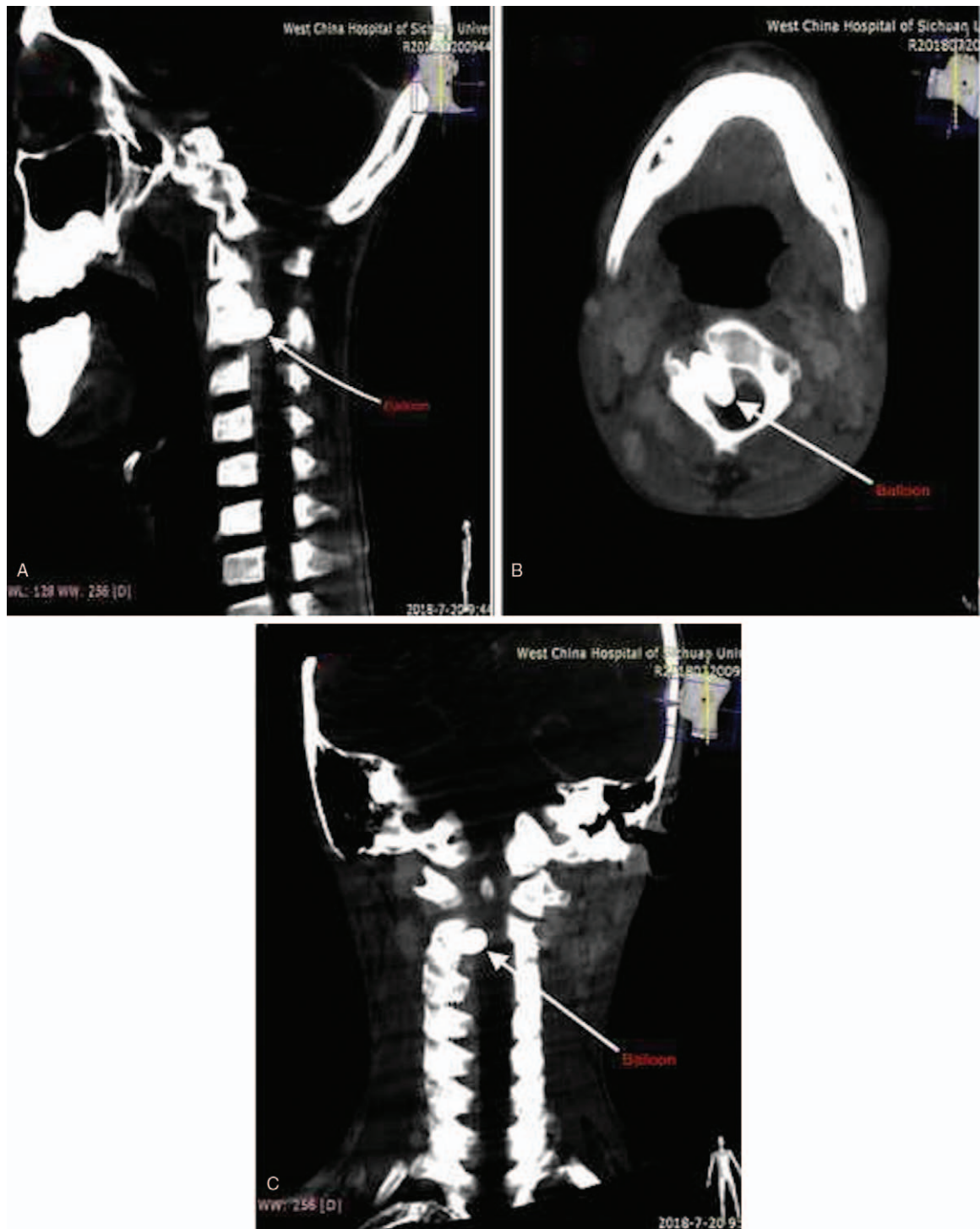
**Figure 1.** A and B are preoperative digital subtraction angiogram (DSA) images showing the lateral and anteroposterior views of right vertebral artery. C and D are preoperative DSA images showing the anteroposterior and lateral views of left vertebral artery.

compensatory blood supply to the basilar artery was adequate. However, posterior cerebellar and/or spinal infarct risk and the fact that the patient already had neurological defect, prompted us to preserve the vertebral artery. Therefore, endovascular approach with balloons was the most suitable treatment option. We introduced the TransForm Occlusion

Balloon Catheter into right vertebral artery, identified the VAVF, and occluded it with the balloon. We successfully obliterated the VAVF with patency of parent vertebral artery (Fig. 2A–D). The symptoms of the patient were relieved immediately after the procedure. Postoperative magnetic resonance imaging revealed occlusion of the fistula with the balloon (Fig. 3A–C). Two years’



**Figure 2.** A and B are postoperative digital subtraction angiogram (DSA) images showing the anteroposterior view of right vertebral artery. C and D are postoperative DSA images showing lateral view of right vertebral artery.



**Figure 3.** A, B, and C are postoperative magnetic resonance imaging images showing occlusion of the fistula with the balloon.

follow-up revealed no recurrence of the fistula. The patient is currently well.

### 3. Discussion

VAVFs are depicted with anomalous connections between the vertebral artery, or its branches, and the adjacent venous system.<sup>[2,7]</sup> Most VAVFs occur as a result of direct trauma during

accidents, whereas others have iatrogenic origin. Iatrogenic VAVFs can occur as a result of direct angiographic puncture of the vertebral artery or as a result of struggles in cannulating the internal jugular vein during insertion of a central line.<sup>[2]</sup> Our patient was a child with spontaneous VAVF. Interestingly, our patients did not have fibromuscular dysplasia or neurofibromatosis, although majority of spontaneous VAVFs occurred in patients with these anomalies.<sup>[7,8]</sup>

To accurately and efficiently diagnose as well as manage VAVFs cases, Lasjaunias divided them into upper cervical and lower cervical.<sup>[7,9]</sup> The upper cervical VAVFs usually encompass lesions at C1-2 level, whereas lower cervical VAVFs encompass lesions below this level. Most often, the upper cervical VAVFs usually derived their blood supply from the occipital artery through an anastomoses with the vertebral artery.<sup>[7,9]</sup> Also, for a better safeguarding of the vertebral artery, Lasjaunias<sup>[9]</sup> further divided the VAVFs in the upper cervical group into segmental and intersegmental. Nevertheless, in most cases, the venous drainage is usually channeled to the suboccipital and vertebral plexus.<sup>[7]</sup>

The single most important sign used in diagnosing VAVFs is a bruit.<sup>[7]</sup> Also, symptoms like tinnitus or even heart failure from shunting may be obvious. Nevertheless, in cases with high-flow fistulae, symptoms such as hemorrhage, steal phenomena, intracranial venous hypertension, or embolic stroke may also occur.<sup>[10]</sup> Furthermore, cervical radiculopathy may also occur when there is a direct compression of the nerve roots by the draining veins.<sup>[7,11]</sup> Myelopathy has been reported in some cases. This often occurs as a result of mass effect from dilated veins in the epidural space or an epidural bleed. Myelopathy may also be secondary to venous hypertension.<sup>[7,12]</sup> Conventional or selective catheter angiography is the “criterion” standard modality used to diagnose VAVFs.<sup>[1,4,7]</sup>

Endovascular techniques are the preferred management modality of VAVFs. These techniques usually utilize detachable balloons, stent grafts, as well as detachable coils as embolic materials.<sup>[1,2]</sup> Most often, the principal aim of management is occlusion of the fistula as well as conservation of the vertebral artery. This is often very difficult to achieve. Nevertheless, during the procedure, the surgeon should as much as possible prevent proximal vessel ligation to avoid vertebrobasilar inadequacy, as this usually increases retrograde flow.<sup>[7,9]</sup> Although various agents as well as treatment modality have been proposed for the management of VAVFs, balloons are preferred since precise positioning of the embolic agent can be done.<sup>[5,7]</sup> Besides, other embolic agents may be used to supplement the closure in cases of partial closures with balloons. In our case, we achieved total occlusion of fistula with patency of the parent artery. Usually, the use of balloons may not be feasible, particularly from the contralateral artery, if there is obvious tortuosity or narrowing of the arterial lumen. The most suitable treatment modality after careful evaluation of our patient was the use of a balloon.

Some authors have used the contralateral approach to achieve satisfactory results. In this approach, they used coils to occlude the vertebral artery just distal to the fistula. The traditional surgical procedure usually involves direct surgical ligation of punctiform fistula.<sup>[1]</sup> Nevertheless, during surgical intervention, the surgeon obtains a bypass venous graft from the subclavian to reconstruct the distal vertebral artery for large, complex fistulas with several arterial feeders.<sup>[1,5]</sup> The major drawbacks with surgical intervention are usually steal flow symptoms, massive hemorrhages, and injuries to surrounding structures.<sup>[1,5]</sup> The use of endovascular stent-graft repair is not much as compare to other agents.<sup>[13–15]</sup> These devices are best substitutes for the management of VAVF because they are able to preserve vessel patency. Nevertheless, the current stent-graft available is very rigid and not appropriate for vessels that are tortuous.<sup>[1,13,14]</sup>

Endovascular treatment with a detachable balloon to occlude the fistula is the best treatment modality as compared to microsurgical ligation, coil embolization, or stent-grafting.<sup>[1]</sup>

Several authors have demonstrated that detachable balloons are most appropriate for occlusion of fistulas. They argue that these balloons can be repeatedly inflated and deflated before their detachment so that exact position and ideal occlusion of the fistula can be attained.<sup>[1,12,16]</sup> Regardless of which ever treatment modality that is adapted by the surgeon, evaluation of the fistula and parent vessel anatomy, hemodynamics and flow (high or low) is key to attaining successful fistula occlusions.<sup>[1,17]</sup>

#### 4. Conclusion

We present a case of a VAVF in a pediatric patient in whom we used a balloon to completely obliterate the shunt with patency of the parent vertebral artery. Successful obliteration of the fistula with patency of parent vertebral artery has not been achieved in all reported cases in literature. The symptoms of the patient were relieved after the procedure and 2 years’ follow-up revealed now recurrence of the fistula.

#### Author contributions

**Conceptualization:** Chang Wei Zhang, Ting Wang, Seidu A. Richard, Xiao Dong Xie.

**Data curation:** Chang Wei Zhang, Ting Wang, Seidu A. Richard.

**Formal analysis:** Ting Wang, Seidu A. Richard, Xiao Dong Xie.

**Funding acquisition:** Chang Wei Zhang, Xiao Dong Xie.

**Investigation:** Ting Wang.

**Methodology:** Seidu A. Richard.

**Supervision:** Chang Wei Zhang, Xiao Dong Xie.

**Writing – original draft:** Seidu A. Richard.

**Writing – review & editing:** Chang Wei Zhang, Ting Wang, Seidu A. Richard, Xiao Dong Xie.

#### References

- Briganti F, Tedeschi E, Leone G, et al. Endovascular treatment of vertebro-vertebral arteriovenous fistula: a report of three cases and literature review. *Neuroradiol J* 2013;26:339–46.
- Mitchell P, Thomas P, Anderson D. Spontaneous resolution of a non-traumatic vertebro-vertebral arteriovenous fistula in a paediatric patient. *J Clin Neurosci* 2018;53:220–2.
- Zhong H, Shao G. Vertebral arteriovenous fistula. *J Vasc Surg* 2011; 53:492.
- Adams A, Allouni K, Basheer S, et al. Case report: spontaneous resolution of an established iatrogenic vertebral arteriovenous fistula. *J Child Neurol* 2013;28:255–8.
- Beaujeux R, Reizine D, Casasco A, et al. Endovascular treatment of vertebral arteriovenous fistula. *Radiology* 1992;183:361–7.
- Stuhlfaut JW, Barest G, Sakai O, et al. Impact of MDCT angiography on the use of catheter angiography for the assessment of cervical arterial injury after blunt or penetrating trauma. *Am J Roentgenol* 2005; 185:1063–8.
- Goyal M, Willinsky R, Montaner W, et al. Spontaneous vertebrovertebral arteriovenous fistulae clinical features, angioarchitecture and management of twelve patients. *Interv Neuroradiol* 1999;5: 219–24.
- Bahar S, Chiras J, Carpena J, et al. Spontaneous vertebro-vertebral arterio-venous fistula associated with fibro-muscular dysplasia. *Neuroradiology* 1984;26:45–9.
- Lasjaunias P. Vascular diseases in neonates, infants and children: interventional neuroradiology management. *Eur Radiol* 1998; 8: 193–.
- Moret J, Lasjaunias P, Doyon D. Occipital approach for treatment of arteriovenous malformation of the vertebral artery by balloon occlusion. *Neuroradiology* 1979;17:269–73.
- Olson RW, Baker HL Jr, Svien HJ. Arteriovenous fistula: a complication of vertebral angiography: report of a case. *J Neurosurg* 1963;20:73–5.

- [12] Modi M, Bapuraj JR, Lal A, et al. Vertebral arteriovenous fistula presenting as cervical myelopathy: a rapid recovery with balloon embolization. *Cardiovasc Interv Radiol* 33 2010;1253–6.
- [13] Sadato A, Satow T, Ishii A, et al. Large vertebral arteriovenous fistula treated with stent-grafts. *Neurol Med Chir* 2003;43:250–4.
- [14] Surber R, Werner GS, Cohnert TU, et al. Recurrent vertebral arteriovenous fistula after surgical repair: treatment with a self-expanding stent-graft. *J Endovasc Ther* 2003;10:49–53.
- [15] Briganti F, Tortora F, Marseglia M, et al. Covered stent implantation for the treatment of direct carotid-cavernous fistula and its mid-term follow-up. *Interv Neuroradiol* 2009;15:185–90.
- [16] Reddy M, Schogge A, Saringer W, et al. Traumatic arteriovenous fistula of the vertebral artery. *Neurol Med Chir* 2002;42:289–92.
- [17] Yeh C-H, Chen Y-L, Wu Y-M, et al. Anatomically based approach for endovascular treatment of vertebro-vertebral arteriovenous fistula. *Interv Neuroradiol* 2014;20:766–73.