

Available online at www.sciencedirect.com

ScienceDirect

journal homepage: www.elsevier.com/locate/radcr

Case report

Novel radiographic presentation of primary syphilis of the tonsil

Garrett Camps, BEng*, Cole Pavelchek, BS, Rami Eldaya, MD, Matthew Parsons, MD

Mallinckrodt Institute of Radiology, Washington University School of Medicine, St Louis, Missouri

ARTICLE INFO

Article history:

Received 3 May 2021

Revised 16 July 2021

Accepted 17 July 2021

Available online 26 August 2021

Keywords:

Primary Syphilis

Tonsil

Chancre

Treponema pallidum

ABSTRACT

A 61-year-old HIV+ male presented to an infectious disease clinic with a complaint of sore throat. A painless ulcerated mass was discovered on the right tonsil resulting in further evaluation with a CT scan of the neck. Imaging confirmed the presence of a mass centered on the palatine tonsil and associated lymphadenopathy. A presumptive diagnosis of HPV-related squamous cell carcinoma was made due to patient risk factors. However, multiple biopsies found no evidence of carcinoma, but instead revealed the presence of spirochetes that stained positive for *T Pallidum*. Soon after, the patient developed the characteristic copper-red maculopapular rash of secondary syphilis, indicating that the tonsillar mass was, in fact, a primary chancre. Since such chancres are most often found externally in the genital or anal region, they are seldom radiographically characterized, placing them low on the differential diagnosis for most radiologists. A high index of suspicion could aid future radiologists in placing primary syphilis higher on the differential diagnosis in similar cases in which the patient has appropriate risk factors, such as a known history of genital-oral sexually transmitted infections or an immunocompromised state. Prompt recognition of the nature of a primary syphilitic lesion can lead to rapid resolution of symptoms following treatment with intramuscular benzathine penicillin G, as eventually occurred in this case.

© 2021 The Authors. Published by Elsevier Inc. on behalf of University of Washington.

This is an open access article under the CC BY-NC-ND license (<http://creativecommons.org/licenses/by-nc-nd/4.0/>)

Introduction

The incidence of syphilis in the United States has been increasing over the past 20 years. Therefore, physicians need to be aware of alternative presentations of this classic disease [1]. Syphilis, caused by the spirochete, *Treponema pallidum*, is primarily a sexually transmitted infection (STI), but can be vertically transmitted in pregnant patients as well. It generally presents as primary or secondary syphilis, but it

can later progress to latent and tertiary syphilis (Table 1). Primary syphilis presents with a painless papule that then develops into a painless ulcerated chancre at the site of inoculation, typically around 2-6 weeks following the infection [2]. These are found in the genital region (85%), the anus (10%), or the oral mucosa near the lips (4%) [3]. The chancre resolves without treatment, and 6-8 weeks following the initial infection, secondary syphilis will present, characterized by headache, fever, and a generalized maculopapular rash affecting the palms and soles. If syphilis is left untreated, then

* Corresponding author.

E-mail address: garrett.camps@wustl.edu (G. Camps).

<https://doi.org/10.1016/j.radcr.2021.07.047>

1930-0433/© 2021 The Authors. Published by Elsevier Inc. on behalf of University of Washington. This is an open access article under the CC BY-NC-ND license (<http://creativecommons.org/licenses/by-nc-nd/4.0/>)

Table 1 – Manifestations of syphilitic disease.

Syphilitic stage	Timeframe post-inoculation	Symptoms
Primary	3 - 90 days	One or more papules that are usually painless. Papules rapidly progress to chancres, which are painless ulcers measuring 1 to 2 cm with raised, indurated margins. Ulcers typically have non-exudative bases. Lesions occur at the site of primary inoculation and heal within 3 to 6 weeks. Mild to moderate regional painless lymphadenopathy located near the chancre, typically bilateral. [4]
Secondary	2 - 12 weeks	Skin (diffuse, symmetrical maculopapular copper-red rash, typically involving the trunk and extremities, including the palms and soles) Constitutional (fever, anorexia, sore throat, weight loss, malaise, myalgias) Condyloma lata Ocular (uveitis, iritis, optic neuritis) Oral gray-white pseudomembranes with surrounding erythema Periostitis Arthritis Hepatitis Alopecia Glomerulonephritis Gastrointestinal ulcerations Neurological (meningitis, cerebrovascular accident, headache, cranial nerve palsy) Lymphadenopathy [4]
Latent – early	< 1 year	Asymptomatic [5]
Latent – late	> 1 year	Asymptomatic [5]
Tertiary	1 - 50 years	Gummatous lesions Cardiovascular Neurological (paresis, tabes dorsalis) [5]

there can be a period in which the treponemes are present but inactive, termed latent syphilis, during which patients will remain positive in serologic tests [4]. Years later, complications of tertiary syphilis may develop with a wide range of presentations due to its disseminated nature. These manifestations are broadly damaging and potentially life-threatening; they can range from neurosyphilis to cardiac syphilis to bony granulomatous lesions termed gummas. However, proper recognition and treatment of primary or secondary syphilis with benzathine penicillin can prevent these more severe disease manifestations from occurring, so early detection is essential [5]. Radiologically, secondary and tertiary syphilis manifestations are seen frequently, but primary syphilis typically presents as an external lesion that is identified on a physical exam without a need for imaging. However, although exceedingly rare, primary syphilitic chancres also have the potential to present in atypical locations such as the tonsils, a presentation which has been reported less than 10 times in existing literature and has yet to be characterized radiographically [3,4,6]. We present a case of a patient who presented with primary syphilitic chancre of the tonsil, characterized by computed tomography (CT) imaging with intravenous contrast.

We present a case of a primary syphilitic chancre that developed in a tonsillar location, a rarely reported occurrence referenced less than 10 times in the literature. In addition, for the first time reported in literature for this location [3,4,6], a primary chancre was radiographically characterized. Due to the rarity of such radiologic characterization and the potential for a chancre to mimic other diseases, we were compelled to write this case report.

Case report

A 61-year-old Human Immunodeficiency Virus positive (HIV+) Caucasian male with a prior history of resolved syphilis presented to the Infectious Disease clinic with a sore throat and approximately one week of worsening symptoms. He was previously seen at urgent care and prescribed an unknown antibiotic, which did not alleviate his symptoms. Physical exam was significant for an ulcerative mass involving the right tonsil. Physical exam also noted a fixed, rigid, painless right neck mass. The patient denied dysphagia, odynophagia, shortness of breath, weight loss, or voice changes.

This patient has a history of HIV diagnosed in 1997, which is currently well controlled on Truemeq. In 2016, he had Burkitt Lymphoma of the cecum which was successfully treated with chemotherapy. In early 2019, the patient was asymptomatic, but tested RPR positive after a partner's syphilis diagnosis prompted a test; subsequent treatment with bicillin rendered him RPR and treponemal antibody negative. The patient has a 25 pack year smoking history but quit in 2013. At presentation, the patient denied having any recent sexual activity and declined STI screening; the patient is male and preferred sexual partners are male when active. Due to the history of Burkitt lymphoma and the fixed and rigid nature of the lymphadenopathy, there was a concern for malignancy. A neck computed tomography (CT) scan with intravenous contrast was performed for further evaluation.

The CT scan showed a 2.4 cm × 1.3 cm lesion centered on the right palatine tonsil, including the anterior tonsillar pil-

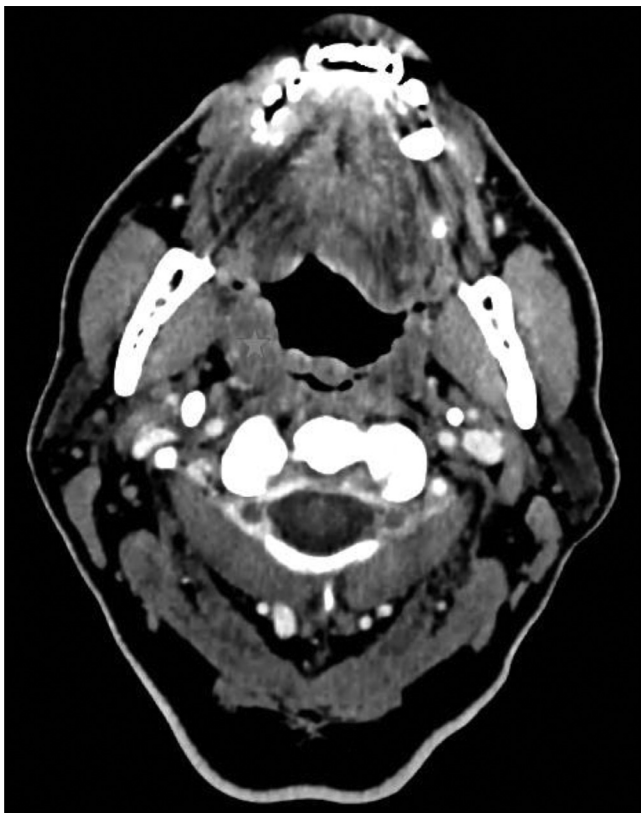


Fig. 1 – Axial neck CT scan with IV contrast approximately 17 days following reported symptom onset. Demonstrates enlargement of the right palatine tonsil (blue star).

lar, with a mild extension onto the glossotonsillar sulcus and lateral base of the tongue. Bilateral cervical lymphadenopathy was also seen on the right at levels 2A, 2B, and 3, and on the left at levels 2A and 4. Given the patient's age, smoking and sexual history, the ulcerated appearance of the tonsillar mass, and the anatomic location, the lesion and lymphadenopathy were presumed to likely be Human Papilloma Virus positive (HPV+) metastatic squamous cell carcinoma. Given his history of Burkitt lymphoma, lymphoma was also considered a possibility. No acute intracranial abnormalities were noted.

The patient presented a few weeks later with a one-week history of pinkish/red spots on his hands, arms, chest, stomach, and legs. The onset of this rash was approximately 3.5 weeks after the beginning of the sore throat. The spots varied in size (0.5 cm - 1.0 cm) and were neither pruritic nor painful. The patient reported no recent unprotected sex, and a sexually transmitted infection was not suspected. The patient noted that he began using Lysol wipes around the time of rash onset and was told to stop using the wipes and take loratadine. Approximately one week later, the rash resolved.

As discussed previously, the patient's neck CT scans were concerning for metastatic cancer, most likely HPV+ oropharyngeal squamous cell carcinoma. The patient was referred to radiology for an ultrasound-guided fine needle aspiration biopsy of his right cervical lymph node and a chest CT to check for possible lung metastases and complete staging. The chest CT with Intravenous (IV) contrast did not show any definite ev-

idence of metastatic cancer within the chest. The ultrasound-guided fine needle aspiration biopsy of the right cervical lymphadenopathy was inconclusive and did not show evidence of either squamous cell carcinoma or lymphoma. The ultrasound was followed by tonsillar biopsy of the presumed primary lesion. The tonsil biopsy showed benign squamous mucosa with reactive follicular hyperplasia. It did not show evidence of squamous cell carcinoma or lymphoma.

Despite negative tissue biopsies, clinical concern for malignancy remained high and more definitive tissue sampling was performed via laryngoscopy. This biopsy showed benign squamous mucosa with reactive lymphoid follicular hyperplasia and no evidence of squamous cell carcinoma or lymphoma. However, because this was a repeat biopsy, a more extensive panel of stains was used, resulting in the identification of numerous spirochete organisms staining positive for *T. pallidum* in the ulcerated mucosa, consistent with active syphilis infection. The patient was treated with a single intramuscular injection of penicillin G benzathine (Bicillin). The ulcer on his tonsil was determined to likely have been his primary chancre as there were no genital or anal lesions reported. The patient's rapid plasma reagin (RPR) and Treponemal IgG/IgM were reactive, with an RPR titer of 1:512, confirming the diagnosis. A repeat RPR drawn four months later was reactive with a significantly decreased titer of 1:16, ensuring resolution of infection in conjunction with symptomatic resolution on physical exam.

Discussion

Syphilis is caused by a spirochete, *Treponema pallidum*, and is typically transmitted via direct sexual contact, although it can also spread vertically through the placenta. Transmission of *T. pallidum* through sexual contact requires direct exposure to an open lesion with *T. pallidum* organisms present, such as the primary chancre or condyloma lata. These lesions are highly infectious, with a transmission rate following exposure estimated at 30% [7]. Syphilis can present clinically in several stages; primary, secondary, and tertiary. Primary syphilis is characterized by a solitary or multiple painless papule(s) that develop into an ulcerated chancre with induration, often with associated lymphadenopathy in the surrounding region. This is most common in the genital or anal area; however, a small number of patients develop a primary oral chancre. The most common locations for an oral chancre are the tongue, gingiva, soft palate, and lips [2]; however, rarer hard palate and tonsillar lesions have also been reported [3,4]. Regardless of the location, this phase is self-limiting, ending with spontaneous healing of the chancre as the organisms are phagocytosed by macrophages, and the infection is mostly cleared. However, during this process, a few spirochetes can escape into the bloodstream and seed the subsequent secondary infection [2].

Secondary syphilis typically appears 4-10 weeks after primary syphilis. In rarer cases, it can be concurrent with primary symptoms, especially in immunocompromised hosts. It occurs when the hematogenous spread of treponemes results in a disseminated spread of the infection to multiple locations throughout the body. These treponemes multiply and

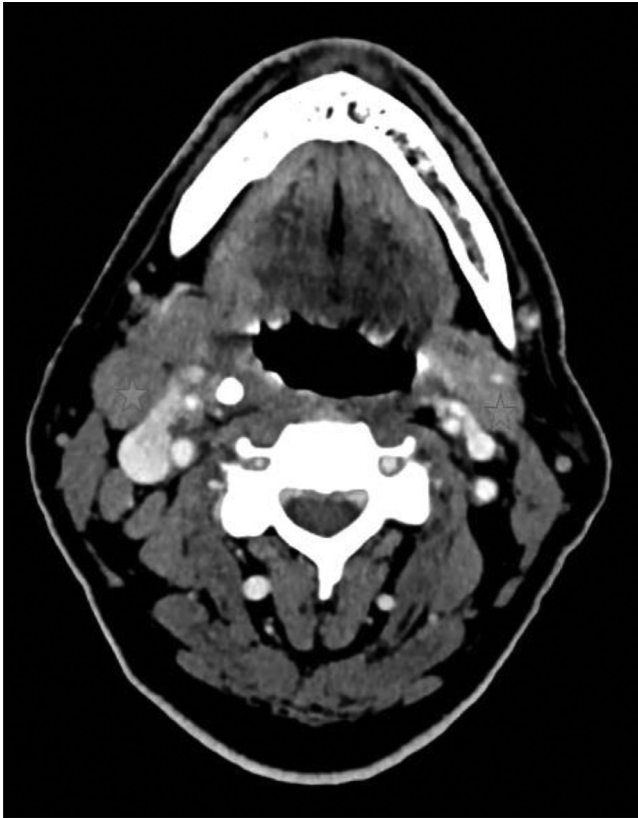

Fig. 2 – Axial neck CT scan with IV contrast approximately 17 days following reported symptom onset. Demonstrates bilateral upper jugulodigastric lymphadenopathy (blue stars).

induce an immune response causing systemic symptoms, including headache, a generalized rash that commonly affects the palms and soles, malaise, pyrexia, and condyloma lata. The rash is the most common symptom, occurring in 90% of patients and often beginning as a copper-red macular rash before the papules develop [5]. Lymphadenopathy and a painful sore throat can also develop with secondary syphilis but are less common symptoms [2]. Secondary syphilis will also resolve without treatment; however, approximately one-quarter of patients will develop a recurrence in 4 years if untreated [5]. Finally, if treatment has not been pursued with curative antibiotics, tertiary syphilis can occur years after primary syphilis. Any organ or tissue can be invaded by the treponemes and cause inflammation due to the hypersensitivity response. This results in the formation of gummas, which are granulomatous lesions in the skin, mucosa, and bone, as well as neurosyphilis and cardiovascular syphilis [5].

In high socioeconomic regions such as the United States and Europe, the increase in syphilis has been primarily concentrated in high-risk populations. One such group is men who have sex with men. There is a higher rate of coinfection of syphilis and HIV than in the general population, putting them more at risk for unusual presentations and faster disease progression [1]. In this case, a patient with well-controlled HIV de-

veloped a primary chancre on the tonsil, which went unrecognized until multiple biopsies ruled out the initial suspected diagnosis of squamous cell carcinoma. HPV+ squamous cell carcinoma was initially highest on the differential diagnosis secondary to the patient's smoking history, prior history of STI's, age and the ulcerated nature of the lesion. However, the presence of the maculopapular rash along with a painless ulcerated lesion should have placed syphilis higher on the differential. There were factors leading away from a syphilis diagnosis as well, such as the unusual location of the chancre and the patient reporting no recent sexual activity, which likely referred to no recent genital-anal sexual activity. In addition, the patient had previously been infected with syphilis which may place it lower on the differential, however prior infection with syphilis does not confer full immunity, and the patient was in an immunocompromised state during the infection. Finally, while several cases similar to this have been reported in the literature, none have been radiographically characterized, making the appearance relatively novel [3,4,6]. This is an interesting case radiologically because primary syphilis rarely appears on imaging. While distantly on the differential diagnosis for most patients with a tonsillar lesion of this type on CT, a history of syphilis or other sexually transmitted infections and an immunocompromised state should place a primary syphilitic chancre on the differential and prompt a biopsy or RPR. Providers should keep in mind the increase in genital-oral sexual practices when questioning the sexual history of patients in whom sexually transmitted infections are suspected and remember that the primary chancre of syphilis can appear in unusual oral locations.

Conclusion

The incidence of primary syphilis has been increasing in wealthy countries and is mainly concentrated in high-risk groups. In this case, a patient presented with a primary syphilitic chancre that had developed as a painless ulcerated mass on the right tonsil with associated cervical lymphadenopathy. Prior to this case, this diagnosis in this location had not been characterized radiographically. Specifically, a CT scan enabled a radiographic characterization of the lesion as a mildly enhancing mass partially narrowing the oropharynx, and the presence of syphilis was confirmed on biopsy. In light of this case, radiologists should include syphilis in the differential diagnosis in certain clinical scenarios. In doing so, radiologists can assist in expediting treatment of patients such as this who rapidly improve following the administration of benzathine penicillin Figs. 1 and 2.

Consent Statement

No consent obtained for this case report as this is a retrospective study with no patient identifiers. "Formal consents are not required for the use of entirely anonymized images from which the individual cannot be identified - for example, X-rays, ultrasound images, pathology slides or laparoscopic im-

ages, provided that these do not contain any identifying marks and are not accompanied by text that might identify the individual concerned.”

Declaration of interests

The authors declare that they have no known competing financial interests or personal relationships that could have appeared to influence the work reported in this paper.

REFERENCES

- [1] Kidd S, Torrone E, Su J, Weinstock H. Reported Primary and Secondary Syphilis Cases in the United States: Implications for HIV Infection. *Sex Transm Dis* Sep 2018;45(9S Suppl 1):S42–7 PMID: 29465633; PMCID: PMC6745698. doi:[10.1097/OLQ.0000000000000810](https://doi.org/10.1097/OLQ.0000000000000810).
- [2] Ficarra G, Carlos R. Syphilis: the renaissance of an old disease with oral implications. *Head and Neck Pathology* Sep 2009;3(3):195–206. doi:[10.1007/s12105-009-0127-0](https://doi.org/10.1007/s12105-009-0127-0).
- [3] Lobato-Berezo A, Imbernon-Moya A, Martinez-Perez M, Churruca-Grijelmo M, Vargas-Laguna ME, Fernandez-Cogolludo E, Aguilar-Martinez A, Gallego-Valdes MA. Tonsillar chancre as unusual manifestation of primary syphilis. *Dermatol Online J* 2015 Apr 16;21(4) 13030/qt6gn70381. PMID: 25933085.
- [4] Streight KL, Paranal RM, Musher DM. The oral manifestations of syphilitic disease: a case report. *J Med Case Rep* 2019 Jul 26;13(1):227 PMID: 31345262; PMCID: PMC6659237. doi:[10.1186/s13256-019-2171-z](https://doi.org/10.1186/s13256-019-2171-z).
- [5] Golden MR, Marra CM, Holmes KK. Update on Syphilis: Resurgence of an Old Problem. *JAMA* 2003;290(11):1510–14. doi:[10.1001/jama.290.11.1510](https://doi.org/10.1001/jama.290.11.1510).
- [6] Fiumara NJ, Berg M. Primary syphilis in the oral cavity. *Br J Vener Dis* Dec 1974;50(6):463–4 PMID: 4217210; PMCID: PMC1045088. doi:[10.1136/sti.50.6.463](https://doi.org/10.1136/sti.50.6.463).
- [7] ROCKWELL DH, YOBS AR, MOORE MB. The Tuskegee Study of Untreated Syphilis: The 30th Year of Observation. *Arch Intern Med* 1964;114(6):792–8. doi:[10.1001/archinte.1964.03860120104011](https://doi.org/10.1001/archinte.1964.03860120104011).