



## Clinical Studies

# Is it mandatory to routinely use image intensifier during scoliosis surgery? – Results of an email survey



Devi Prakash Tokala\*, Sashin Ahuja

Welsh Centre for Spinal Surgery &amp; Trauma, University Hospital of Wales, Heath Park, Cardiff, CF14 4XW, United Kingdom

## ARTICLE INFO

## Keywords:

Scoliosis surgery  
Image intensifier  
Email survey  
Scoliosis spine surgeons  
Fluoroscopy  
Medico-legal

## ABSTRACT

**Background:** It is now considered standard of care to use Spinal cord monitoring during scoliosis surgery. Use of Image intensifier during scoliosis surgery, on the other hand, is highly variable in United Kingdom (UK) spine centres. Our objective was to evaluate the use of image intensifier during scoliosis surgery in UK spine centres.

**Methods:** Ninety three British scoliosis spine surgeons were invited to complete a survey via email using Survey Monkey platform. Surgeons were asked about the routine use of image intensifier during scoliosis surgery, including the reasons for using it and if, in their opinion, routine use is medico-legally mandatory.

**Results:** Thirty four Spine surgeons replied (response rate of 36.5%). Among these 85% have been consultants for at least 5 years. 91% performed more than 10 paediatric scoliosis operations per annum and 53% performed more than 30 operations per annum. 68% always routinely use image intensifier during scoliosis surgery while 21% do not use it routinely. However 66% mentioned that in their opinion, it is not medico-legally mandatory to use the Image intensifier during scoliosis surgery and that routine use should be left to the discretion of the operating surgeon.

**Conclusions:** Although majority of the United Kingdom spine surgeons, who responded to this survey, routinely use image intensifier during scoliosis surgery, they agree that it is not medico-legally mandatory to routinely use the image intensifier.

## Introduction

It is now considered standard of care to use Spinal cord monitoring during scoliosis surgery [1–3]. Use of Image intensifier during scoliosis surgery, on the other hand, is highly variable in United Kingdom (UK) spine centres. Our objective was to evaluate the use of image intensifier during scoliosis surgery in the UK spine centres.

## Materials and methods

An online survey was developed using Survey Monkey platform and 93 spine surgeons registered on the British scoliosis society membership database were invited to participate in this survey via email, which included a background summary and the aims of this study. The following questions were included in the survey:

Q1: Do you routinely use Image Intensifier during scoliosis surgery?

- a) No
- b) Yes, always

- c) Yes, sometimes

Q2: Is the image intensifier used to identify the pedicles and aid the insertion of screws?

- a) Yes
- b) No

Q3: Is the image intensifier used only to check the position of the screws after insertion of the screws free hand?

- a) Yes
- b) No

Q4: In your opinion – is the use of image intensifier during scoliosis surgery:

- a) Medico legally mandatory
- b) Not mandatory

Q5: Please add comments below

Q6: Your details (name)

Q7: Number of years as a consultant

DOI of original article: [10.1016/j.xnsj.2020.100027](https://doi.org/10.1016/j.xnsj.2020.100027)

\* Corresponding author.

E-mail address: [dptokala@aol.com](mailto:dptokala@aol.com) (D.P. Tokala).

<https://doi.org/10.1016/j.xnsj.2020.100024>

Received 5 July 2020; Received in revised form 1 September 2020; Accepted 3 September 2020

Available online 9 September 2020

2666-5484/Crown Copyright © 2020 Published by Elsevier Ltd on behalf of North American Spine Society. This is an open access article under the CC BY-NC-ND license (<http://creativecommons.org/licenses/by-nc-nd/4.0/>)

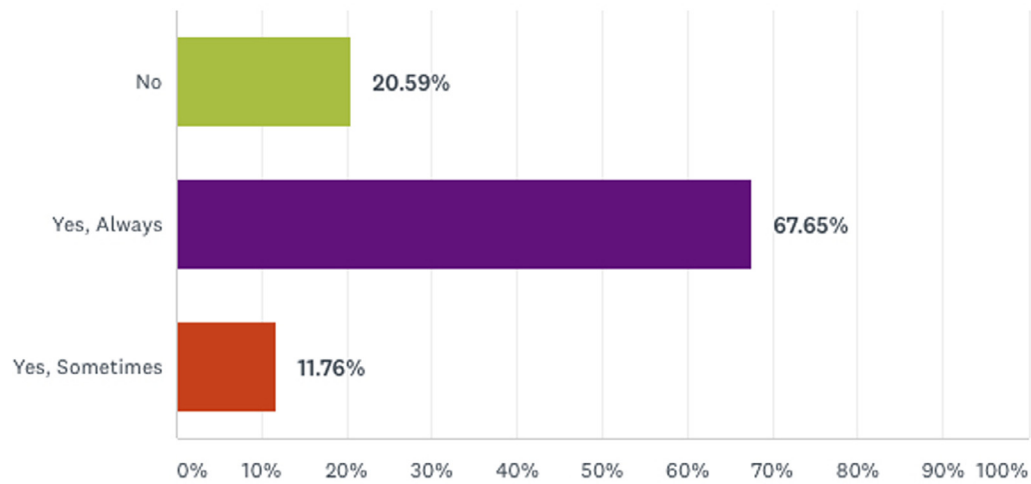


Fig. 1. Q1: Do you routinely use Image Intensifier during scoliosis surgery?

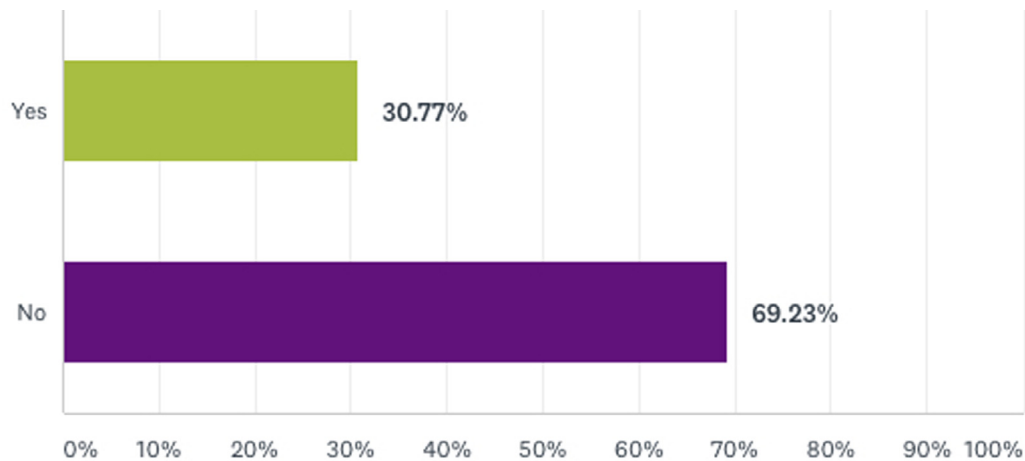


Fig. 2. Q2: Is the image intensifier used to identify the pedicles and aid the insertion of screws?

Q8: How many paediatric scoliosis operations do you perform approximately per annum?

- Less than 10
- 10–30
- 30–50
- more than 50

Q9: How many adult scoliosis operations do you perform approximately per annum?

- Less than 10
- 10–30
- 30–50
- more than 50

Respondents were also asked to document any rationale underpinning their responses. The authors collated data and the Survey monkey platform was used to prepare the charts.

## Results

Thirty four Spine surgeons replied (response rate of 36.5%). 68% of the surgeons who replied, always routinely use image intensifier during scoliosis surgery while 21% do not use it routinely [Figure 1](#). However

66% mentioned that in their opinion, it is not medico-legally mandatory to use the Image intensifier during scoliosis surgery and that routine use should be left to the discretion of the operating surgeon [Figure 4](#). Image intensifier was used to identify the pedicles by 31% of the respondents [Figure 2](#), while 65% used it to check the position after insertion of the screws free hand [Figure 3](#). Among these 85% have been consultants for minimum 5 years, 91% performed more than 10 paediatric scoliosis operations per annum [Figure 5](#), and 73% performed more than 10 adult scoliosis operations per annum [Figure 6](#).

Open-ended comments were collected via question 5, 38% of the respondents added free text comment. Few of the illustrative examples are as follows:

- Confirms acceptable screw placement, correct levels instrumented and gives an idea of balance of correction.
- With respect to Q2 and 3 my routine is to insert screws freehand and then image, but if the pedicles are difficult then I will use the II to find the pedicle.
- The use will depend on types of curve; and complexity of curves. Usually for identification of pedicles and to check screw placement.
- Difficult to check levels and satisfactory hardware placement/reduction without Imaging of some sort. II or plain X-ray or CT all will work.
- It needs to be used as a minimum to check the levels of the surgery.

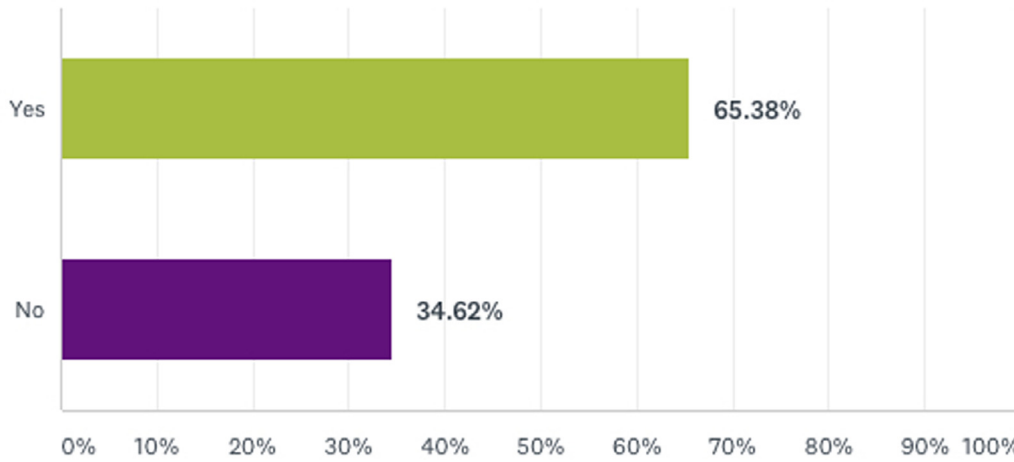


Fig. 3. Q3: Is the image intensifier used only to check the position of the screws after insertion of the screws free hand?

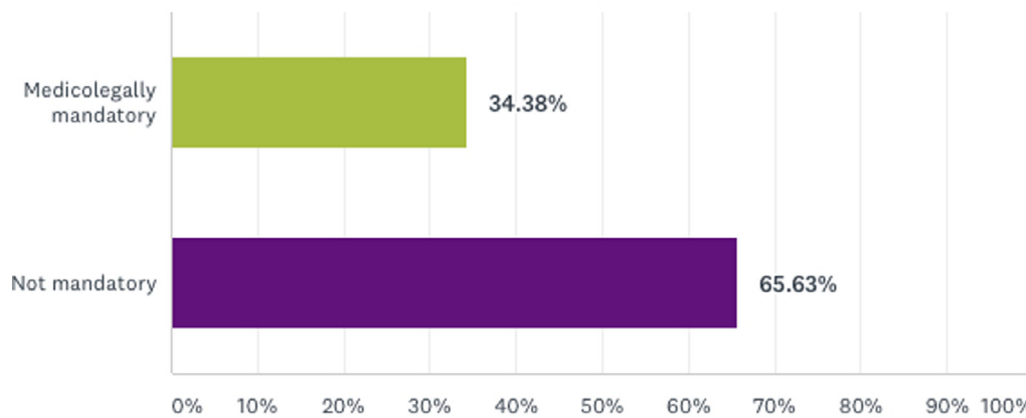


Fig. 4. Q4: In your opinion – is the use of image intensifier during scoliosis surgery:

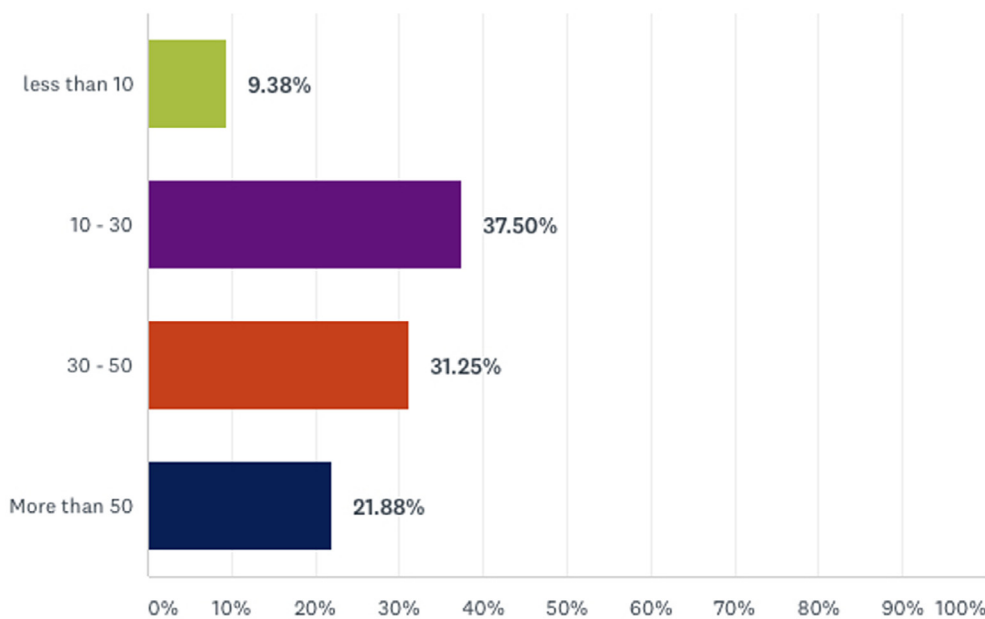


Fig. 5. Q8: How many paediatric scoliosis operations do you perform approximately per annum?

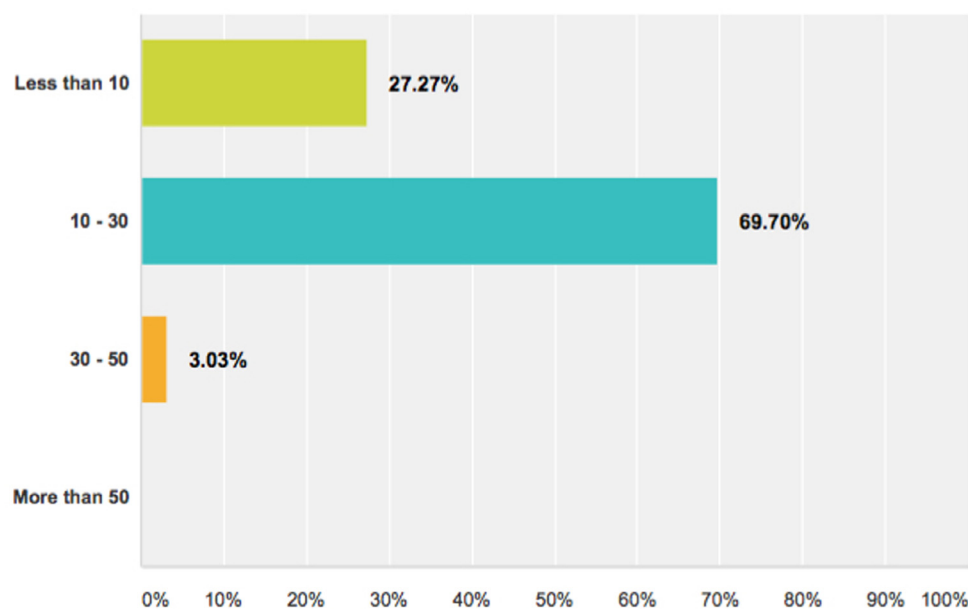


Fig. 6. Q9: How many adult scoliosis operations do you perform approximately per annum?

- Level check is mandatory. Accurate placement of screws is essential. How the surgeon does it depends on the individuals ability and training.

## Discussion

Scoliosis surgery is performed to achieve balanced spine over horizontal pelvis (in both coronal and sagittal planes) and solid fusion with good correction of the deformity. Spinal instrumentation to achieve few of these goals has evolved over the past 40 years from Harrington rod construct to current hook/screw hybrid construct or pedicle screw only constructs [4–6].

Advantages of pedicle screws include good three-column purchase, segmental fixation allows derotation, leading to better correction of scoliosis without intruding the spinal canal. Pedicle screw instrumentation also enables slightly shorter fusion length and decreases the incidence of pseudarthrosis and implant failure [4,6–8]. However there remains potential for severe complications, if there is a breach of the pedicles, causing injury to the spinal cord, nerves, and important vascular structures. Screw misplacement can also weaken reduction and fixation, requiring revision surgery [5,9,10].

In order to improve accuracy of pedicle screw insertion, image intensifier has been used during scoliosis surgery [6,11]. Image intensifier also helps to confirm the levels of instrumentation, magnitude of curve correction and balance obtained [6].

There are differing opinions as to what constitutes the best practice. Pedicle screw insertion with [6,11] or without image intensifier [9,12], long-cassette intraoperative scoliosis films [8], CT based [11,13] or intraoperative fluoroscopy based navigation [7] has been used to confirm that the above aims have been achieved during scoliosis operation.

Majority of the spinal surgeons continue to use the free hand technique and may use image intensifiers as a method of confirmation of screw position rather than as a guidance tool [9,12,14]. The neurological complication rate was found to be similar in the studies using CT navigation, free-hand technique and fluoroscopy [12,15]. The use of free-hand technique for pedicle screw fixation, requires minimum amount of fluoroscopic use, thus decreasing radiation exposure to the surgeon and the patient in spinal deformity correction operations [12,16].

It is widely accepted that radiation safety must be a priority in the operative setting [17]. Mastrangelo et al. [18] reported that working as an orthopaedic surgeon was a significant risk factor for tumour develop-

ment in a survey of cancer incidence amongst 316 hospital employees. Similarly Chou et al. [19] reported that female orthopaedic surgeons in their study had a 2.9-fold higher prevalence of breast cancer compared to the general U.S. female population. Simony et al. [20] reported higher incidence of endometrial and breast cancer in adolescent idiopathic scoliosis (AIS) cohort compared to the age matched population in Denmark. Presciutti et al. [21] reported that surgically treated patients received significantly greater average annual radiation doses than braced or observed AIS patients with operative patients receiving approximately 8 to 14 times more radiation than braced patients or those undergoing observation alone, respectively.

The rates of misplaced pedicle screws using the free-hand technique range from 2% to 43% [7,15,22]. Computer-assisted or fluoroscopy assisted navigation has been on the rise in an attempt to obviate the chance of pedicle screw malpositioning [7,11]. Revision surgery following conventional technique has been reported ranging from 0.21% to 7%, while computer assisted surgery (CAS) group did not have any revision operations [9,11,12].

Increased setup time and registration-related errors are a drawback to the first generation CT-based navigation systems, which rely on acquired data before surgery. The change in the intervertebral anatomic relationship in prone position compared to supine preoperative films was also reported with navigation systems using preoperative CT scans [7]. The intraoperative CT/MRI based navigation systems are more accurate but not widely available due to the unacceptably high cost. They also occupy more space in the operating room and need a specific compatible operating table with their use. On the other hand, with intraoperative imaging modality of fluoroscopy based navigation systems, data is acquired intraoperatively after patient positioning and imported to a computer navigation system. The real-time images avoid the registration-related errors and shorten the surgical time. Rajashekar et al. [7] reported that Iso-C navigation increases accuracy, reduces surgical time and radiation in thoracic deformity correction surgeries. Similarly, Watkins et al. [23] reported that intraoperative fluoroscopy based navigation for the placement of pedicle screws may be cost effective in spine practices with heavy volume, that perform surgery in difficult cases and that radiation exposure to the surgeon per case is negligible.

Hartl et al. [24] reported in their survey based study of world-wide AO spine surgeons that 75% of the survey population considered Computer assisted surgery (CAS) improves accuracy, potentially makes complex surgery safer, and possibly reduces radiation. High costs, the lack of CAS equipment, increase in operating room (OR) time, and no or

inadequate training were quoted as the important reasons for not using CAS at all or more often by 52–73% of all surgeons.

In our survey of British scoliosis spine surgeons, 68% of the surgeons who replied, always routinely use image intensifier during scoliosis surgery. This was used to identify the pedicles by 31% of the respondents, whilst 65% used it to check the position after insertion of the screws free hand. We agree that due to the limited response rate of 36.5%, the generalisability of these findings is limited and definitive recommendations based on this survey cannot be made. We also understand that some spine surgeons who routinely use intraoperative fluoroscopy (IOF) may choose to state that IOF should not be medicolegally mandatory for various reasons including personal aversion to malpractice litigation. Successful malpractice lawsuits are based on various factors including particularities of specific cases, on expert opinions and jury perceptions of the presence of a deviation from the standard of care during trial. New technologies by their very nature can become a particular attraction for litigation until they become common usage and have established standards. Standard of care (Good practise) can be turned on its head by the concept of defensive medicine, which is the practice of utilising medical technologies, not because they make healthcare safer, but because they ward off medical malpractice litigation.

Despite a generally reported low clinically important complication rate using a freehand technique [12], CT or fluoroscopy based navigation systems are increasingly being used to increase the accuracy of screw insertion. However, the justification for increased accuracy at the expense of increased cost and radiation exposure to the patient remains debatable. Urbanski et al. [13] reported that patients with moderate idiopathic scoliosis undergoing primary surgery experienced increased radiation without any benefit of pedicle screw accuracy.

Chan et al. [10] in their systematic review found that current evidence is limited by small sample sizes, lack of comparison groups, and poorly predefined complications. They recommended randomised controlled trials with larger samples with standardised definitions and recording of predefined breach and complication occurrences.

## Conclusion

Although majority of the United Kingdom spine surgeons, who responded to our survey, routinely use image intensifier during scoliosis surgery, they agree that it is not medico-legally mandatory to routinely use the image intensifier.

## Declaration of Competing Interest

The authors declare that they have no known competing financial interests or personal relationships that could have appeared to influence the work reported in this paper.

## Sources of financial support

None.

## Author contributions

DPT conducted the study, analysed the data, presented in the national meeting and prepared the manuscript.

SA is the senior author, he recommended and supervised the study & improved the manuscript.

Both authors have read, reviewed and approved the article.

Both authors believe that the manuscript represents honest work.

## Approval code

N/A.

## Acknowledgements

None.

Social media summary sentence

Survey of UK spine surgeons, reveals that majority of them routinely use image intensifier during scoliosis surgery, however, they agree that it is not medico-legally mandatory to routinely use the image intensifier.

## Previous publication

Authors confirm that this study was presented as a poster in a national meeting in Sheffield, UK (British Scoliosis Society, April 2015) and the abstract has been published as a proceeding in The Spine Journal, Volume 16, Issue 4, Supplement, Pages S110–S111.

([https://www.thespinejournalonline.com/article/S1529-9430\(15\)01925-7/fulltext](https://www.thespinejournalonline.com/article/S1529-9430(15)01925-7/fulltext))

## Supplementary materials

Supplementary material associated with this article can be found, in the online version, at doi:10.1016/j.xnsj.2020.100024.

## References

- [1] Bhagat S, Durst A, Grover H, Blake J, Lutchman L, Rai AS, Crawford R. An evaluation of multimodal spinal cord monitoring in scoliosis surgery: a single centre experience of 354 operations. *Eur Spine J* 2015;24(7):1399–407. doi:10.1007/s00586-015-3766-8.
- [2] Pastorelli F, Di Silvestre M, Plasmati R, Michelucci R, Greggi T, Morigi A, Bacchin MR, Bonarelli S, Cioni A, Vommaro F, Fini N, Lolli F, Parisini P. The prevention of neural complications in the surgical treatment of scoliosis: the role of the neurophysiological intraoperative monitoring. *Eur Spine J* 2011;20(Suppl 1):S105–14. doi:10.1007/s00586-011-1756-z.
- [3] Raw DA, Beattie JK, Hunter JM. Anaesthesia for spinal surgery in adults. *Br J Anaesth* 2003;91(6):886–904.
- [4] Kim YJ, Lenke LG, Cho SK, Bridwell KH, Sides B, Blanke K. Comparative analysis of pedicle screw versus hook instrumentation in posterior spinal fusion of adolescent idiopathic scoliosis. *Spine* 2004;29(18):2040–8.
- [5] Hicks JM, Singla A, Shen FH, Arlet V. Complications of pedicle screw fixation in scoliosis surgery: a systematic review. *Spine* 2010;35(11):E465–70. doi:10.1097/BRS.0b013e3181d1021a.
- [6] Suk SI, Kim JH, Kim SS, Lim DJ. Pedicle screw instrumentation in adolescent idiopathic scoliosis (AIS). *Eur Spine J* 2012;21(1):13–22. doi:10.1007/s00586-011-1986-0.
- [7] Rajasekaran S, Vidyadhara S, Ramesh P, Shetty AP. Randomized clinical study to compare the accuracy of navigated and non-navigated thoracic pedicle screws in deformity correction surgeries. *Spine* 2007;32(2):E56–64. doi:10.1097/01.brs.0000252094.64857.ab.
- [8] Lehman RA Jr, Lenke LG, Helgeson MD, Eckel TT, Keeler KA. Do intraoperative radiographs in scoliosis surgery reflect radiographic result? *Clin Orthop Relat Res* 2010;468(3):679–86. doi:10.1007/s11999-009-0873-z.
- [9] Parker SL, Amin AG, Santiago-Dieppa D, Liauw JA, Bydon A, Sciubba DM, Wolinsky JP, Gokaslan ZL, Witham TF. Incidence and clinical significance of vascular encroachment resulting from freehand placement of pedicle screws in the thoracic and lumbar spine: analysis of 6816 consecutive screws. *Spine* 2014;39(8):683–7. doi:10.1097/BRS.0000000000000221.
- [10] Chan A, Parent E, Narvacan K, San C, Lou E. Intraoperative image guidance compared with free-hand methods in adolescent idiopathic scoliosis posterior spinal surgery: a systematic review on screw-related complications and breach rates. *Spine J* 2017;17(9):1215–29. doi:10.1016/j.spinee.2017.04.001.
- [11] Amiot LP, Lang K, Putzier M, Zippel H, Labelle H. Comparative results between conventional and computer-assisted pedicle screw installation in the thoracic, lumbar, and sacral spine. *Spine* 2000;25(5):606–14.
- [12] Dede O, Ward WT, Bosch P, Bowles AJ, Roach JW. Using the freehand pedicle screw placement technique in adolescent idiopathic scoliosis surgery: what is the incidence of neurological symptoms secondary to misplaced screws? *Spine* 2014;39(4):286–90. doi:10.1097/BRS.0000000000000127.
- [13] Urbanski W, Jurasz W, Wolanczyk M, Kulej M, Morasiewicz P, Dragan SL, Zaluski R, Miekisiak G, Dragan SF. Increased radiation but no benefits in pedicle screw accuracy with navigation versus a freehand technique in scoliosis surgery. *Clin Orthop Relat Res* 2018;476(5):1020–7. doi:10.1007/s11999-000000000000204.
- [14] Karapinar L, Erel N, Ozturk H, Altay T, Kaya A. Pedicle screw placement with a free hand technique in thoracolumbar spine: is it safe? *J Spinal Disord Tech* 2008;21(1):63–7. doi:10.1097/BSD.0b013e3181453dc6.
- [15] Gelalis ID, Paschos NK, Pakos EE, Politis AN, Arnaoutoglou CM, Karageorgos AC, Ploumis A, Xenakis TA. Accuracy of pedicle screw placement: a systematic review of prospective in vivo studies comparing free hand, fluoroscopy guidance and navigation techniques. *Eur Spine J* 2012;21(2):247–55. doi:10.1007/s00586-011-2011-3.

- [16] Erken HY, Burc H, Saka G, Akmaz I, Aydoğan M. Can radiation exposure to the surgeon be reduced with freehand pedicle screw fixation technique in pediatric spinal deformity correction? A prospective multicenter study. *Spine* 2014;39(6):521–5. doi:[10.1097/BRS.000000000000172](https://doi.org/10.1097/BRS.000000000000172).
- [17] Narain AS, Hijji FY, Yom KH, Kudaravalli KT, Haws BE, Singh K. Radiation exposure and reduction in the operating room: Perspectives and future directions in spine surgery. *World J Orthop* 2017;8(7):524–30. doi:[10.5312/wjo.v8.i7.524](https://doi.org/10.5312/wjo.v8.i7.524).
- [18] Mastrangelo G, Fedeli U, Fadda E, Giovanazzi A, Scozzato L, Saia B. Increased cancer risk among surgeons in an orthopaedic hospital. *Occup Med* 2005;55(6):498–500. doi:[10.1093/occmed/kqi048](https://doi.org/10.1093/occmed/kqi048).
- [19] Chou LB, Chandran S, Harris AH, Tung J, Butler LM. Increased breast cancer prevalence among female orthopedic surgeons. *J Womens Health* 2012;21(6):683–9. doi:[10.1089/jwh.2011.3342](https://doi.org/10.1089/jwh.2011.3342).
- [20] Simony A, Hansen EJ, Christensen SB, Carreon LY, Andersen MO. Incidence of cancer in adolescent idiopathic scoliosis patients treated 25 years previously. *Eur Spine J* 2016;25(10):3366–70. doi:[10.1007/s00586-016-4747-2](https://doi.org/10.1007/s00586-016-4747-2).
- [21] Presciutti SM, Karukanda T, Lee M. Management decisions for adolescent idiopathic scoliosis significantly affect patient radiation exposure. *Spine J* 2014;14(9):1984–90. doi:[10.1016/j.spinee.2013.11.055](https://doi.org/10.1016/j.spinee.2013.11.055).
- [22] Belmont PJ Jr, Klemme WR, Robinson M, Polly DW Jr. Accuracy of thoracic pedicle screws in patients with and without coronal plane spinal deformities. *Spine* 2002;27(14):1558–66.
- [23] Watkins RG, Gupta A, Watkins RG. Cost-effectiveness of image-guided spine surgery. *Open Orthop J* 2010;4:228–33. doi:[10.2174/1874325001004010228](https://doi.org/10.2174/1874325001004010228).
- [24] Hartl R, Lam KS, Wang J, Korge A, Kandziora F, Audige L. Worldwide survey on the use of navigation in spine surgery. *World Neurosurg* 2013;79(1):162–72. doi:[10.1016/j.wneu.2012.03.011](https://doi.org/10.1016/j.wneu.2012.03.011).