

Pentalogy of Cantrell Associated with Ectopia Cordis: A Case Report

Muneer Fazea^{1,2}, Mansour Alhameli^{2,3}, Faisal Ahmed⁴, Mohammad Reza Askarpour⁵, Wafa Murshed², Azizh Jarwsh², Amal Alkbous²

¹Department of Radiology, School of Medicine, Ibb University of Medical Sciences, Ibb, Yemen; ²Department of Radiology, Al-Ma'amon Diagnostic Center, Sana'a, Yemen; ³Department of Radiology, Faculty of Medicine, Sana'a University of Medical Sciences, Sana'a, Yemen; ⁴Urology Research Center, Al-Thora General Hospital, Department of Urology, School of Medicine, Ibb University of Medical Sciences, Ibb, Yemen; ⁵Department of Urology, School of Medicine, Shiraz University of Medical Sciences, Shiraz, Iran

Correspondence: Faisal Ahmed, Al-Thora General Hospital, Alodine Street, Ibb, Yemen, Email fmaa2006@yahoo.com

Abstract: Pentalogy of Cantrell is a congenital anomaly of the median mesodermal constructions with a poor prognosis. It is characterized by defects of the anterior diaphragm, the lower sternum, the abdominal wall, pericardium, and various congenital heart malformations. We present a case of ectopia cordis and Pentalogy of Cantrell in a newborn of a healthy 35-year-old woman with no history of embryotoxic exposure or smoking. The infant was first diagnosed with the anomaly in the second trimester of pregnancy and was delivered at 35 weeks of gestational age via a caesarian section. Shortly after birth, he was transferred to the neonatal intensive care unit (NICU) due to progressive respiratory failure, which ultimately, along with septicemia, led to infant death on the second day. In conclusion, the Pentalogy of Cantrell should be appropriately assessed for effective prenatal counseling and postnatal management with a multidisciplinary team; since infant survival assessment and early diagnosis give the parents the option of terminating the pregnancy.

Keywords: case report, Pentalogy of Cantrell, ectopia cordis

Plain Language Summary

Pentalogy of Cantrell (POC) is a congenital anomaly with a poor prognosis, especially in developing countries. This syndrome is a collection of five congenital midline birth anomalies (cardiac malformations, partial absence of the pericardium, anterior diaphragm hernia, lower sternum defects, and abdominal wall defects) that present a distinctive challenge for surgeons. We present a case of ectopia cordis and POC diagnosed in the second trimester and delivered by the caesarian section from a healthy 35-year-old gravid 3 with no history of embryotoxic exposure or smoking. Shortly after delivery, the baby was transferred to the neonatal intensive care unit, and mechanical ventilation was assembled due to progressive respiratory failure. Unfortunately, his general condition deteriorated, and he died on the second day. In conclusion, the POC should be appropriately assessed for effective prenatal counseling and postnatal management with a multidisciplinary team.

Introduction

Pentalogy of Cantrell is a poor prognosis sporadic congenital disorder with an incidence of 1–60:200,000 births, and a 1.3:1 male predominance.^{1,2}

The pentalogy of Cantrell was first mentioned in 1958. It was distinguished by defects of the diaphragm's anterior part, the sternum's lower part, the abdominal wall, the pericardium, and various heart congenital anomalies.³ The original hypothesis attributed to this syndrome is arrest in the development of lateral mesoderm between 14 and 18 days of the embryonic period since no solitary genetic defect has been associated with it.⁴

Few patients have presented the full range of the Pentalogy of Cantrell associated with ectopia cordis in the literature.^{5–7} Here, we present a case of Pentalogy of Cantrell associated with ectopia cordis in a male newborn diagnosed in the second trimester and delivered by the caesarian section.

Case Presentation

A 35-years-old housewife woman, gravid 3, para 2, was referred to our radiology department after second-trimester ultrasonography reported omphalocele in her fetus. She had two prior normal vaginal delivery of healthy offspring and has no previous history of smoking, medical illness, specific medications, or congenital anomalies.

In the 23rd week of gestations, the US showed a small fetal chest with loss of anterior chest wall exposing the heart to the outside. The US also showed cardiac chambers with a slight loss of configuration, so cardiac anomalies could not be excluded. These findings were highly suggestive of the Pentalogy of Cantrell. Additionally, the US report supra-umbilical omphalocele, containing bowel loops and the liver (Figure 1). The amniocentesis was not performed due to family financial problems.

Magnetic resonance imaging (MRI) revealed an extra-thoracic heart located anterior to the chest cavity with the possibility of herniation of the left lung, herniated liver through the anterior abdominal wall, and dilated bowel with a chance of stenosis, atresia; and signs of spinal deformity. The above finding keeps with the Pentalogy of Cantrell and ectopia cordis (Figure 2).

Parents were thoroughly informed about the situation but preferred to continue the pregnancy since they had been dealing with secondary infertility for six years.

In the 33rd gestational week, the US showed a male gender and confirmed the diagnosis of Pentalogy of Cantrell and ectopia cordis.

On the 5th of march 2022 patient arrived in the delivery room at Al-Gumhori Teaching Hospital, Sana'a University, Sana'a, Yemen. The newborn was delivered with a caesarian section at 35 gestational weeks. The newborn length was about 46 cm. His weight was about 2100 g. The head circumference was about 30 cm, and the thoracic perimeter was 25cm. In the first and fifth minutes, the newborn received Apgar scores of 3/10 and 6/10, respectively.

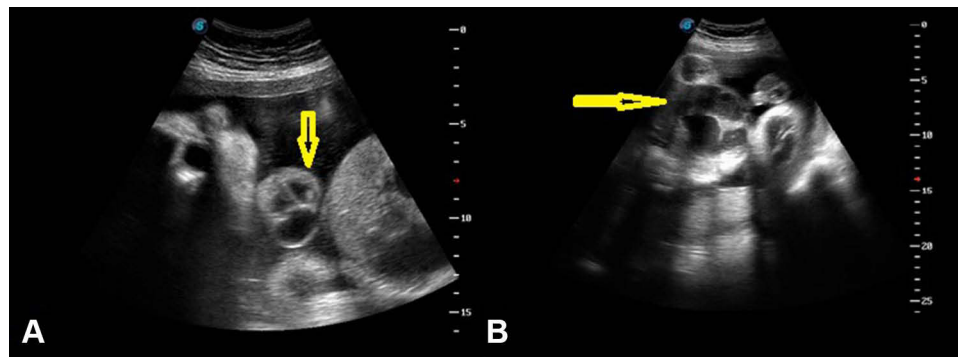


Figure 1 Two-dimensional sonographic examination showed (A) heart and liver extruded through the lower chest and upper abdomen (yellow arrow). (B) Omphalocele containing liver, intestine, and dilated bowel loops (yellow arrow).

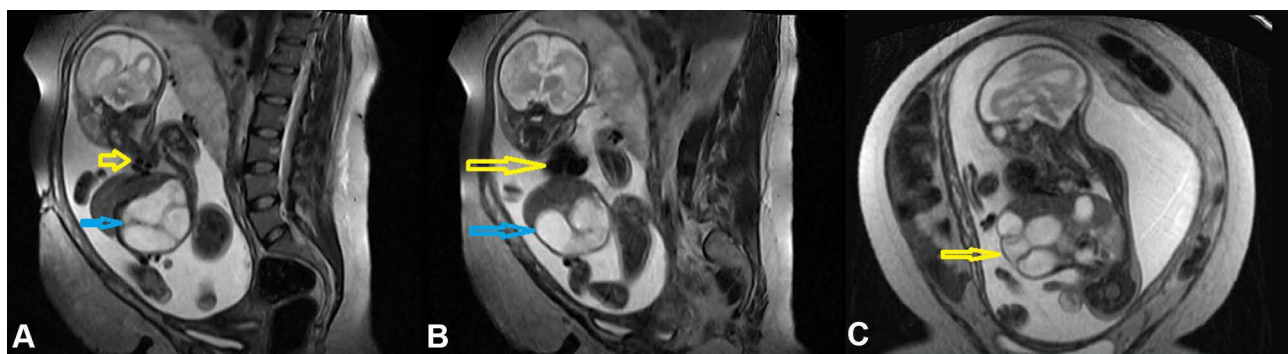


Figure 2 Magnetic resonance imaging (MRI) showed (A) sagittal view shows roots of four pulmonary veins (yellow arrow) and dilated bowels (blue arrow). (B) Sagittal view shows a four-chamber heart (yellow arrow) and dilated bowel (blue arrow). (C) Coronal view shows extrude liver and dilated bowel outside the abdomen (yellow arrow).

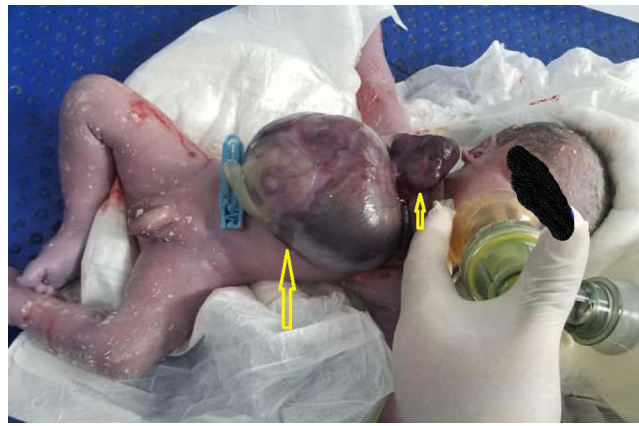

Figure 3 Post-delivery photo shows a baby with omphalocele (large cyst in the abdomen) and heart extruded through the chest (arrows).

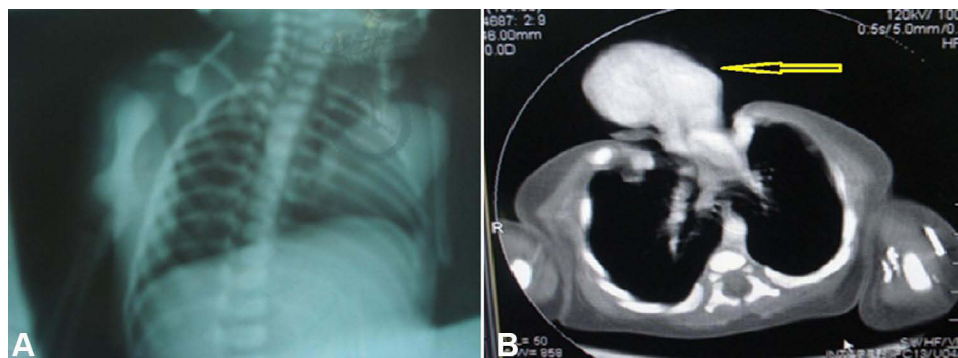


Figure 4 Shows (A) post-delivery chest x-ray of the patient. (B) Post-delivery computed tomography scan showed the Pentalogy of Cantrell (arrow).

On clinical examination, the neonate had a bulky omphalocele with the liver and bowel loops out of the abdomen and covered with thick membranous. Maldevelopment of the distal part of the sternum and diaphragmatic hernia were also observed. The heart was located outside the chest, associated with abnormalities (Figure 3).

Shortly after birth, the infant was admitted to the neonatal intensive care unit (NICU). Mechanical ventilation was assembled due to progressive respiratory failure, severe respiratory acidosis, and electrolyte imbalance in blood gas analysis. (Figure 4). Unfortunately, his general condition deteriorated, and he died on the second day due to septicemia and respiratory failure. We recommended the autopsy examination, but the patient's family did not accept it.

Discussion

Pentalogy of Cantrell is a severe congenital abnormality first described by James R Cantrell in 1958. The virulence factors and pathophysiology of Pentalogy of Cantrell are not well understood.⁸

Mechanical teratogenesis by amnion tissue band adhesion, vascular dysplasia, biological field defects, altered mesoderm formation during early embryogenesis, and structural compression secondary to chorion or yolk sac breakage are all theories suggested as the etiology of Pentalogy of Cantrell. Many chromosomal anomalies, primarily trisomy 18, have also been noted in individuals affected.^{9–12}

The majority of these cases are incidental, with only a few reports of familial cases suggesting a potential autosomal dominant, sex-linked disorder.^{13,14}

BMP2 (bone morphogenetic protein 2) gene mutations, according to some researchers, are the main reason for this condition since these genes are responsible for the normal midline structure development. Aldehyde Dehydrogenase 1 family member A2 (ALDH1A2) on chromosome 15 has recently been linked to the Pentalogy of Cantrell progression. ALDH1A2 codes for the enzyme retinaldehyde dehydrogenase type 2, which is required to convert vitamin A into all-

trans-retinoic acid. Retinoic acid is an essential morphogen for embryogenesis, as it is necessary for pleuroperitoneal diaphragm formation.^{10,15,16}

The Pentalogy of Cantrell manifests variously, ranging from minor to severe forms involving other organ systems. Additional anomalies, which include abnormalities of the central nervous system, the face, the intestinal system, and the limbs, are present in up to 28% of individuals affected.¹⁷

Toyama classified the severity of the Pentalogy of Cantrell into three categories in 1972. Class I Pentalogy of Cantrell is a definite diagnosis in which all five primary defects are existent. Class II is a likely diagnosis (4 of the five deformities existent), and Class III is a partial expression with various anomalies but always includes sternal deformities.¹⁸ Our case was Class I of Toyama's classification, which exhibited all five significant defects and additional primary and minor anomalies.

According to the literature, 80–100% of patients with Pentalogy of Cantrell have congenital heart defects, and ectopia cordis has been described in a few cases.⁶ In ectopia cordis, the heart is entirely or partially outside the thoracic cavity. It is classified into four subtypes based on the anatomic cardiac location: thoracic location (60%), abdominal location (30%), thoracoabdominal location (7%), and cervical location (3%).^{18,19} The thoracoabdominal subtype is commonly associated with Cantrell's Pentalogy, as seen in our case.²⁰

Pentalogy of Cantrell and ectopia cordis are listed on the Online Mendelian Inheritance in Man (OMIM) website as midline defects that may be part of an X-linked ventral midline developmental field complex. Research findings of an extended family of 14 affected individuals suggest mutations in the X-linked gene *ZIC3* (cited on Xq26.3) may be responsible for a subgroup of patients with ventral midline developmental field defects.⁹ As a result, we believe that in the presence of both midline developmental defects and anomalies implying left-right axis alterations, *ZIC3* mutations should be considered.

The US could identify this anomaly in the first gestational trimester. The diagnostic characteristics of Pentalogy of Cantrell in the US are pericardial effusion associated with an anterior diaphragmatic hernia and pericardial diaphragmatic deformities. Additionally, MRI exams will confirm the diagnosis and establish the fetal anomalies, as seen in our patient.^{21,22}

In our case, the combination of US and MRI has proven to be a valuable diagnostic tool, enabling the most appropriate way of counseling a pregnant woman and her family. Fetal echocardiography is now used to support the diagnosis of cardiac abnormalities associated with the Pentalogy of Cantrell.²²

The Pentalogy of Cantrell is treated with cardiovascular surgery and palliative surgical corrections of the ventral hernia, diaphragmatic malformations, and related anomalies. The magnitude of the abdominal wall defect, the malformations in the heart, and the form of ectopia cordis will all impact treatment strategies.^{23,24}

Van Hoorn et al conducted a literature review on 58 patients with Pentalogy of Cantrell. Complete Pentalogy of Cantrell was presented in 33 patients. 14 patients with ectopia cordis but no congenital cardiac abnormalities, 16 with intracardiac defects but no ectopia cordis, and 23 with both. 37 of the 58 patients cited, including those whose pregnancies were terminated, died within a few days of birth. Patients with associated abnormalities and the existence of the complete form had the highest mortality rate in this group. Ectopia cordis patients who survived had intracardiac abnormalities. This unusual finding might result from the limited number of patients in the study.²⁵ Due to inadequate facilities in our country, no government support, and no expert pediatric cardiac surgeon, performing any intervention for this neonate was impossible, and the baby died on the second day.

Conclusion

Pentalogy of Cantrell accompanied by ectopia cordis is a rare phenomenon with a broad range of clinical symptomatology and consequences, which demand a multidisciplinary team to be appropriately assessed for effective prenatal counseling and postnatal management. Prenatal investigations with fetal ultrasonography, fetal MRI, karyotyping, and genetic counseling for associated anomalies are critical since infant survival assessment and early diagnosis give the parents the option of terminating the pregnancy.

Ethics and Consent

Written informed consent was obtained from the patient's family to publish this case report and any accompanying images. No institutional approval was required to publish the case report.

Disclosure

The authors declare that they have no conflicts of interest in this work.

References

1. Desselle C, Herve P, Toutain A, et al. Pentalogy of Cantrell: sonographic assessment. *J Clin Ultrasound*. 2007;35(4):216–220. doi:10.1002/jcu.20318
2. Williams AP, Marayati R, Beierle EA. Pentalogy of Cantrell. *Semin Pediatr Surg*. 2019;28(2):106–110. doi:10.1053/j.sempedsurg.2019.04.006
3. Hill MA, Kwon JH, Rajab TK, et al. Pentalogy of Cantrell with a left ventricular diverticulum and muscular VSD. *Ann Thorac Surg*. 2021;113(6):e461–3.
4. Cantrell JR, Haller JA, Ravitch MM. A syndrome of congenital defects involving the abdominal wall, sternum, diaphragm, pericardium, and heart. *Surg Gynecol Obstet*. 1958;107(5):602–614.
5. Madi JM, Festugatto JR, Rizzon M, et al. Ectopia cordis associated with Pentalogy of Cantrell-A case report. *Rev Bras Ginecol Obstet*. 2019;41(5):352–356. doi:10.1055/s-0039-1679878
6. Ludwig K, Salmaso R, Cosmi E, et al. Pentalogy of Cantrell with complete ectopia cordis in a fetus with asplenia. *Pediatr Dev Pathol*. 2012;15(6):495–498. doi:10.2350/12-03-1169-CR.1
7. Pirasteh A, Carcano C, Kirsch J, et al. Pentalogy of Cantrell with ectopia cordis: CT findings. *J Radiol Case Rep*. 2014;8(12):29–34. doi:10.3941/jrcr.v8i12.1972
8. Khoury MJ, Cordero JF, Rasmussen S. Ectopia cordis, midline defects and chromosome abnormalities: an epidemiologic perspective. *Am J Med Genet*. 1988;30(3):811–817. doi:10.1002/ajmg.1320300314
9. Carmi R, Parvari R, Ehrlich S, et al. Mapping of an X-linked gene for ventral midline defects (the Tas gene). *Birth Defects Orig Artic Ser*. 1996;30(1):179–187.
10. Patil AR, Praveen LS, Ambica V. Pentalogy of Cantrell: a case report. *BJR Case Rep*. 2015;1(2):20140002. doi:10.1259/bjrcr.20140002
11. Korver AM, Haas F, Freund MW, et al. Pentalogy of Cantrell: successful early correction. *Pediatr Cardiol*. 2008;29(1):146–149. doi:10.1007/s00246-007-9032-z
12. Kaplan LC, Matsuoka R, Gilbert EF, et al. Ectopia cordis and cleft sternum: evidence for mechanical teratogenesis following rupture of the chorion or yolk sac. *Am J Med Genet*. 1985;21(1):187–202. doi:10.1002/ajmg.1320210128
13. Forzano F, Daubeney PE, White SM. Midline raphé, sternal cleft, and other midline abnormalities: a new dominant syndrome? *Am J Med Genet A*. 2005;135(1):9–12. doi:10.1002/ajmg.a.30682
14. Martin RA, Cunniff C, Erickson L, et al. Pentalogy of Cantrell and ectopia cordis, a familial developmental field complex. *Am J Med Genet*. 1992;42(6):839–841. doi:10.1002/ajmg.1320420619
15. Singh AP, Castranio T, Scott G, et al. Influences of reduced expression of maternal bone morphogenetic protein 2 on mouse embryonic development. *Sex Dev*. 2008;2(3):134–141. doi:10.1159/000143431
16. Steiner MB, Vengoechea J, Collins RT 2nd. Duplication of the ALDH1A2 gene in association with pentalogy of Cantrell: a case report. *J Med Case Rep*. 2013;7(1):287. doi:10.1186/1752-1947-7-287
17. Vazquez-Jimenez JF, Muehler EG, Daebritz S, et al. Cantrell's syndrome: a challenge to the surgeon. *Ann Thorac Surg*. 1998;65(4):1178–1185. doi:10.1016/S0003-4975(98)00089-7
18. Toyama WM. Combined congenital defects of the anterior abdominal wall, sternum, diaphragm, pericardium, and heart: a case report and review of the syndrome. *Pediatrics*. 1972;50(5):778–792.
19. Naren Satya SM, Mayilvaganan KR, Prathyusha IS, et al. A recurrent case of Pentalogy of Cantrell: a rare case with sonological findings and review of literature. *Pol J Radiol*. 2017;82:28–31. doi:10.12659/PJR.900086
20. Falkensammer CB, Ayres NA, Altman CA, et al. Fetal cardiac malposition: incidence and outcome of associated cardiac and extracardiac malformations. *Am J Perinatol*. 2008;25(5):277–281. doi:10.1055/s-2008-1066874
21. Oka T, Shiraishi I, Iwasaki N, et al. Usefulness of helical CT angiography and MRI in the diagnosis and treatment of pentalogy of Cantrell. *J Pediatr*. 2003;142(1):84. doi:10.1067/mpd.2003.mpd031
22. Song A, McLeary MS. MR imaging of pentalogy of Cantrell variant with an intact diaphragm and pericardium. *Pediatr Radiol*. 2000;30(9):638–639. doi:10.1007/s002470000288
23. Gao Z, Duan QJ, Zhang ZW, et al. Prognosis of pentalogy of Cantrell depends mainly on the severity of the intracardiac anomalies and associated malformations. *Eur J Pediatr*. 2009;168(11):1413–1414. doi:10.1007/s00431-008-0905-9
24. Chen CP. Syndromes and disorders associated with omphalocele (II): OEIS complex and Pentalogy of Cantrell. *Taiwan J Obstet Gynecol*. 2007;46(2):103–110. doi:10.1016/S1028-4559(07)60003-5
25. van Hoorn JH, Moonen RM, Huysentruyt CJ, et al. Pentalogy of Cantrell: two patients and a review to determine prognostic factors for optimal approach. *Eur J Pediatr*. 2008;167(1):29–35. doi:10.1007/s00431-007-0578-9

Pediatric Health, Medicine and Therapeutics

Dovepress

Publish your work in this journal

Pediatric Health, Medicine and Therapeutics is an international, peer-reviewed, open access journal publishing original research, reports, editorials, reviews and commentaries. All aspects of health maintenance, preventative measures and disease treatment interventions are addressed within the journal. Practitioners from all disciplines are invited to submit their work as well as healthcare researchers and patient support groups. The manuscript management system is completely online and includes a very quick and fair peer-review system. Visit <http://www.dovepress.com/testimonials.php> to read real quotes from published authors.

Submit your manuscript here: <http://www.dovepress.com/pediatric-health-medicine-and-therapeutics-journal>