

Facet angle and its importance on joint violation in percutaneous pedicle screw fixation in lumbar vertebrae

A retrospective study

Zhengkuan Xu, MD, Yiqing Tao, MD, Hao Li, MD, Gang Chen, MD, Fangcai Li, MD, Qixin Chen, MD*

Abstract

This is a retrospective study of case records. The aim of this study was to investigate the relationship between the facet angle (FA) at the pedicle level and facet joint violation (FJV) in percutaneous pedicle screw fixation (PPSF) in lumbar vertebrae.

Current PPSF technique has a high facet violation rate than open surgery, and the relationship of FJV and FA has not been studied.

Retrospective imaging analysis was conducted for 115 cases who underwent PPSF from December 2013 to November 2016 by the same group of surgeons using the same technique, in the spine surgery center of our hospital. The FA at the pedicle level was measured by computed tomography, and diagnosis and evaluation of FJV grade were performed postoperatively. The effect of the variant FA and lumbar segment (L1-L5) on FJV, and the correlation between FA and the FJV and FJV grade in PPSF were evaluated.

A total of 476 percutaneous pedicle screws were included: 144 L1, 136 L2, 64 L3, 72 L4, and 60 L5 screws, with a total FJV rate of 30.46% (145/476). The FJV rate was 28.78% in upper lumbar group with 344 screws (99/344), and 34.85% in lower lumbar group with 132 screws (46/132). There was no significant difference between groups with regards to FJV rate, and age, sex, or BMI index. Evaluation of variant FA and lumbar segment on FJV rate indicated that FJV rate increased dramatically when FA >35 degree; however, FJV rate was not significantly related to the lumbar segment. There was a positive correlation between FA and FJV rate, as well as FA and FJV grade.

There was a positive correlation between the increase of the FA at the pedicle level, and the FJV rate and FJV grade. The FJV risk increased remarkably when the FA was >35 degree.

Abbreviations: ASD = adjacent segment disease, CT = computed tomography, FA = facet angle, FJV = facet joint violation, PPSF = percutaneous pedicle screw fixation, 2-way ANOVA = 2-factor analysis of variance.

Keywords: facet angle, joint violation, lumbar vertebrae, percutaneous pedicle screw fixation

1. Introduction

Use of the percutaneous pedicle screw technique combined with external fixation for thoracolumbar fractures was first reported

Editor: Bernhard Schaller.

ZX, YT, and HL contributed equally to this work.

Funding: This study was partly supported by funding from the National Nature Science Foundation of China (81171756, 81401822 and 81472114).

Ethical Approval and Consent to participate: This study was approved by ethics committee of 2nd affiliated hospital, School of medicine, Zhejiang University. The recruited subjects gave informed consents before the present study.

Consent for publication: Not applicable

Availability of supporting data: The data were collected and analyzed by authors, and are not ready to share their data because the data have not been published.

The authors report no conflicts of interest.

Department of Orthopedics, 2nd Affiliated Hospital, School of medicine, Zhejiang University, Hangzhou, China.

* Correspondence: Qixin Chen, #88 Jie Fang Road, Hangzhou, 310009 Zhejiang, PR China (e-mail: zrcqx@zju.edu.cn).

Copyright © 2018 the Author(s). Published by Wolters Kluwer Health, Inc. This is an open access article distributed under the terms of the Creative Commons Attribution-Non Commercial-No Derivatives License 4.0 (CCBY-NC-ND), where it is permissible to download and share the work provided it is properly cited. The work cannot be changed in any way or used commercially without permission from the journal.

Medicine (2018) 97:22(e10943)

Received: 21 February 2018 / Accepted: 7 May 2018

<http://dx.doi.org/10.1097/MD.0000000000010943>

by Magerl.^[1] Percutaneous pedicle screw technology has the advantages of less trauma, less bleeding, and quick recovery. It has been widely used in the clinical treatment of spinal fractures, degenerative disease, and spinal deformities with confirmed effectiveness^[2–5]. However, since 2011, many authors have reported that, compared with the open pedicle screw fixation technique, percutaneous pedicle screw technology leads to a higher facet joint violation (FJV) rate; moreover, it was proposed that FJV leads to adjacent segment disease (ASD), causing early postoperative pain and increasing the reoperation rate^[6–8]. However, the risk factors of FJV in percutaneous pedicle screw technique are still unclear nowadays.

The change of the facet angle (FA) of the human body varies for each individual. FAs of different segments are different; furthermore, FA on the same segment is even different. Thoracic FAs are distributed coronally, whereas lumbar vertebrae FAs have a sagittal distribution (average 25–56 degree).^[9,10] The FA is important to protect articulation during lumbar micro-discectomy. Nevertheless, for the clinical application of the percutaneous pedicle screw technique in lumbar fixation, there is no relevant study about the effects of difference in lumbar segments and difference in FA on the FJV.

In this study, to investigate the potential relationship between FA and FJV, we retrospectively analyzed 115 consecutive patients who received the same percutaneous pedicle screw fixation (PPSF) treatment by the same group of surgeons in the spine surgery centers of our hospital from December 2013 to November 2016, with a total of 476 pedicle screws. We analyzed

the correlation between different lumbar segments and different FAs with the FJV. Our objectives were: to investigate the effect and correlation of L1-L5 segments and percutaneous pedicle screw techniques on the FJV; and to explore the effect and correlation of FA on the FJV.

2. Methods

2.1. Inclusion and exclusion criteria

This study was approved by ethics committee of 2nd affiliated hospital, School of medicine, Zhejiang University. The recruited subjects gave informed consents before the present study. Inclusion criteria were as follows: patients with lumbar fracture or lumbar degenerative disease who were treated by percutaneous pedicle screw technology; patients with PPSF segment including the lumbar spine; and patients with PPSF who were treated by the same group of surgeons guided by anteroposterior and lateral C-arm fluoroscopy.

Exclusion criteria were as follows: patients with severe spinal deformity with vertebral rotation; severe osteoporosis; fused articular facet joints such as ankylosing spondylitis, etc; and patients with both thoracic and lumbar spine screw fixation; thoracic screw data were excluded.

2.2. Demographic data

In total, 115 consecutive patients received lumbar vertebrae PPSF between December 2013 and November 2016 (56 males and 59 females, average age 53.71 ± 12.19 years, age range 15–77 years). A total of 476 PPSF procedures were conducted, of which 144 were at L1, 136 at L2, 64 at L3, 72 at L4, and 60 at L5.

Among the 115 patients, 91 patients had spinal fractures, 24 had lumbar spinal stenosis or lumbar spondylolisthesis with or without segmental instability requiring extreme lateral intervertebral fusion. There were 72 patients who underwent fixation at L1, 68 at L2, 32 at L3, 36 at L4, and 30 at L5.

2.3. Surgical methods

2.3.1. Imaging requirements of C-arm fluoroscopy. A standard anteroposterior image of the vertebral segment was obtained by adjusting the C-arm perfectly parallel to the endplates. The superior and inferior endplates were superimposed with the spinous process centered between the pedicles, and the bilateral oval-shaped pedicle ring images symmetrical. The lateral image demonstrated the bilateral posterior borders overlapping with the upper and lower borders of the pedicle images, with the superior and inferior endplates parallel.

2.3.2. Check points A, B, and C of Jamshidi needle insertion.

Checkpoint A: the starting point of the needle tip on the anteroposterior image was at the 3 o'clock or 9 o'clock position of the lateral edge of the pedicle ring; the corresponding site of the lateral fluoroscopic image was the starting point of the pedicle (Fig. 1).

Checkpoint B: when the tip of the needle was located at the middle of the pedicle ring on the anteroposterior fluoroscopic image, the corresponding checkpoint on the lateral image was the central position of the pedicle.

Checkpoint C: when the tip of the needle was located at the inner edge of the pedicle ring on the anteroposterior fluoroscopic

image, the corresponding checkpoint on the lateral image must have reached or exceeded the posterior margin of the vertebral body.

2.3.3. Surgical procedure. Patients were positioned prone under general anesthesia. A pad was placed under the abdomen to suspend the thoracolumbar area and maintain lumbar lordosis. Conventional disinfection was performed. Anteroposterior fluoroscopy was focused at the vertebral pedicle ring of the vertebral body in question, the surface projection horizontal line was drawn at the 3 o'clock or 9 o'clock position of the pedicle, and then the vertical line was drawn 0.5–1 cm from the outer edge of the pedicle. A 1.5-cm incision was made along the vertical line with the horizontal line as midline. The skin, subcutaneous, and deep fascia were incised, followed by coagulation hemostasis. Anteroposterior C-arm fluoroscopy was used to monitor the three checkpoints of A, B, and C, with the Jamshidi needle gradually inserted into the lateral edge (3 o'clock or 9 o'clock), the central and inner margin of the pedicle of the vertebral body, with the corresponding checkpoints on the lateral image as the starting point, midpoint, and posterior margin of the pedicle. The center of the trocar was pulled out, the guidewire inserted, the catheter needle removed, and projected along the guidewire into the working sleeve. The hollow tap was tightened for approximately 3 cm, and then the pedicle screws implanted with appropriate length and diameter as determined by preoperative computed tomography (CT). After screw implantation, the prebent titanium rod was inserted and screwed into the pedicle screw-fixating nut, which was tightened, and the stick connection locked. The same method was used to conduct screw rod fixation connection on the opposite side. Once C-arm fluoroscopy showed a satisfactory image with good internal fixation position, the cap was locked again with the counter wrench, and the T type handle until the screw cap was broken. The operative site was irrigated without placement of a drainage device, followed by closure of the deep fascia and skin.

2.3.4. Postoperative management. All patients underwent lumbar radiographic imaging and CT examination on the second postoperative day to confirm positioning of the percutaneous pedicle screw and FJV. Patients were instructed to exercise early, while avoiding waist bending or rotational movement.

2.4. Data acquisition and imaging assessment

According to the different lumbar fixation segments, patients were divided into upper lumbar vertebrae (L1-L3 vertebral body) and lower lumbar vertebrae (L4, L5 vertebral body) groups, as well as an FJV group and non-FJV group according to the presence or absence of FJV.

2.5. Imaging assessment

Preoperative cross-sectional CT was used to measure the FA at the pedicle level (the angle between the facet joint and the sagittal axis of the vertebral body, Fig. 1A).^[9] Postoperative CT cross-sectional assessment of FJV and FJV grade was performed according to the diagnostic and grading criteria of Babu et al (Table 1).^[7]

2.6. Statistical analysis

SPSS version 17.0 statistical software (SPSS, Chicago, IL) was used for statistical analysis. Measurement data were expressed as

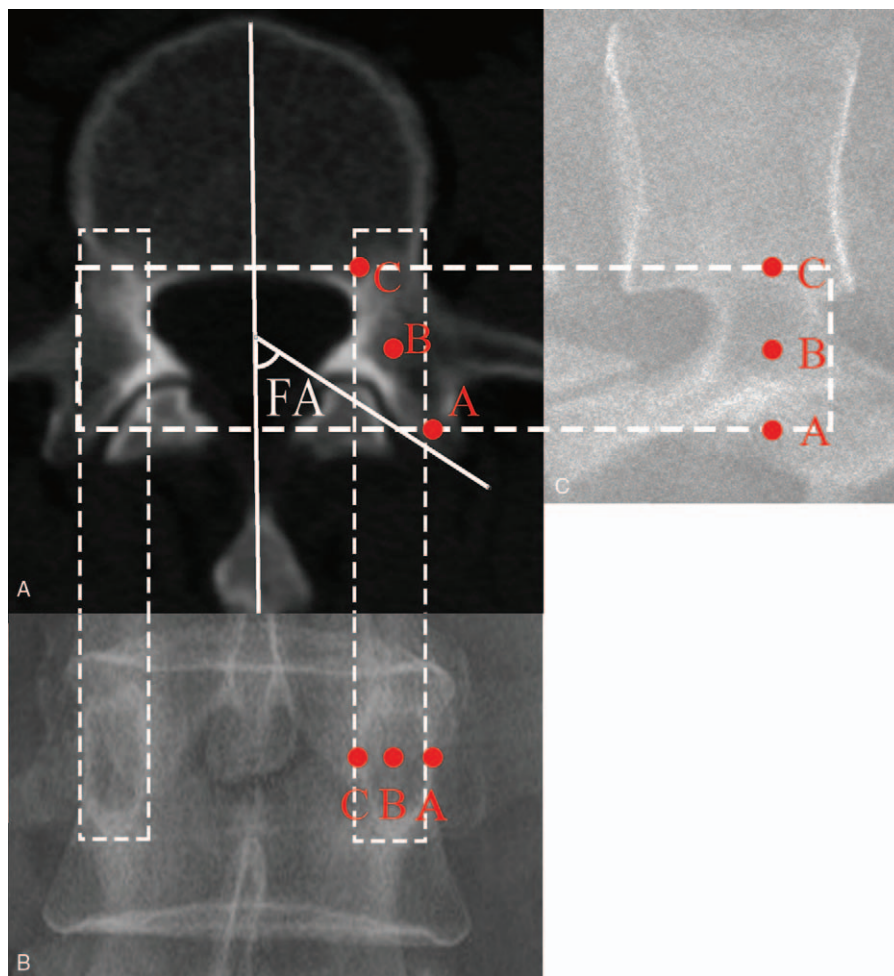


Figure 1. (A) FA measurement: select transverse section image of the pedicle on the lumbar CT, measuring the angle between the facet joint and vertebral axis (angle between the solid white line). (B) Dashed line shows the oval-shaped pedicle ring of the pedicle on CT and the projection on the anteroposterior-lateral C-arm fluoroscopy, indicating overlapping of the facet joint and oval-shaped pedicle ring, and the larger FA occupying a larger screw pathway. The red A, B, and C dots indicate the relationship between the 3 checkpoints of the anteroposterior-lateral C-arm fluoroscopy with those of the CT image. CT = computed tomography, FA = facet angle.

the mean ± standard deviation. Comparison between groups was conducted using the independent sample *t* test. Numerical data were expressed as percentages and the χ^2 test was used for between-group comparisons. In addition, the difference in FJV rate between the upper and lower lumbar vertebra was analyzed by the χ^2 test. The influence of lumbar segment (L1-L5) and FA on the FJV was analyzed by 2-factor analysis of variance (2-way ANOVA). The Spearman rank correlation test was used to analyze the correlation between FA, FJV rate, and the FJV grade. The test confidence level was set at a bilateral $\alpha=0.05$.

3. Results

3.1. Effects of lumbar segment and FA on the FJV

A total of 115 patients were included in the study, including 78 patients with upper lumbar screws, 26 lower lumbar screws, and 11 screw fixation cases in both the upper and lower lumbar vertebrae. There were a total of 476 percutaneous pedicle screws implanted and 145 (30.46%) demonstrated an FJV rate. Of these, there were 344 (72.27%) upper lumbar screws with an FJV rate of 28.78% (99/344), and 132 (27.73%) lower lumbar screws with an FJV rate of 34.85% (46/132); no significant difference was detected between groups ($\chi^2=1.659, P=.198$). There was no significant difference in age, sex, and body mass index (BMI) between groups ($P > .05$, Table 2).

The FA distribution of L1-L5 on the lumbar pedicle level was 35.25 ± 12.14 degree (Fig. 2). The FA on the pedicle level of 35 degree was used as the threshold for ranked ordinal data. There were 272 cases with an FA of ≤ 35 degree, with an FJV rate of 22.06% (60/272). There were 204 cases demonstrating an FA of greater than 35 degree, with an FJV rate of 41.67% (85/204). L1-L5 screw FJV distribution is shown in Figure 3. The effect of the

Table 1

Classification criteria of [7]FJV.

Grade	Relationship between screws and facet joints
Grade 0	Screws not in facet
Grade 1	Screw in lateral facet but not in facet articulation
Grade 2	Penetration of facet articulation by screw, with entry distance less than 1 mm
Grade 3	Screw travels within facet articulation, with entry distance larger than 1 mm

FJV = facet joint violation.

Table 2

Comparison of upper lumbar and lower lumbar groups.

Group	Number of pedicle screws	Age, y ($\bar{x} \pm s$)	Male/female	BMI, kg/m ² ($\bar{x} \pm s$)	FA, degree ($\bar{x} \pm s$)	FJV rate (%)
Upper lumbar group	344	53.95 ± 11.92	176/168	23.93 ± 2.99	34.40 ± 12.83	28.78% (99/344)
Lower lumbar group	132	55.92 ± 11.47	57/75	24.18 ± 2.84	37.44 ± 9.83	34.85% (46/132)
T value or χ^2 value	-	$t = -1.625$	$\chi^2 = 2.432$	$t = -0.828$	$t = -2.454$	$\chi^2 = 1.659$
P	-	.105	.119	.408	.014	.198

BMI = body mass index, FA = facet angle, FJV = facet joint violation.

FA and lumbar segment on the FJV was analyzed by 2-way ANOVA. Interestingly, an FA of >35 degree significantly increased the rate of joint violation ($F = 20.124, P < .0001$). Otherwise, there was no significant effect of the L1-L5 lumbar segments on the rate of FJV ($F = 0.926, P = .448$). Typical cases are shown in Figure 4.

3.2. The relationship between FA and FJV

Among the 476 percutaneous pedicle screws, there were 145 (30.46%) cases in the FJV group, with an average FA of 39.84

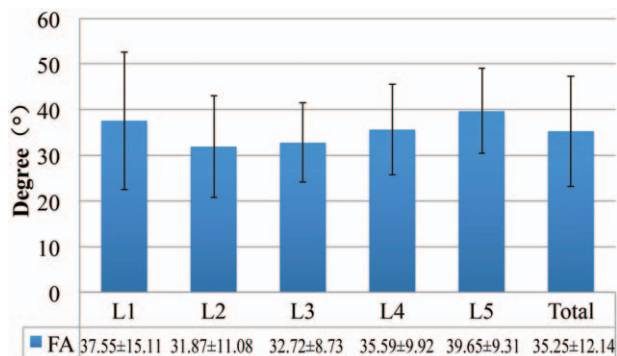


Figure 2. FA distribution of L1-L5 segments. FA on L1 is from the coronal shift to the sagittal orientation of the thoracolumbar vertebrae, which is still large. FA of the L2 is the smallest, whereas the FA of L3 and the lower vertebrae gradually becomes larger. FA = facet angle.

±12.61 degree. There were 331 (69.54%) in the non-FJV group, with an average FA of 33.23 ± 11.38 degree. As a result, the FA of the FJV group was significantly larger than that of the non-FJV group ($t = -5.643, P < .0001$). Moreover, the Spearman rank correlation analysis between the FA and FJV showed a significant correlation ($r = 0.251, P < .0001$).

3.3. The relationship between FA and FJV grade.

A total of 145 (30.46%) pieces of percutaneous pedicle screw demonstrated the joint violation. According to diagnostic grading criteria by Babu et al^[7], there were 331 of grade 0 (69.54%), 87 of grade 1 (18.28%), 38 of grade 2 (7.98%), and 20 of grade 3 (4.20%). Furthermore, Spearman rank correlation analysis was performed between the FA of 145 percutaneous pedicle screws and the FJV grade, which showed significant correlation ($r = 0.274, P < .0001$).

4. Discussion

At present, there are 2 surgical techniques for the clinical application of percutaneous pedicle screw placement. The most widely used method is under anteroposterior-lateral C-arm fluoroscopy guidance, which we also adopted in the current study. Heintel et al^[11,12] described this technique in detail for percutaneous pedicle screw placement. But the 3 checkpoints for intraoperative imaging mainly focused on mitigating the risk of pedicle violation, however, ignoring protection of the facet joint, which causes early pain post operation. Recently, the “owl’s-eye

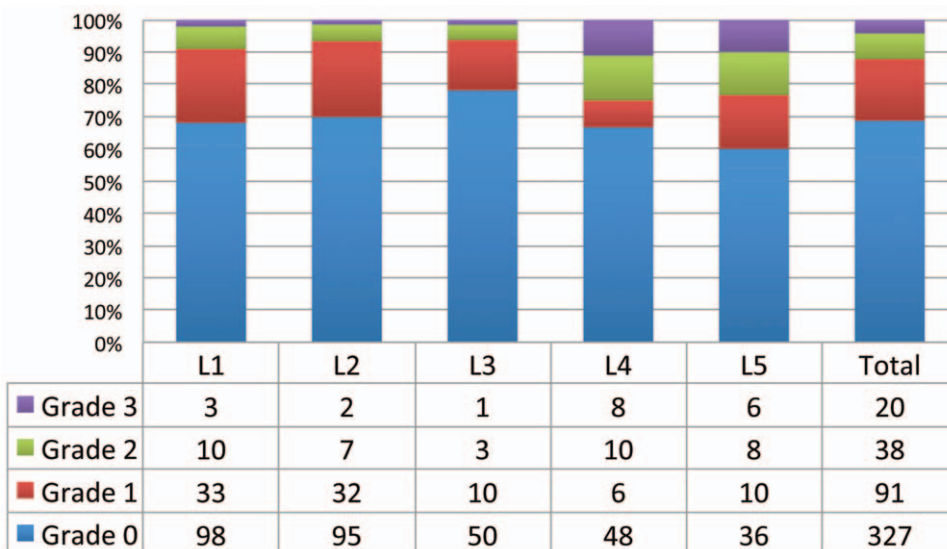


Figure 3. Distribution of facet joint violation grade on the L1-L5 segments.

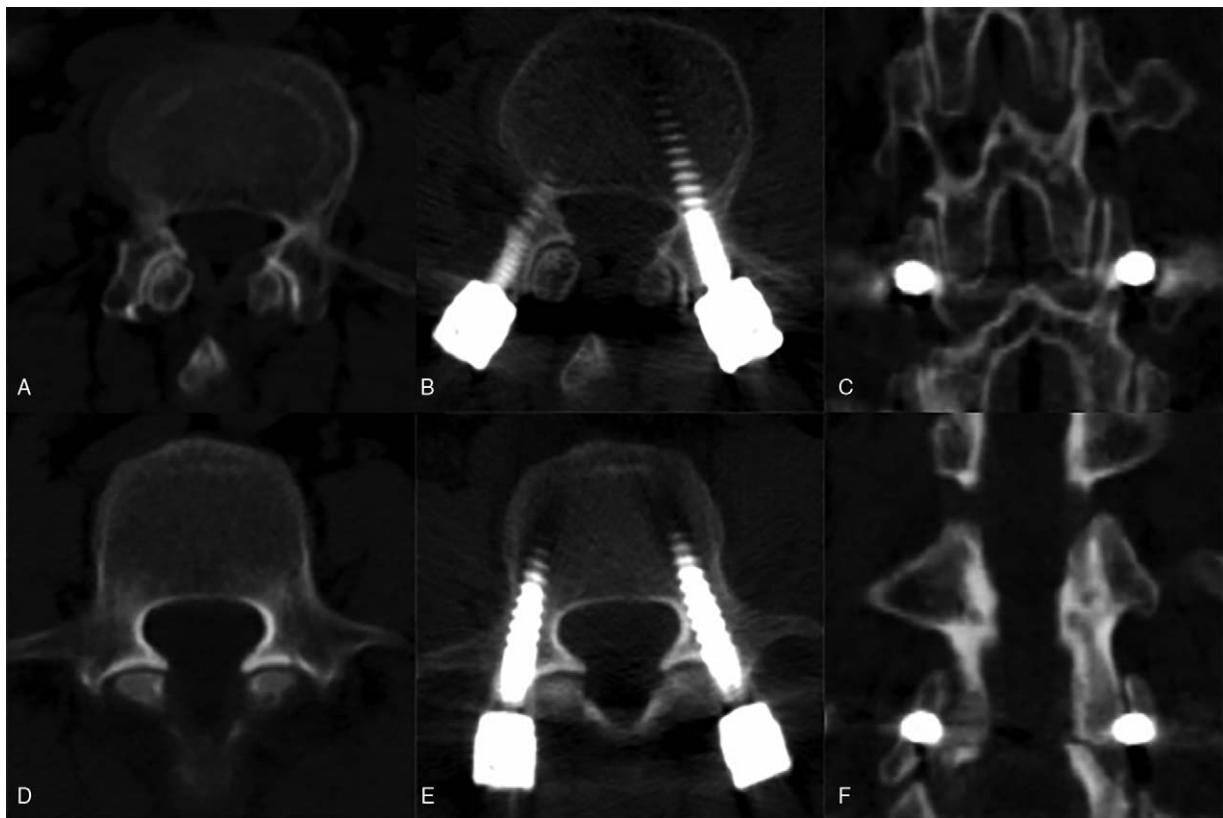


Figure 4. (A) Screw placement on the L4 vertebral body. The patient is a 62-year-old woman with grade I lumbar spondylolisthesis, who has undergone extreme lateral intervertebral fusion. The patient then received percutaneous pedicle screw fixation under anteroposterior-lateral C-arm fluoroscopy. The facet angle of L4 is 30 degree (left) and 29 degree (right). (B, C) The postoperative facet joint violation (FJV) grade was grade 0 bilaterally, whereas both computed tomography (CT) transverse section images and coronal reconstruction showed that no FJV. (E, F) Screw placement on the L4 vertebral body. The patient was a 57-year-old female with lumbar spinal stenosis who underwent extreme lateral intervertebral fusion. The patient then received percutaneous pedicle screw fixation, with L4 at the pedicle level and FAs of 68 degree (left) and 75 degree (right). Postoperative FJV was determined to be grade 2 (left) and grade 3 (right). CT transverse-sectional imaging and coronal reconstruction suggested that the pedicle screw has penetrated the joint cavity.

technique" was proposed,^[13] performed under the oblique approach under anteroposterior-lateral C-arm fluoroscopy guidance. The endplates of the vertebrae are required to be parallel and the C-arm was obliquely placed on the screw-implanted side until the pedicle ring reached the maximum area, like an owl eye. Then, the screw was inserted along the center of the owl's eye, with the starting point and entire path of the screw to not exceed the owl eye. The surgical procedure is designed to prevent the escape of the screw from the pedicle screw range, also ignoring the protection of the facet joints. Recently, research has shown the joint violation rate of percutaneous pedicle screw placement techniques under the guidance of the anteroposterior lateral C-arm to be lower.^[14] As the current percutaneous pedicle screw placement technique lacks the protection of the facet joints, since 2011, many authors have reported the FJV rate of the percutaneous pedicle screw to be as high as 6.3% to 58%,^[6-8,15] with only a BMI of >30kg/m² as a risk factor for FJV.^[7] Unfortunately, the potential anatomical risk factors of FJV have not been described in recent studies.

To the best of our knowledge, there have been no reports disclosing the effect of the FA at the level of pedicle on the FJV. The results of this study showed that there was a significant positive correlation between the FA and the FJV rate. In addition, there was also a significant positive correlation between the FA and the FJV grade. Interestingly, the rate of articular facet joint

damage significantly increased from 22.06% to 41.67%, when the FA is >35 degree (the average FA of this data). This result suggested that the greater the FA at the pedicle level, the greater the risk of FJV. Whereas the effects of different segments, and upper or lower lumbar location, on the FJV rate are not significant. There could be many reasons. First, overlapping between the oval-shaped pedicle ring and projection of the facet joint in the intraoperative anteroposterior-lateral C-arm fluoroscopy, which becomes more significant with a larger FA. When the facet joint projection covers most of the oval-shaped pedicle ring, or even covers the lateral edge of the pedicle ring, it is bound to increase the rate of FJV. Second, when the FA increases, that is, the facet joint gradually changes to the coronal direction, it will block the pathway of the percutaneous screw (Fig. 1). Therefore, the percutaneous screw is more likely to pass through rather than scratch the facet joints, leading to a higher FJV. Third, the pedicle angles of the segments are different, resulting in different directions of percutaneous screw placement, for which the lower lumbar spine is generally larger than the upper lumbar spine. When the segment changes, FA increases, and the percutaneous screw insertion direction is also changed toward the coronal direction, producing interactive effects. Therefore, this study showed that the effects of different segments, and upper or lower lumbar location, were not significant with regards to the FJV rate.

There are many authors who argue that superior FJV leads to accelerated ASD after instrumented spinal fusion.^[16,17] Therefore, to assess the safety and accuracy of percutaneous pedicle screw technology, it is not enough to only observe whether the pedicle screw invades the spinal canal or violates the pedicle, but also the rate of the FJV must be assessed. The traditional PPSF technique did not set any specific checkpoints on C-arm fluoroscopy to protect the facet joints. Therefore, others propose new auxiliary techniques to reduce the rate of FJV. Patel et al^[6] suggested that using the transverse process as the starting point for screw placement can effectively avoid FJV, but failed to elaborate on how to adjust the checkpoints on anteroposterior-lateral C-arm fluoroscopy. Ohba et al^[18] compared percutaneous pedicle screw placement with traditional C-arm fluoroscopy and CT-guided 3D navigation technology. The results showed the FJV rate with C-arm fluoroscopy to be 30.5%, whereas the FJV rate of percutaneous placement using CT-guided 3D navigation was 3.8%—significantly lower, suggesting that the 3D navigation technique can effectively protect the facet joints. The comparison study by Yson et al^[19] also reached the same conclusion.

There are also several limitations in present study. First of all, the patients, included in this study, are Asian population. As there is no investigation providing the striking difference among different populations, the correlation between FA and FJV rate or FJV grade is credible; however, the particular angle should be confirmed by more samples from patients of different populations. Additionally, this research retrospectively studied the effects of FA on the FJV without a relevant solution. In the future, we will carry out prospective clinical research, hoping to set or adjust the checkpoint on the C-arm fluoroscopy to protect the facet joints, optimizing the surgical method and reducing the FJV rate.

5. Conclusion

In conclusion, current standard percutaneous pedicle screw placement guided by anteroposterior-lateral C-arm fluoroscopy results in a high rate of FJV. The FA at the pedicle level significantly affected the occurrence of FJV, which also significantly correlated with the rate of FJV, and the FJV grade. An FA >35 degree will significantly increase the risk of FJV.

Author contributions

Xu Z, Li F and Chen Q carried out the concept and research design. Xu Z, Tao Y, Li H and Chen Q retrieved the data and participated in the analysis and interpretation of data. Xu Z, Tao Y and Li H conceived of statistical analysis. Xu Z and Chen G helped to draft and revised the manuscript for important intellectual content. All authors read and approved the final manuscript.

Data curation: Zhengkuan Xu, Yiqing Tao, Qixin Chen.

Formal analysis: Zhengkuan Xu, Hao Li.

Investigation: Zhengkuan Xu, Yiqing Tao, Hao Li.

Methodology: Zhengkuan Xu, Yiqing Tao, Hao Li, Gang Chen.

Resources: Hao Li, Gang Chen.

Supervision: Fangcai Li.

Validation: Fangcai Li.

Writing – original draft: Zhengkuan Xu, Yiqing Tao.

Writing – review & editing: Fangcai Li, Qixin Chen.

References

- [1] Magerl FP. Stabilization of the lower thoracic and lumbar spine with external skeletal fixation. *Clin Orthop Relat Res* 1984;125–41.
- [2] Phan K, Rao PJ, Mobbs RJ. Percutaneous versus open pedicle screw fixation for treatment of thoracolumbar fractures: Systematic review and meta-analysis of comparative studies. *Clin Neurol Neurosurg* 2015;135:85–92.
- [3] Miyashita T, Ataka H, Kato K, et al. Good clinical outcomes and fusion rate of facet fusion with a percutaneous pedicle screw system for degenerative lumbar spondylolisthesis: minimally invasive evolution of posterolateral fusion. *Spine (Phila Pa 1976)* 2015;40:E552–7.
- [4] Cimatti M, Forcato S, Polli F, et al. Pure percutaneous pedicle screw fixation without arthrodesis of 32 thoraco-lumbar fractures: clinical and radiological outcome with 36-month follow-up. *Eur Spine J* 2013;22 (suppl 6):S925–32.
- [5] Ahmad FU, Wang MY. Use of anteroposterior view fluoroscopy for targeting percutaneous pedicle screws in cases of spinal deformity with axial rotation. *J Neurosurg Spine* 2014;21:826–32.
- [6] Patel RD, Graziano GP, Vanderhave KL, et al. Facet violation with the placement of percutaneous pedicle screws. *Spine (Phila Pa 1976)* 2011;36:E1749–52.
- [7] Babu R, Park JG, Mehta AI, et al. Comparison of superior-level facet joint violations during open and percutaneous pedicle screw placement. *Neurosurgery* 2012;71:962–70.
- [8] Jones-Quaidoo SM, Djurasovic M, Owens RK2nd, et al. Superior articulating facet violation: percutaneous versus open techniques. *J Neurosurg Spine* 2013;18:593–7.
- [9] Masharawi Y, Rothschild B, Dar G, et al. Facet orientation in the thoracolumbar spine: three-dimensional anatomic and biomechanical analysis. *Spine (Phila Pa 1976)* 2004;29:1755–63.
- [10] Masharawi Y, Rothschild B, Salame K, et al. Facet tropism and interfacet shape in the thoracolumbar vertebrae: characterization and biomechanical interpretation. *Spine (Phila Pa 1976)* 2005;30:E281–92.
- [11] Heintel TM, Dannigkeit S, Fenwick A, et al. How safe is minimally invasive pedicle screw placement for treatment of thoracolumbar spine fractures? *Eur Spine J* 2017;26:1515–24.
- [12] Heintel TM, Berglehner A, Meffert R. Accuracy of percutaneous pedicle screws for thoracic and lumbar spine fractures: a prospective trial. *Eur Spine J* 2013;22:495–502.
- [13] Idler C, Rolfe KW, Gorek JE. Accuracy of percutaneous lumbar pedicle screw placement using the oblique or "owl's-eye" view and novel guidance technology. *J Neurosurg Spine* 2010;13:509–15.
- [14] Tannous O, Jazini E, Weir TB, et al. Facet joint violation during percutaneous pedicle screw placement: a comparison of two techniques. *Spine (Phila Pa 1976)* 2016;Dec 02.
- [15] Lau D, Terman SW, Patel R, et al. Incidence of and risk factors for superior facet violation in minimally invasive versus open pedicle screw placement during transforaminal lumbar interbody fusion: a comparative analysis. *J Neurosurg Spine* 2013;18:356–61.
- [16] Wang H, Ma L, Yang D, et al. Incidence and risk factors of adjacent segment disease following posterior decompression and instrumented fusion for degenerative lumbar disorders. *Medicine (Baltimore)* 2017;96:e6032.
- [17] Kim TH, Lee BH, Moon SH, et al. Comparison of adjacent segment degeneration after successful posterolateral fusion with unilateral or bilateral pedicle screw instrumentation: a minimum 10-year follow-up. *Spine J* 2013;13:1208–16.
- [18] Ohba T, Ebata S, Fujita K, et al. Percutaneous pedicle screw placements: accuracy and rates of cranial facet joint violation using conventional fluoroscopy compared with intraoperative three-dimensional computed tomography computer navigation. *Eur Spine J* 2016;25:1775–80.
- [19] Yson SC, Sembrano JN, Sanders PC, et al. Comparison of cranial facet joint violation rates between open and percutaneous pedicle screw placement using intraoperative 3-D CT (O-arm) computer navigation. *Spine (Phila Pa 1976)* 2013;38:E251–8.