

Trauma and reconstruction

Renal transplantation with duplicated ureters: A case report

Gampo Alam Irdam*, Kindy Aulia Rasyid, Nur Rasyid, Arry Rodjani

Department of Urology, Faculty of Medicine Universitas Indonesia, Jakarta, Indonesia, Jl. Diponegoro No. 71, Salemba, Jakarta Pusat, DKI Jakarta, 10430, Indonesia

ARTICLE INFO

Keywords:

Renal transplantation
Duplication of ureters
Urinary reconstruction

ABSTRACT

We reported a case in which a renal allograft with duplicated ureters from a 25-year old donor were successfully transplanted into a 38-year old recipient with combination of spatulation and side-to-side anastomosis of the duplicated ureters with Lich-Gregoir technique for ureteroneocystostomy of the transplantation. There was no complication after the transplant. The recipient's post-operative course remains uneventful at more than 4 months with serum creatinine 1.35 mg/dL.

Introduction

Renal transplant is considered as the best available treatment for end-stage renal disease (ESRD). In Indonesia, renal transplantation from deceased donor is not yet legalized, therefore living donor becomes the only option.¹ Consequently, urologists may use all compatible donor organs including organs with unmodifiable anatomic characteristics. Ureteral duplications are common anomaly, found in approximately 1 in 125 people (0.8%). There are few reports on transplantation using kidneys with duplicated ureters, and ureteroneocystostomy techniques for duplicated ureters has not yet been established. These techniques vary depending on surgeons' preference.² In this case, we performed a combination of spatulation and side-to-side anastomosis of duplicated ureters with an extravesical technique of ureteroneocystostomy (Lich-Gregoir).

Case presentation

A 38-year-old woman with ESRD following uncontrolled hypertension received living renal transplant from her 25-year-old sister. Preoperative evaluation revealed a double pelvicalyceal system and duplicated ureters on both kidneys by intravenous pyelography. Both ureters fused on the level of minor pelvic cavity on the right side and on the level of 5th lumbar vertebral body on the left side (Fig. 1). The left kidney was taken as donor due to better feasibility for the laparoscopic technique.

The patient underwent laparoscopic nephrectomy in modified left lateral position. After achieving pneumoperitoneum, left kidney was exposed and both left ureters were distally dissected until the fusion part. The left gonadal vein was dissected as distal as possible to preserve

ureteral vascularity. The left renal vein and artery were identified and dissected from the surrounding tissue; branches to the renal vein were ligated. After securing the ureters and gonadal vein with ligature clips, we sharply transected those structures. Renal vessels were secured with two ligature clips for each and then transected. The kidney was taken out and then flushed.

Simultaneously, the recipient was prepared. Right Gibson's incision was done to prepare the location for ureteral implantation at the bladder while preserving the right external iliac vessels. After flushing the allograft kidney, we performed end-to-side vascular anastomosis; renal vein/artery to right external iliac vein/artery. Total warm ischemic time was 39 minutes, cold ischemic time was 28 minutes and the urine stream was observed 2 minutes later. The duplicated ureters were cut 1 cm proximal from the fused part. Each ureter was spatulated about 1 cm on the medial surface and side-to-side anastomosis was performed with 4-0 Vicryl(R) interrupted suture. A 3-cm-longitudinal myotomy was performed on the right anterolateral wall of bladder. A 1.5-cm-elliptical opening was made on the mucosal layer. After inserting a 6-Fr-double J stent, the ureter was sutured to the mucosal layer with 4-0 Vicryl(R) interrupted suture. The perivesical fat and muscular layer were closed over the anastomosed ureter to prevent vesicoureteral reflux by 3-0 chromic catgut suture. The surgical incision was closed (Figs. 2 and 3).

The recipient's postoperative course was uneventful: no fever, extravasation or urinary leakage. The drain was removed on the fourth POD. The patient was discharged on the sixth POD with hemoglobin 9.1 g/dL, ureum 81 mg/dL, creatinine 1.4 mg/dL and urine production 3280 ml/24 hours. The double-J stent was removed one month later. Two weeks postremoval, no apparent sign of hydronephrosis with ureum 45 mg/dL, creatinine 0.87 mg/dL, and glomerular filtration rate

* Corresponding author.

E-mail addresses: gampoai@gmail.com (G.A. Irdam), kindyrasyid28@gmail.com (K.A. Rasyid), nur.rasyid@gmail.com (N. Rasyid), arry_rodjani@gmail.com (A. Rodjani).<https://doi.org/10.1016/j.eucr.2019.100946>

Received 18 May 2019; Received in revised form 9 June 2019; Accepted 11 June 2019

Available online 12 June 2019

2214-4420/© 2019 The Authors. Published by Elsevier Inc. This is an open access article under the CC BY-NC-ND license (<http://creativecommons.org/licenses/by-nc-nd/4.0/>).

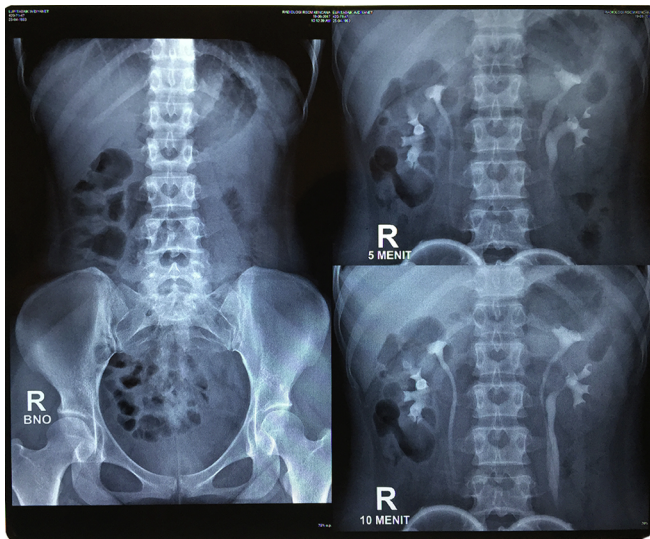


Fig. 1. Patient's KUB-IVP showed that she has double pelvicalyceal system and duplicated ureters on both kidneys. Both kidneys have double collecting system and duplicated ureters. Right ureters fused as one on distal ureter, while left ureters fused on mid ureter.

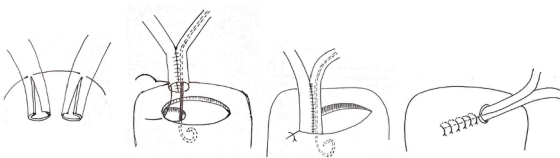


Fig. 2. Spatulation of duplicated ureters to anastomose the duplicated ureters combined with Lich-Gregoir technique to anastomose the ureters to the bladder. (Illustration by K. Aulia).

(GFR) 80 ml/minute. Fourth month postremoval, patient had no complaint with ureum 38 mg/dL and creatinine 1.35 mg/dL. One year later, patient had no complaint and renal function test showed normal result (ureum 28 mg/dL and creatinine 1.2 mg/dL). Sonography examination for both follow-up periods revealed no dilation of ureter or pelvicalyceal system.

Discussion

Duplicated ureters are prevalent in approximately 0.8% population.¹ The shortage of donated kidneys allows renal allograft with duplicated ureters be used for renal transplantation. However, some technical modifications are necessary for the ureteroneocystostomy.

Various methods for ureteroneocystostomy of duplicated ureters in renal transplantation have been described in previous studies, including the combination of spatulation and side-to-side anastomosis of duplicated ureters with Lich-Gregoir technique. From 43 duplicated ureters patients which transplanted using this technique, only 9 patients had urological complications (4 ureteral leakage, 2 ureteral obstruction and 3 reflux).^{2,3}

Other extravesical ureteroneocystostomy techniques are available for renal allograft with duplicated ureters namely: (A) Duplicated ureters are introduced to a common ostium on the bladder and fixed with a simple U-stitch²; (B) Duplicated ureters separately introduced to two different ostiums on the bladder²; (C) Duplicated ureters separately introduced to native ureter (double ureteroureterostomy).³ From 8 patients using first technique, one patient had ureteral leakage and another one had reflux. The advantages are the use of a single cystostomy, simple and possibly decreasing the operation time. From 17 patients using second technique, one patient had ureteral obstruction and another one had reflux. The third technique was used in 2 studies which none had urological complications.²

In our study, we used the combined technique of side-to-side anastomosis of the duplicated ureters with Lich-Gregoir technique. The advantages are minimal vesical dissection, avoidance of second myotomy incision and ureteral reimplantation, shorter operation time and possibility of using short ureters.³ Haferkamp et al. compared 10 patients receiving the same technique as our study with 9 patients having separate anastomoses. The complication rate for both techniques was similar.³

A multicenter study compared outcomes and complications of renal transplant with duplicated ureters to the single ureter. The first group (76 duplicated ureters patients) and the second group (2365 single ureter patients), were receiving renal allograft. This study demonstrated no statistically significant difference between groups regarding postoperative complications, patient and graft survival during 5-year-follow-up.⁴

Ureteral leakage, stricture, vesicoureteral reflux, hydronephrosis and urinary tract infection are common complications following the ureteroneocystostomy technique.⁵ Among three most frequently used

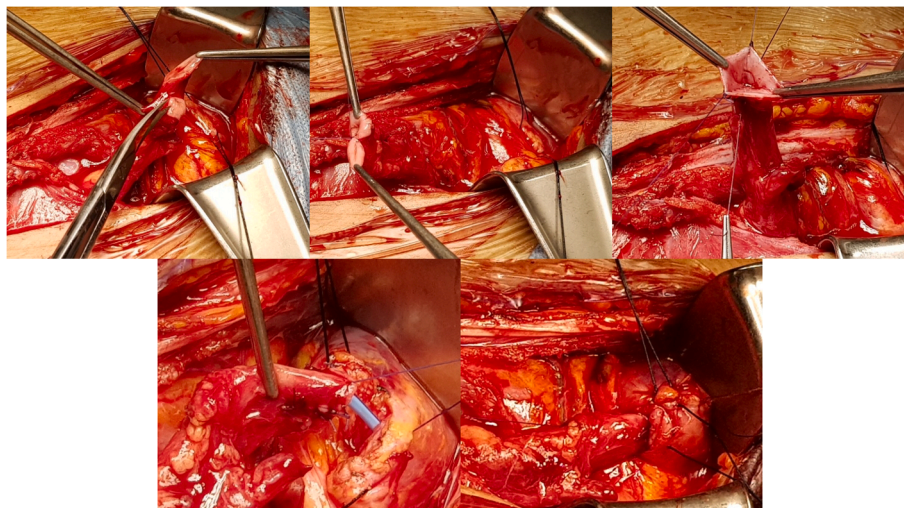


Fig. 3. Intra-operation documentation of the combined technique: spatulation of duplicated ureters combined with Lich-Gregoir technique, an extravesical technique in ureteroneocystostomy.

ureteroneocystostomy techniques in renal transplant, Lich-Gregoir technique had a significant fewer ureteral leakage, stricture and hematuria compared to Politano-Leadbetter and also significantly fewer hematuria compared to Taguchi/U-stitch technique. Vesicoureteral reflux was insignificant between among three aforementioned techniques.⁵

Conclusion

Spatulation and side-to-side anastomosis with Lich-Gregoir technique for ureteral implantation has good outcome, no complication and applicable for ureteroneocystostomy in renal transplantations with duplicated ureters. Further follow-up is needed to evaluate long-term complications.

Consent

The patient has already given his consent to be reported and published as a case report.

Conflict of interest

There is no conflict of interest, neither financial or nonfinancial, in the whole process from making to publishing this study.

References

1. Peters CA, Cathy Mendelsohn C. Ectopic ureter, ureterocele, and ureteral anomalies. In: Campbell MF, Walsh PC, Retik AB, eds. *Campbell's Urology*. eleventh ed. Philadelphia: Saunders; 2016.
2. Uchida J, Naganuma T, Machida Y, et al. Modified extravesical ureteroneocystostomy for completely duplicated ureters in renal transplantation. *Urol Int*. 2006;77:104–106.
3. Haferkamp A, Dorsam J, Mohring K, Wiesel M, Staehler G. Ureteral complications in renal transplantation with more than one donor ureter. *Nephrol Dial Transplant*. 1999;14:1521–1524.
4. Ghazanfar A, Zaki MR, Pararasingam R, Forgacs B, Tavakoli A. Outcome of kidney transplant with double ureter: a multicenter study. *Exp Clin Transplant*. 2015;13(2):152–156.
5. Alberts VP, Idu MM, Legemate DA, Pes MP, Minnee RC. Ureterovesical anastomotic techniques for kidney transplantation: a systematic review and meta-analysis. *Transpl Int*. 2014;27(6):593–605.