



# Clinical Evidence for the Relationship between Nail Configuration and Mechanical Forces

Hitomi Sano, MD\*†  
Rei Ogawa, MD, PhD†

**Summary:** Mechanobiology is an emerging field of science that focuses on the way physical forces and changes in cell or tissue mechanics contribute to development, physiology, and disease. As nails are always exposed to physical stimulation, mechanical forces may have a particularly pronounced effect on nail configuration and could be involved in the development of nail deformities. However, the role of mechanobiology in nail configuration and deformities has rarely been assessed. This review describes what is currently understood regarding the effect of mechanical force on nail configuration and deformities. On the basis of these observations, we hypothesize that nails have an automatic curvature function that allows them to adapt to the daily upward mechanical forces. Under normal conditions, the upward daily mechanical force and the automatic curvature force are well balanced. However, an imbalance between these 2 forces may cause nail deformation. For example, pincer nails may be caused by the absence of upward mechanical forces or a genetic propensity increase in the automatic curvature force, whereas koilonychia may occur when the upward mechanical force exceeds the automatic curvature force, thereby causing the nail to curve outward. This hypothesis is a new concept that could aid the development of innovative methods to prevent and treat nail deformities. (*Plast Reconstr Surg Glob Open* 2014;2:e115; doi: 10.1097/GOX.0000000000000057; Published online 7 March 2014.)

Our bodies are constantly subjected to mechanical forces that directly affect cellular functions. For example, gravity and body weight influence bone metabolism, bone density, and bone cell proliferation/differentiation.<sup>1-4</sup> Mechanobiology is an emerging and rapidly growing field of scientific

and medical research that focuses on the spatial and temporal responses to mechanical forces that shape development, physiology, and disease. Indeed, there are already several therapies that utilize the biological responses of tissues to mechanical forces, namely, tissue expanders<sup>5</sup> and negative pressure wound therapy.<sup>6</sup> These approaches can be seen as mechanotherapies, as described in a recent review.<sup>7</sup>

Nails have numerous functions. Fingernails are very important in protecting the distal phalanges, enhancing tactile discrimination, and performing fine manipulation and haptic tasks.<sup>8-11</sup> They are also widely used for scratching and grooming and are an efficient natural weapon. Toenails protect the distal toes and contribute to pedal biomechanics. Thus, nails are always exposed to physical stimulation.

The nail configuration is influenced by genetic factors, the shape of the distal phalangeal bone,<sup>12</sup>

From the \*Department of Surgical Science, Graduate School of Medicine, University of Tokyo, Tokyo, Japan; and †Department of Plastic, Reconstructive and Aesthetic Surgery, Nippon Medical School, Tokyo, Japan.

Received for publication August 14, 2013; accepted January 2, 2014.

Copyright © 2014 The Authors. Published by Lippincott Williams & Wilkins on behalf of The American Society of Plastic Surgeons. *PRSGO Global Open* is a publication of the American Society of Plastic Surgeons. This is an open-access article distributed under the terms of the Creative Commons Attribution-NonCommercial-NoDerivatives 3.0 License, where it is permissible to download and share the work provided it is properly cited. The work cannot be changed in any way or used commercially.

DOI: 10.1097/GOX.0000000000000057

**Disclosure:** The authors have no financial interest to declare in relation to the content of this article. The Article Processing Charge was paid for by the authors.

mechanical force,<sup>13–15</sup> malnutrition,<sup>16</sup> neurogenic factors,<sup>17,18</sup> blood flow,<sup>19,20</sup> and factors that cause the thinning and softening of nails.<sup>21</sup> Because several treatments for pincer nails that are based on the principle of mechanical correction (eg, use of an elastic wire<sup>22</sup> or a plastic device)<sup>23,24</sup> can be effective, mechanical forces may have a particularly pronounced effect on nail configuration and thus may also be involved in nail deformity development. However, the role of mechanobiology in nail configuration and deformities has rarely been considered. In the present review, the effect of mechanical force on nail configuration was assessed. We hope that the information contained in this review will help to inform and initiate future experimental and clinical research.

## ANATOMICAL CHARACTERISTICS OF NAILS

To understand the effect of mechanical forces on nails, it is important to briefly describe the structures of the nail. Thus, the nail apparatus consists of the nail plate, the nail fold, the nail matrix, the sterile matrix, and the hyponychium.

### Nail Plate

The nail plate is a fully keratinized structure that is continuously produced throughout life. It results from maturation and keratinization of the nail matrix epithelium and is firmly attached to the sterile matrix, which partially contributes to its formation.

In transverse section, the nail plate consists of 3 portions: the dorsal, intermediate, and ventral nail plates.<sup>25</sup> The dorsal and intermediate plates are produced by the nail matrix, whereas the ventral plate is produced by the sterile matrix. Above the lunula, the nail plate is thinner and consists only of the dorsal and intermediate plates. The nail plate is densely adherent to the matrices on its undersurface, but distal of the onychodermal band, it becomes a free structure. Nails thicken with age, particularly in the first 2 decades. Nail thickness depends on the length of the nail matrix and the sterile matrix.<sup>26</sup>

### Nail Fold

The sides of the nail plate are bordered by lateral nail folds that are continuous with the proximal fold. The lateral nail folds enclose the lateral free edges of the nail plate and are bounded by the attachment of the skin to the lateral aspect of the distal phalanx margin and the lateral nail; they provide the visible proximal border of the nail apparatus. The proximal nail fold is a skinfold that consists of a dorsal and a ventral portion. The dorsal portion is anatomically similar to

the skin of the dorsum of the digit but is thinner and devoid of pilosebaceous units. The ventral portion covers approximately one-fourth of the nail plate.

### Nail Matrix

The nail matrix is a specialized epithelial structure that lies above the midportion of the distal phalanx. In longitudinal sections, the matrix has a wedge-shaped appearance and consists of a proximal (dorsal) and a distal (ventral) portion. Nail matrix keratinocytes divide in the basal cell layer and keratinize in the absence of a granular zone. The site of keratinization of nail matrix onychocytes can be clearly distinguished. In this area, nuclear fragments are destroyed by deoxyribonuclease and ribonuclease enzymes. Keratinization of the proximal nail matrix cells produces the dorsal nail plate, whereas keratinization of the distal nail matrix cells produces the intermediate nail plate. The distal matrix is not completely covered by the proximal nail fold but is visible through the nail plate as a white half-moon-shaped area called the lunula. The white color of the lunula results from 2 main anatomic factors: (1) the keratogenous zone of the distal matrix contains nuclear fragments that cause light diffraction and (2) nail matrix capillaries are less visible than sterile matrix capillaries because of the relative thickness of the nail matrix epithelium.<sup>27</sup> Melanocytes,<sup>28</sup> Langerhans cells, and Merkel cells<sup>29</sup> have also been observed in the nail matrix.

### Sterile Matrix

The sterile matrix epidermis extends from the distal margin of the lunula to the hyponychium. The sterile matrix epithelium is thin and consists of 2–5 cell layers. The sterile matrix contribution to nail plate formation is approximately one-fifth of the terminal nail thickness and mass.<sup>30</sup> The dermis is well innervated and contains numerous sensory nerve endings, including Merkel endings and Meissner's corpuscles.<sup>31</sup> Sterile matrix cells differentiate toward the nail plate, contributing to it ventrally.

### Hyponychium

The hyponychium is the area under the free nail between the onychodermal band proximally and the distal groove. It is an epidermal ridge that demarcates the junction between the finger pulp and the subungual structures.

## ROLE OF MECHANOBIOLOGY IN NAIL DEFORMITY

Although excessive curvature of the nail is classically considered to be an abnormal state,<sup>32</sup> we hypothesize that nails are actually equipped with an

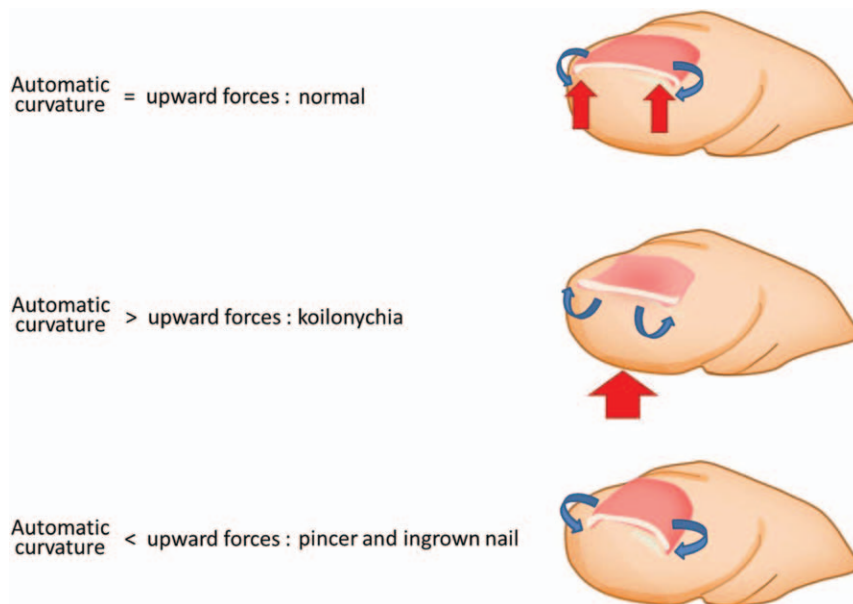
automatic curvature force that helps them to adapt to daily upward mechanical forces. We also hypothesize that when the upward mechanical and automatic curvature forces are well balanced, the nail is normal; however, an imbalance between these 2 forces may result in nail deformation. Thus, pincer nails may be caused either by the lack of such upward mechanical forces or by an inherent increase in the automatic curvature force. In addition, if the upward mechanical force exceeds the automatic curvature force, the nail will curve outward, resulting in koilonychia (Fig. 1).

### WHY DO NAILS CURVE WHEN MECHANICAL FORCE IS LACKING?

Like nails, hair is composed of cornified keratinocytes and is a tissue whose morphology is related to mechanical forces.<sup>33</sup> Hair has a central layer and a surrounding layer, and it has been suggested that the mechanical force resulting from a mismatch in the growth rates of the central and surrounding layers is mainly responsible for the curling deformation of hair.<sup>33–35</sup> Nails are composed of a similarly layered structure, namely, they have dorsal, intermediate, and ventral nail plates.<sup>36</sup> We hypothesize that when there is a mismatch in the growth rates of these nail layers, the nail configuration changes and could lead to nail deformities. Such a mismatch in layer growth

rates is possible because, as described above, the dorsal and intermediate layers of the nail plate are produced by the nail matrix, whereas the ventral layer is produced by the sterile matrix.<sup>12</sup> This mismatch is exemplified by pincer nails, which tend to show greater inward curvature on the distal side; as it has been suggested that the dorsal layer of the pincer nail maintains the same circumferential length from the root to the tip, this means that the pincer nail is the result of shortening of the ventral layer in the tip side.<sup>32</sup>

The mismatched growth of the ventral and dorsal layers that results in pincer nail deformation may be driven by the lack of mechanical stimuli as follows. The dermis of the sterile matrix contains numerous mechanoreceptors, including Merkel endings and Meissner's corpuscles.<sup>31</sup> Although the functions of these mechanoreceptors have not yet been fully elucidated, they may play a prominent role in the nail unit in the early stages of fetal development and a role in ontogenesis has been proposed.<sup>29</sup> As mechanical forces are generally known to directly promote cell proliferation and differentiation,<sup>1–5</sup> it is possible that mechanical stimuli may shape nail configuration either through those mechanoreceptors or by directly affecting sterile matrix cell proliferation. Thus, those parts of the sterile matrix that receive most of the mechanical stimuli from walking and loading may grow faster than other, less stimulat-



**Fig. 1.** Hypothesis to explain the mechanism underlying the development of nail deformities. Under normal conditions, the upward mechanical force on the nail and its automatic curvature force are well balanced. However, if the upward mechanical force exceeds the automatic curvature force, the nails curve outward. Conversely, if the automatic curvature force exceeds the upward mechanical force, the nails curve inward.

ed parts of the sterile matrix, leading to a normally shaped nail. However, in the absence of mechanical stimuli, the growth rates of the matrix-oriented dorsal and intermediate layers and the sterile matrix-oriented ventral layer become mismatched, which may lead to nail deformities.

### RELATIONSHIP BETWEEN NAIL DISEASES AND MECHANICAL FORCES

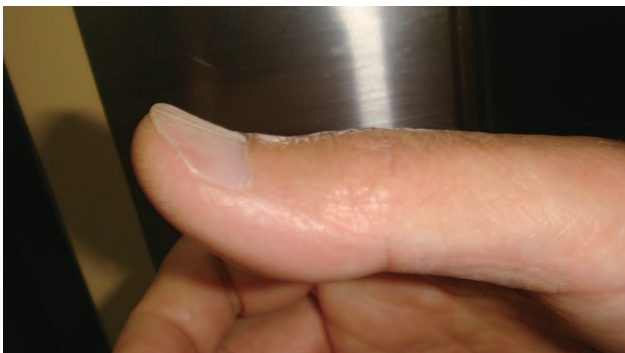To demonstrate how mechanical force can shape nail configuration, koilonychia and pincer nail were chosen as representative nail deformities.

#### Koilonychia

Koilonychia is characterized by spooning of the nails (Fig. 2). It has been associated with various causative factors and diseases, including iron deficiency, chronic renal failure,<sup>37</sup> malnutrition,<sup>16</sup> and pharmaceutical use. It is known that its etiology is often associated with thinning and softening of the nails.<sup>21</sup> Supporting this is several studies that suggest that thin and/or fragile nails readily adopt a concave shape when they are subjected to mechanical force.<sup>38,39</sup>

However, koilonychia can also be observed in the nails of healthy adults that are exposed to frequent strong force. Bentley-Phillips and Bayles<sup>39</sup> reported that toe nail koilonychias was observed at a high rate in “Ricksha pullers,” whose bare feet are habitually exposed to gross trauma. They also showed that the disease rate was higher in the older pullers and was proportional to the length of the employment. They hypothesized that the koilonychias in these workers may have been the result of pressure and trauma.

Furthermore, koilonychia in the toenails of children is normal: it reflects the immaturity of their nails, which cannot yet withstand normal mechanical forces.<sup>12</sup> These observations indicate that koilonychia may develop when the mechanical force exceeds the nail strength.



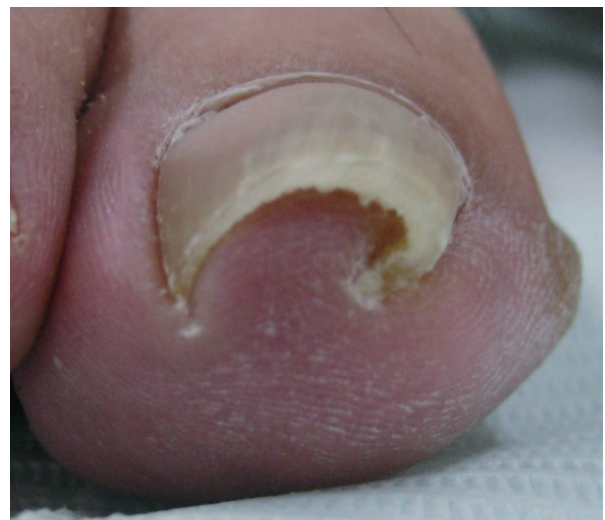**Fig. 2.** Typical appearance of koilonychias. The nail plate has a concave form.

#### Pincer and Ingrown Nails

Pincer nail is defined as the transverse overcurvature of the nail plate that increases along the longitudinal axis (Fig. 3).<sup>40</sup> Ingrown nails resemble pincer nails as they are characterized by a sharp irregular nail edge that involves the distal corners of the nails; they are usually due to improper trimming. However, while ingrown nail may be confused with pincer nail and at the clinical level the two often associate with each other, ingrown nail is generally a relatively symptomatically derived term, while pincer nail is a more morphologically derived term.<sup>32</sup> Although pincer and ingrown nails are commonly encountered diseases, their precise etiologies remain unclear.

Plausible mechanisms for pincer nail and ingrown nail include heredity,<sup>41,42</sup> inappropriate nail cutting,<sup>43,44</sup> and in particular, the physical forces caused by ill-fitting shoes.<sup>43,44</sup> However, there is also a high incidence of pincer nail among bedridden patients whose feet are not subjected to shoes or weight bearing.<sup>45</sup>

In our previous studies, we assessed the degree of great toe nail curvature in volunteers who had been bedridden for various durations; moreover, we compared the great toe and thumb nail curvatures of the loaded and nonloaded sides of subjects with unilateral loading due to hemiplegia or fracture.<sup>13</sup> The degree of great toe nail curvature tended to increase as the duration of the bedridden state rose. Moreover, in the unilateral loading cases, the great toe nails on the nonloaded side had a greater degree of curvature than those on the loaded side. Similarly, in hemiplegia cases, the thumb nails on the palsy side were more curved than those on the nonpalsy side.<sup>14</sup> Thus, these studies support the notion that nails can be affected by mechanical forces.



**Fig. 3.** Typical appearance of pincer nail. Transverse overcurvature of the nail plate is observed.



We also examined how the frequency and strength of mechanical forces influence the nail configuration, nail morphology, and pinch strength in healthy adults.<sup>15</sup> For this, the thumb nails of healthy subjects with office-based and carpentry professions were compared. In a second study, the left and right finger nails of jazz bassists were compared. The carpenters had a significantly stronger pinch force than the office workers, which suggests that carpenters use stronger pinch force on a daily basis. The thumb nails of the office workers had a significantly higher curve index than those of the carpenters, which suggests that mechanical force affects nail morphology. In the study of the nails of the bassists, the right fourth and fifth fingers, which are not used in playing bass, had more strongly curved nails than their counterparts on the left hand, which are used in playing. As expected, the pinch force of the left fifth finger, which is used to place strong pressure on the strings, was much stronger than the pinch force of the unused right fifth finger. Interestingly, while the right (unused) and left (frequently but weakly used) fourth fingers did not differ in terms of pinch force, the former was significantly more curved. This suggests that even weak forces that are applied with high frequency, such as those placed on the left fourth finger during bass playing, can affect nail morphology. These observations together indicate that pincer nail may develop when the nail strength exceeds the mechanical force.

### CURRENT NAIL-TREATMENT STRATEGIES

The indications for treatment of pincer and ingrown nails are pain, inflammation, interference with wearing shoes, and cosmetic embarrassment. Various surgical<sup>46–54</sup> and conservative measures<sup>55,56</sup> have been reported. Surgical procedures, including total or partial excision of the sterile matrix,<sup>57,58</sup> phenolization,<sup>59</sup> and carbon dioxide laser matricectomy,<sup>60</sup> are commonly performed. The disadvantages of these methods include complexity, pain, time consumption, and the need for local anesthesia during the operation. Moreover, these methods themselves result in some cosmetic deformity, namely, a narrower nail width.

Conservative procedures are usually employed first. These include cotton, elastic tape,<sup>61</sup> polyacryl sculptured nails,<sup>62</sup> flexible tube splinting,<sup>62,63</sup> or an elastic wire<sup>22</sup> or plastic device.<sup>23,24</sup> Although these conservative treatments are relatively noninvasive, they demand frequent care and the recurrence rate is high.

### FUTURE PERSPECTIVES

The treatment of nail deformities can be revolutionized by elucidating the relationship between mechanical force and nail configuration: this knowledge will help to prevent or treat nail deformity, as it will reveal which passive mechanical forces could alter the force imbalance that leads to deformity and how to alter the automatic curvature force of the nails. In addition, the pincer nails of hard and thick nails can be treated by applying an external preparation that softens the nail or by thinning the nails with a nail rasp. These mechanical stimulus-based treatments can also be used to prevent recurrence after the conventional therapies described above. Although koilonychia treatment has rarely been documented, this condition may be improved by reducing the physical stimulus on the nail and by supplying nutrients that aid the growth of the nails. We hope that this review of the new concepts and mechanism(s) underlying nail deformities will aid the future development of innovative methods of prevention and treatment.

### CONCLUSION

Mechanical forces may affect nail configuration and be involved in the development of nail deformities. Although the pathophysiology of the cellular and tissue responses of the nail to mechanical force remains unknown, our hypothesis is a new concept that could lead to innovative methods that prevent and treat nail deformities.

*Hitomi Sano, Department of Surgical Science  
Graduate School of Medicine  
University of Tokyo  
Hongo 7-3-1, Bunkyo-ku  
Tokyo 113-8656  
Japan  
E-mail: sasasa116sasasa@hotmail.com*

### REFERENCES

1. Duncan RL, Turner CH. Mechanotransduction and the functional response of bone to mechanical strain. *Calcif Tissue Int.* 1995;57:344–358.
2. Aronson J, Good B, Stewart C, et al. Preliminary studies of mineralization during distraction osteogenesis. *Clin Orthop Relat Res.* 1990;250:43–49.
3. Carter DR, Beaupré GS, Giori NJ, et al. Mechanobiology of skeletal regeneration. *Clin Orthop Relat Res.* 1998;355:41–55.
4. Kim IS, Song YM, Hwang SJ. Osteogenic responses of human mesenchymal stromal cells to static stretch. *J Dent Res.* 2010;89:1129–1134.
5. Lantieri LA, Martin-Garcia N, Wechsler J, et al. Vascular endothelial growth factor expression in expanded tissue: a possible mechanism of angiogenesis in tissue expansion. *Plast Reconstr Surg.* 1998;101:392–398.
6. Orgill DP, Manders EK, Sumpio BE, et al. The mechanisms of action of vacuum assisted closure: more to learn. *Surgery* 2009;146:40–51.

7. Huang C, Holfeld J, Schaden W, et al. Mechanotherapy: revisiting physical therapy and recruiting mechanobiology for a new era in medicine. *Trends Mol Med*. 2013;19:555–564.
8. Ashbell TS, Kleinert HE, Putcha SM, et al. The deformed finger nail, a frequent result of failure to repair nail bed injuries. *J Trauma* 1967;7:177–190.
9. Russell RC, Casas LA. Management of fingertip injuries. *Clin Plast Surg*. 1989;16:405–425.
10. Drake LA, Scher RK, Smith EB, et al. Effect of onychomycosis on quality of life. *J Am Acad Dermatol*. 1998;38(5, Part 1):702–704.
11. Salazard B, Launay F, Desouches C, et al. [Fingertip injuries in children: 81 cases with at least one year follow-up]. *Rev Chir Orthop Reparatrice Appar Mot*. 2004;90:621–627.
12. Tosti A, Piraccini BM. Biology of nails and nail disorders. In: Fitzpatrick TB, Wolff K, eds. *Fitzpatrick's Dermatology in General Medicine*. 7th ed. New York: McGraw-Hill; 2008:778–794.
13. Sano H, Ichioka S. Influence of mechanical forces as a part of nail configuration. *Dermatology* 2012;225:210–214.
14. Sano H, Ogawa R. Role of mechanical forces in hand nail configuration asymmetry in hemiplegia: an analysis of four hundred thumb nails. *Dermatology* 2013;226:315–318.
15. Sano H, Shionoya K, Ogawa R. Impact of mechanical forces on finger nail curvature: an analysis of the impact of different occupations on 332 finger nails. *Dermatol Surg*. In press.
16. Al-Dabbagh TQ, Al-Abachi KG. Nutritional koilonychia in 32 Iraqi subjects. *Ann Saudi Med*. 2005;25:154–157.
17. Horowitz SH. Diabetic neuropathy. *Clin Orthop Relat Res*. 1993;296:78–85.
18. Andersen H. Motor dysfunction in diabetes. *Diabetes Metab Res Rev*. 2012;28(Suppl 1):89–92.
19. Alemany M. Regulation of adipose tissue energy availability through blood flow control in the metabolic syndrome. *Free Radic Biol Med*. 2012;52:2108–2119.
20. Loenneke JP, Abe T, Wilson JM, et al. Blood flow restriction: an evidence based progressive model (Review). *Acta Physiol Hung*. 2012;99:235–250.
21. Baron EB. Nutrition. In: Tierney LM, McPhee SJ, Papadakis MA, eds. *Current Medical Diagnosis and Treatment*. 38th ed. Stanford: Appleton and Lange; 1999:1182.
22. Moriue T, Yoneda K, Moriue J, et al. A simple therapeutic strategy with super elastic wire for ingrown toenails. *Dermatol Surg*. 2008;34:1729–1732.
23. Harrer J, Schöffl V, Hohenberger W, et al. Treatment of ingrown toenails using a new conservative method: a prospective study comparing brace treatment with Emmert's procedure. *J Am Podiatr Med Assoc*. 2005;95:542–549.
24. Di Chiacchio N, Kadunc BV, Trindade de Almeida AR, et al. Treatment of transverse overcurvature of the nail with a plastic device: measurement of response. *J Am Acad Dermatol*. 2006;55:1081–1084.
25. Perrin C. The 2 clinical subbands of the distal nail unit and the nail isthmus. Anatomical explanation and new physiological observations in relation to the nail growth. *Am J Dermatopathol*. 2008;30:216–221.
26. Johnson M, Shuster S. Determinants of nail thickness and length. *Br J Dermatol*. 1994;130:195–198.
27. Cohen PR. The lunula. *J Am Acad Dermatol*. 1996;34:943–953; quiz 954–956.
28. Perrin C, Michiels JF, Pisani A, et al. Anatomic distribution of melanocytes in normal nail unit: an immunohistochemical investigation. *Am J Dermatopathol*. 1997;19:462–467.
29. Moll I, Moll R. Merkel cells in ontogenesis of human nails. *Arch Dermatol Res*. 1993;285:366–371.
30. Johnson M, Comaish JS, Shuster S. Nail is produced by the normal nail bed: a controversy resolved. *Br J Dermatol*. 1991;125:27–29.
31. Standing S. Skin and skin appendages. In: Standing S, ed. *Gray's Anatomy: The Anatomical Basis of Clinical Practice*. 39th ed. Edinburgh: Elsevier Churchill Livingstone; 2005:157–178.
32. Kosaka M, Kusuhara H, Mochizuki Y, et al. Morphologic study of normal, ingrown, and pincer nails. *Dermatol Surg*. 2010;36:31–38.
33. Xu B, Chen X. The role of mechanical stress on the formation of a curly pattern of human hair. *J Mech Behav Biomed Mater*. 2011;4:212–221.
34. Bernard BA. Hair shape of curly hair. *J Am Acad Dermatol*. 2003;48(6 Suppl):S120–S126.
35. Krause K, Foitzik K. Biology of the hair follicle: the basics. *Semin Cutan Med Surg*. 2006;25:2–10.
36. Zaias N, ed. *The Nail in Health and Disease*. 2nd ed. Norwalk: Appleton and Lange; 1980.
37. Salem A, Al Mokadem S, Attwa E, et al. Nail changes in chronic renal failure patients under haemodialysis. *J Eur Acad Dermatol Venereol*. 2008;22:1326–1331.
38. Nobuhiko H. Pathogenesis of the spooning. *Skin Res*. 1985;27:29–34.
39. Bentley-Phillips B, Bayles MA. Occupational koilonychia of the toe nails. *Br J Dermatol*. 1971;85:140–144.
40. Cornelius CE III, Shelley WB. Pincer nail syndrome. *Arch Surg*. 1968;96:321–322.
41. de Berker D, Carmichael AJ. Congenital alternate nail dystrophy. *Br J Dermatol*. 1995;133:336–337.
42. Chapman RS. Letter: overcurvature of the nails—an inherited disorder. *Br J Dermatol*. 1973;89:317–318.
43. Baran R, Dawber RPR. *Diseases of the Nail and Their Management*. 3rd ed. Boston, MA: Blackwell Science; 2001:496–499.
44. Baran R, Haneke E, Richert B. Pincer nails: definition and surgical treatment. *Dermatol Surg*. 2001;27:261–266.
45. Shionaya K. Pincer nail and ingrown nail. *J Joint Surg*. 2009;28:91–97.
46. DuVries HL. Diseases and deformities of the toenails. In: Inman VT, ed. *Surgery of the Foot*. St. Louis: The CV Mosby; 1959:204–222.
47. Suzuki K, Yagi I, Kondo M. Surgical treatment of pincer nail syndrome. *Plast Reconstr Surg*. 1979;63:570–573.
48. Brown RE, Zook EG, Williams J. Correction of pincer-nail deformity using dermal grafting. *Plast Reconstr Surg*. 2000;105:1658–1661.
49. Plusjé LG. Pincer nails: a new surgical treatment. *Dermatol Surg*. 2001;27:41–43.
50. Aksakal AB, Akar A, Erbil H, et al. A new surgical therapeutic approach to pincer nail deformity. *Dermatol Surg*. 2001;27:55–57.
51. Baran R, Haneke E, Richert B. Pincer nails: definition and surgical treatment. *Dermatol Surg*. 2001;27:261–266.
52. Haneke E. Pincer nail. In: Krull EA, Zook EG, Baran R, et al, eds. *Nail Surgery: A Text and Atlas*. Philadelphia: Lippincott Williams & Wilkins; 2001:168–171.
53. Hatoko M, Iioka H, Tanaka A, et al. Hard-palate mucosal graft in the management of severe pincer-nail deformity. *Plast Reconstr Surg*. 2003;112:835–839.
54. Zook EG, Chalekson CP, Brown RE, et al. Correction of pincer-nail deformities with autograft or homograft dermis: modified surgical technique. *J Hand Surg Am*. 2005;30:400–403.
55. Effendy I, Ossowski B, Happel R. [Pincer nail. Conservative correction by attachment of a plastic brace]. *Hautarzt* 1993;44:800–802.

56. Kim KD, Sim WY. Surgical pearl: nail plate separation and splint fixation—a new noninvasive treatment for pincer nails. *J Am Acad Dermatol*. 2003;48:791–792.
57. Umeda T, Nishioka K, Ohara K. Ingrown toenails: an evaluation of elevating the nail bed-periosteal flap. *J Dermatol*. 1992;19:400–403.
58. Pettine KA, Cofield RH, Johnson KA, et al. Ingrown toenail: results of surgical treatment. *Foot Ankle* 1988;9:130–134.
59. Robb JE, Murray WR. Phenol cauterization in the management of ingrowing toenails. *Scott Med J*. 1982;27:236–239.
60. Leshin B, Whitaker DC. Carbon dioxide laser matricectomy. *J Dermatol Surg Oncol*. 1988;14:608–611.
61. Nishioka K, Katayama I, Kobayashi Y, et al. Taping for embedded toenails. *Br J Dermatol*. 1985;113:246–247.
62. Arai H, Arai T, Nakajima H, et al. Formable acrylic treatment for ingrowing nail with gutter splint and sculptured nail. *Int J Dermatol*. 2004;43:759–765.
63. Schulte KW, Neumann NJ, Ruzicka T. Surgical pearl: nail splinting by flexible tube—a new noninvasive treatment for ingrown toenails. *J Am Acad Dermatol*. 1998;39(4, Part 1): 629–630.