

Point-of-Care Tissue Oxygenation Assessment with SnapshotNIR for Alloplastic and Autologous Breast Reconstruction

William R. Moritz, MD
John Daines, BS
Joani M. Christensen, MD
Terence Myckatyn, MD
Justin M. Sacks, MD, MBA
Amanda M. Westman, PhD

Background: In breast reconstruction, mastectomy and free flaps are susceptible to vascular compromise and tissue necrosis. The SnapshotNIR device (Kent Imaging, Calgary, AB, Canada) utilizes near-infrared spectroscopy to measure tissue oxygen saturation (StO₂) and hemoglobin concentration. Here, we report on the use of this device for StO₂ monitoring among patients receiving alloplastic or autologous breast reconstruction.

Methods: Patients receiving immediate alloplastic reconstruction after mastectomy or autologous reconstruction were enrolled. Preoperative, intraoperative, and postoperative images were taken of the flaps. StO₂ and hemoglobin were measured at the following locations: superior and inferior breast, free flap skin paddle (when applicable), and un-operated control skin. Linear mixed effects model for repeated measurements was used to model measurements to estimate the area effect difference across time, time effect difference across area, and pairwise comparisons between two areas at each time point.

Results: Thirty-two breasts underwent alloplastic reconstruction; 38 breasts underwent autologous reconstruction. No enrollees developed skin necrosis. StO₂ was highest after mastectomy and closure in alloplastic reconstructions. StO₂ was observed to decline at follow-up in autologous reconstructions. Mean preoperative StO₂ was highest in breasts that had previously undergone mastectomy and alloplastic reconstruction.

Conclusions: The SnapshotNIR device detected normal spatial and temporal differences in tissue oxygenation over the operative course of alloplastic and autologous breast reconstruction. A multi-institutional, prospective clinical trial is needed to determine the sensitivity and specificity of this device for detecting skin flap necrosis. (*Plast Reconstr Surg Glob Open* 2023; 11:e5113; doi: [10.1097/GOX.0000000000005113](https://doi.org/10.1097/GOX.0000000000005113); Published online 11 July 2023.)

INTRODUCTION

Both alloplastic and autologous breast reconstruction carry the risks of malperfusion and tissue necrosis. During mastectomy, resection of native breast tissue removes the deep blood supply to the skin overlying the breast resulting in relative hypovascularity. Mastectomy

flap necrosis can occur in up to 20% of alloplastic reconstructions after simple mastectomy.¹ These rates can be even higher in skin- or nipple-sparing mastectomy.²⁻⁷ In alloplastic reconstruction, tissue expander overfilling can put the flaps under tension, further reducing perfusion.⁵ Autologous reconstructions carry the additional risk of total flap failure from occlusion of the vascular pedicle⁸ or fat necrosis from hypoperfusion of flap tissue.⁹ Patient-specific factors such as smoking status, diabetes, mastectomy technique, flap thickness, and flap length can influence an individual's risk of necrosis.^{7,10} This heterogeneity can make it difficult to assess individual patient risk of flap necrosis. Clinical assessment

From the Division of Plastic and Reconstructive Surgery, Department of Surgery, Washington University School of Medicine, St. Louis, Mo.

Received for publication March 10, 2023; accepted May 10, 2023.

Presented at the 2023 Meeting for the American Society for Reconstructive Microsurgery, Jan 20–24, 2023, Miami, Florida.

Copyright © 2023 The Authors. Published by Wolters Kluwer Health, Inc. on behalf of The American Society of Plastic Surgeons. This is an open-access article distributed under the terms of the [Creative Commons Attribution-Non Commercial-No Derivatives License 4.0 \(CCBY-NC-ND\)](https://creativecommons.org/licenses/by-nc-nd/4.0/), where it is permissible to download and share the work provided it is properly cited. The work cannot be changed in any way or used commercially without permission from the journal.

DOI: [10.1097/GOX.0000000000005113](https://doi.org/10.1097/GOX.0000000000005113)

Disclosure statements are at the end of this article, following the correspondence information.

Related Digital Media are available in the full-text version of the article on www.PRSGlobalOpen.com.

is widely relied upon when evaluating flap tissue perfusion. However, clinical assessment alone can be inadequate for predicting free flap failure and mastectomy flap necrosis.^{11–13} For these reasons, more objective methods of evaluating flap perfusion have entered the clinical space.

Systems utilizing laser-assisted fluorescein or indocyanine green angiography, like SPY Elite (Stryker, Kalamazoo, Mich.), have been frequently adopted as intraoperative perfusion assessment tools. Utilizing an intravenous dye injection, these systems facilitate real-time perfusion assessment, allowing surgeons to identify and resect at-risk tissues. These systems have been shown to be effective at detecting and preventing mastectomy flap necrosis^{4,14–20} and free flap fat necrosis.^{9,21} However, laser-assisted angiography is costly. In addition to the price of equipment, which can amount to \$300,000 for a single system,²² the estimated per-use cost can be \$650 per patient, depending on the institution (price estimates for USA).¹⁷ This may be cost-prohibitive for some health-care systems. Additionally, the equipment can be bulky; the systems are primarily used in the operating room; and intravenous dye can cause allergic reactions in some patients.²³

Near-infrared spectroscopy (NIRS)-based systems are potentially useful tools for tissue perfusion assessment²⁴ and have been deployed in the clinical setting for several years.^{13,25,26} These systems utilize near-infrared light to assess tissue oxygen saturation (StO₂). Continuous peripheral free flap monitors utilizing NIRS technology, like the T.Ox (ViOptix Inc., Newark, Calif.), allow for continuous noninvasive perfusion monitoring and have been shown to have excellent sensitivity and specificity for vascular compromise.²⁷ However, these devices are most commonly used for free flap monitoring during the early postoperative period and for sampling a small area of tissue. There has been new interest in adapting NIRS technology for handheld tools that allow clinicians to rapidly evaluate tissue perfusion at the point-of-care. The handheld Intra.Ox (ViOptix Inc., Newark, Calif.) has detected significant differences in tissue oxygenation saturation associated with risk for flap necrosis in preclinical studies.^{28,29} However, both T.Ox and Intra.Ox measure StO₂ at a single point of interest and do not allow users to appreciate oxygenation patterns across an entire flap.

The SnapshotNIR (Kent Imaging, Calgary, AB, Canada) addresses a limitation of current NIRS-based systems by combining NIRS with imaging technology to evaluate patterns of tissue oxygenation within a wide area of interest. This allows surgeons to evaluate perfusion differences over a wider area than possible with the existing ViOptix devices. During image capture, SnapshotNIR produces a red, green, and blue image, an image depicting StO₂ measurements within every pixel, and three hemoglobin reflectance images (oxyhemoglobin, deoxyhemoglobin, and total hemoglobin). The device is handheld, lightweight, instantaneous, and easy to use, allowing for its use in the operating room, hospital floor, or clinic. Unlike traditional clinical examinations, SnapshotNIR provides an objective means to evaluate oxygenation. It is

Takeaways

Question: Can the SnapshotNIR detect spatial and temporal differences in tissue oxygenation over the intraoperative and postoperative period among patients receiving breast reconstruction?

Findings: No patients developed skin flap necrosis. Tissue oxygen saturation and oxyhemoglobin were highest after mastectomy and closure in alloplastic reconstruction. Tissue oxygen saturation declined at follow-up in autologous reconstructions.

Meaning: Tissue oxygen saturation variations reported here reflect normal physiologic responses to breast reconstruction and could contextualize abnormal-appearing changes in oxygenation observed by physicians hoping to deploy this device in their surgical practice.

significantly cheaper than the laser-assisted angiography systems and has no per-use cost. Additionally, measurements are not confounded by ambient temperature or humidity, as with thermal imaging systems like FLIR ONE (FLIR Systems, Inc., Wilsonville, Oreg.).^{30,31} Previous work has shown it not to be inferior to laser-assisted indocyanine green angiography at predicting skin flap necrosis in a rat model³² and it can detect oxygenation differences in tissues that go on to develop skin flap necrosis in the clinical setting.²² In this prospective study, we used SnapshotNIR to detect oxygenation differences observed throughout the course of alloplastic and autologous reconstruction.

METHODS

Patients

Institutional review board approval was obtained (IRB #: 202103145) to recruit adult patients undergoing breast reconstruction at the Washington University School of Medicine (St. Louis, Mo.). Patients receiving immediate reconstruction with tissue expanders or implants after mastectomy (alloplastic reconstruction) or those undergoing free flap reconstruction were recruited for study participation. There were no exclusion criteria outside of patients who did not consent to be part of this study. Written consent was obtained from all participants, including consent for photography.

Study subjects were imaged throughout the course of their care. When alloplastic reconstruction was performed, images were then taken at the following time points: (1) preoperatively and intraoperatively, (2) after mastectomy, (3) after implant or tissue expander placement and closure, and (4) at a follow-up visit within 6 weeks of surgery. When autologous reconstruction was performed, mastectomy flaps and free flaps were imaged at the following time points: (1) preoperatively and intraoperatively, (2) after vascular anastomosis, (3) after closure, and (4) at a follow-up visit within 6 weeks of surgery. Clinical care decisions were based solely on clinical evaluation. The surgeons and clinical team were blinded to the SnapshotNIR device measurements. All images were taken

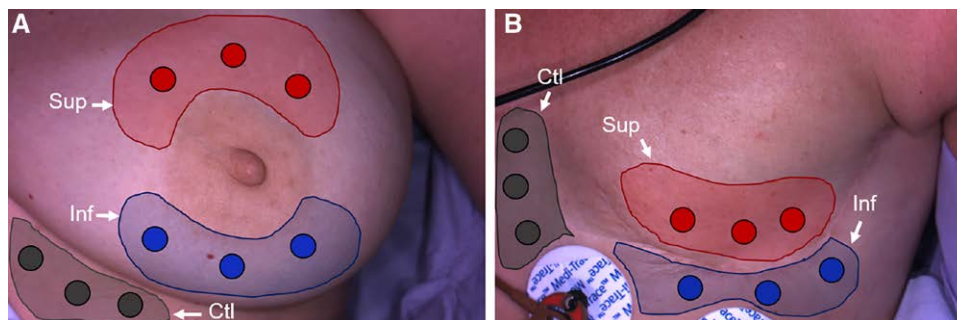


Fig. 1. Measurement selection. Two preoperative images are shown. Three measurements are taken within three areas of interest: superior (Sup, red), inferior (Inf, blue), and unoperated control skin (Ctl, black). A, If patients underwent a nipple-sparing mastectomy and the NAC was preserved throughout enrollment, measurements were taken in the following areas: (i) superior to the NAC, (ii) inferior to the NAC. B, If the patient underwent a skin-sparing mastectomy, simple mastectomy, or modified radical mastectomy, measurements were taken from (i) the superior (above the incision) and (ii) inferior skin flaps. Control areas were defined as areas not affected by the procedure and with similar tissue tone and quality. Skin that was shadowed, reflective, or otherwise obscured was avoided.

by a member of the research study not involved in clinical decision-making. Patient demographics were recorded, and postoperative complications (mastectomy flap necrosis, surgical site infection, seroma, hematoma, wound dehiscence, and implant exposure) were monitored for 6 weeks after reconstruction.

Image Capture

Images were captured with the SnapshotNIR system (Kent Imaging Inc, Calgary, AB, Canada) by holding the device parallel to the surgical site at a distance of 30 cm, allowing the user to assess the perfusion characteristics within a 15 cm × 20 cm field of view. The SnapshotNIR system automatically takes a digital color picture at the same time as that of the StO₂ image, and both images are spatially matched.

Image Analysis

A blinded reviewer (W.R.M.) selected areas of the color images for analysis. If patients underwent a nipple-sparing mastectomy, and the nipple areola complex (NAC) was preserved throughout enrollment, measurements were taken in the following areas: (1) superior to the NAC and (2) inferior to the NAC (Fig. 1A). If the patient underwent a skin-sparing mastectomy, simple mastectomy, or modified radical mastectomy, measurements were taken from (1) the superior (above the incision) and (2) inferior skin flaps (Fig. 1B). If a vertical or inframammary incision was utilized for the mastectomy, measurements were taken at the superior and inferior portions of the breast pocket. This was consistent in both alloplastic and autologous reconstruction. Measurements of flap skin were taken at (1) the donor site (preoperative) and (2) the recipient site (anastomosis, closure, follow-up). Control areas were defined as areas not affected by the procedure and with similar tissue tone and quality. Within each area of interest on the color image, three locations were chosen for measurement. Areas of skin that were shadowed, reflective, or otherwise obscured

were avoided. Measurements within each area of interest were averaged. Measurements included StO₂, deoxyhemoglobin (deoxyHb), oxyhemoglobin (oxyHb), and total hemoglobin (total Hb).

Statistical Analysis

Linear mixed effects model for repeated measurements was used to model measurements (StO₂, total Hb, oxyHb, and deoxyHb) with effect of area, time, and area*time interaction to estimate the area effect difference across time, time effect difference across area, and pairwise comparisons between two areas at each time point. For StO₂ values, the least square mean for the area difference averaged across time and averaged across area were derived with standard error and *P* value. For all measurement values, the least square mean for the difference between areas at each individual time point were derived with *P* values and adjusted *P* values using Tukey-Kramer Adjustment. For visualization, the least square mean estimate of each area and associated 95% confidence interval were plotted. Statistical analysis was performed by the Washington University Biostatistics Core (St. Louis, Mo.).

Post-hoc subgroup analysis of preoperative StO₂ measurements was also performed. Breasts scheduled to receive autologous or alloplastic reconstruction were separated into the following subgroups: (1) breasts that had not previously undergone mastectomy (Native Breast Tissue), (2) breasts that had previously undergone mastectomy without reconstruction (+Mast, -TE/Imp), and (3) breasts that had previously undergone mastectomy with implant or tissue expander placement (+Mast, +TE/Imp). A Shapiro-Wilks test was used to determine normality. An ordinary one-way ANOVA was used for pairwise comparisons of preoperative StO₂ measurements. Results were reported as mean and SD.

RESULTS

A total of 42 individuals were enrolled in this study between July 2021 and July 2022. One individual received

alloplastic reconstruction, and then autologous reconstruction, and was enrolled twice, once for each type of reconstruction (43 enrollees). One enrollee could not be imaged on the day of surgery and was removed from the study. Images taken from three enrollees could not be analyzed due to high skin melanin content (Fitzpatrick 5). The newer algorithm on the SnapshotNIR device includes melanin correction; however, the algorithm on the device was continuously being improved throughout the study period and, for consistency, the data from these subjects could not be included in analysis.

Of the remaining 39 enrollees, 18 underwent alloplastic reconstruction on 32 breasts; 21 underwent free autologous free flap reconstruction in 38 breasts with 39 flaps. (See tables, Supplemental Digital Content 1, which displays (A) demographics and (B) number of averaged measurements taken by region and time point. (C) Statistical analysis between areas of interest at each time point for StO₂, total Hb, oxyHb, and deoxyHb measurements. (D) Influence of prior mastectomy (Mast) and alloplastic reconstruction (TE/Imp) on preoperative StO₂ measurements (mean ± SD). <http://links.lww.com/PRSGO/C651>.) One autologous reconstruction was performed using two transverse upper gracilis flaps to the internal mammary artery. All other autologous reconstructions were performed with singular deep inferior epigastric perforator or transverse rectus abdominis flaps. All free flaps included a cutaneous component. All remaining subjects had Fitzpatrick scores of one to three. There were no instances of skin necrosis. There was one instance of fat necrosis (Table 1). Averaged measurements were obtained from each region of interest when possible. The number of averaged measurements per area of interest can be found in Supplemental Digital Content 1B. (See tables, Supplemental Digital Content 1, <http://links.lww.com/PRSGO/C651>.)

During alloplastic and autologous reconstructions, measurements from the SnapshotNIR device varied across time. Given that there were no instances of skin flap necrosis, the measurement variations were not indicative of underlying physiologic issues. For both types of reconstruction, when averaged across time, the StO₂ values of the control area were significantly lower than superior and inferior areas (Figs. 2–4). For alloplastic reconstructions, when averaged across area, StO₂ measurements were higher postmastectomy and after closure compared

with measurements taken preoperatively and at follow-up ($P < 0.0001$). For autologous reconstruction, when averaged across area, the StO₂ values at follow-up were significantly lower than at earlier timepoints ($P < 0.0001$). Statistical analysis between areas at each time point can be found in Supplemental Digital Content 1C. (See tables, Supplemental Digital Content 1, <http://links.lww.com/PRSGO/C651>.)

Post-hoc subgroup analysis of preoperative StO₂ measurements demonstrated that preoperative StO₂ was significantly higher in breasts that had undergone implant or tissue expander placement after a previous mastectomy (Fig. 5). (See tables, Supplemental Digital Content 1, <http://links.lww.com/PRSGO/C651>.)

DISCUSSION

The purpose of this study was to report on changing oxygenation patterns seen in breast reconstruction to guide surgeons interested in using the SnapshotNIR device as a noninvasive adjunct for clinical evaluation of tissue oxygenation. Early detection of vascular compromise remains an important goal for breast reconstruction. Here, we present the use of NIRS-based technology for tissue perfusion monitoring throughout the course of operative care. This device has been previously shown to detect oxygenation differences in chronic wounds,^{33–35} critical limb ischemia,³⁶ and skin flap necrosis.^{22,32} Additionally, it is affordable, small and lightweight, does not require an intravenous dye (as with laser-assisted angiography), and can be used as frequently as desired without a necessary washout time. Our study reports on the expected changes in oxygenation, as measured by the SnapshotNIR device, throughout the course of surgical care after mastectomy and breast reconstruction.

Patients undergoing mastectomy and immediate alloplastic breast reconstruction, or autologous reconstruction were prospectively enrolled in this study. To evaluate changing perfusion patterns observed over operative care, SnapshotNIR was used to image breast and free flap tissue before, during, and after mastectomy and/or reconstruction. Preoperatively, breasts that had undergone prior mastectomy and alloplastic reconstruction exhibited a higher mean StO₂ than those that had not yet undergone mastectomy or those that had undergone mastectomy without reconstruction. These findings may be explained by angiogenesis secondary to tissue expansion.³⁷ In alloplastic reconstructions, mastectomy flap StO₂ increased after mastectomy, remaining elevated throughout the operation but returning to baseline at follow-up. This mirrors an observed increase in oxyhemoglobin measurements. Superior and inferior StO₂ and oxyhemoglobin measurements were significantly higher than control tissue intraoperatively. These changes could reflect transient cutaneous vasodilation after mastectomy. Alternatively, observed elevations in oxyhemoglobin and StO₂ could stem from poor venous drainage rather than from elevated arterial flow. Resection of the deep and superficial veins of the breast during mastectomy may result in transient venous

Table 1. Complications (by Breast)

Complication	Alloplastic (N = 32), n (%)	Autologous (N = 38), n (%)
Skin necrosis	0	0
Cellulitis	0	1 (2.6)
Contact dermatitis	2 (6.3)	0
Dehiscence	0	5 (13.2)
Epidermolysis	2 (6.3)	1 (2.6)
Hematoma	1 (3.1)	0
Fat necrosis	0	1 (2.6)
Seroma	1 (3.1)	0
Surgical site infection	4 (12.5)	0

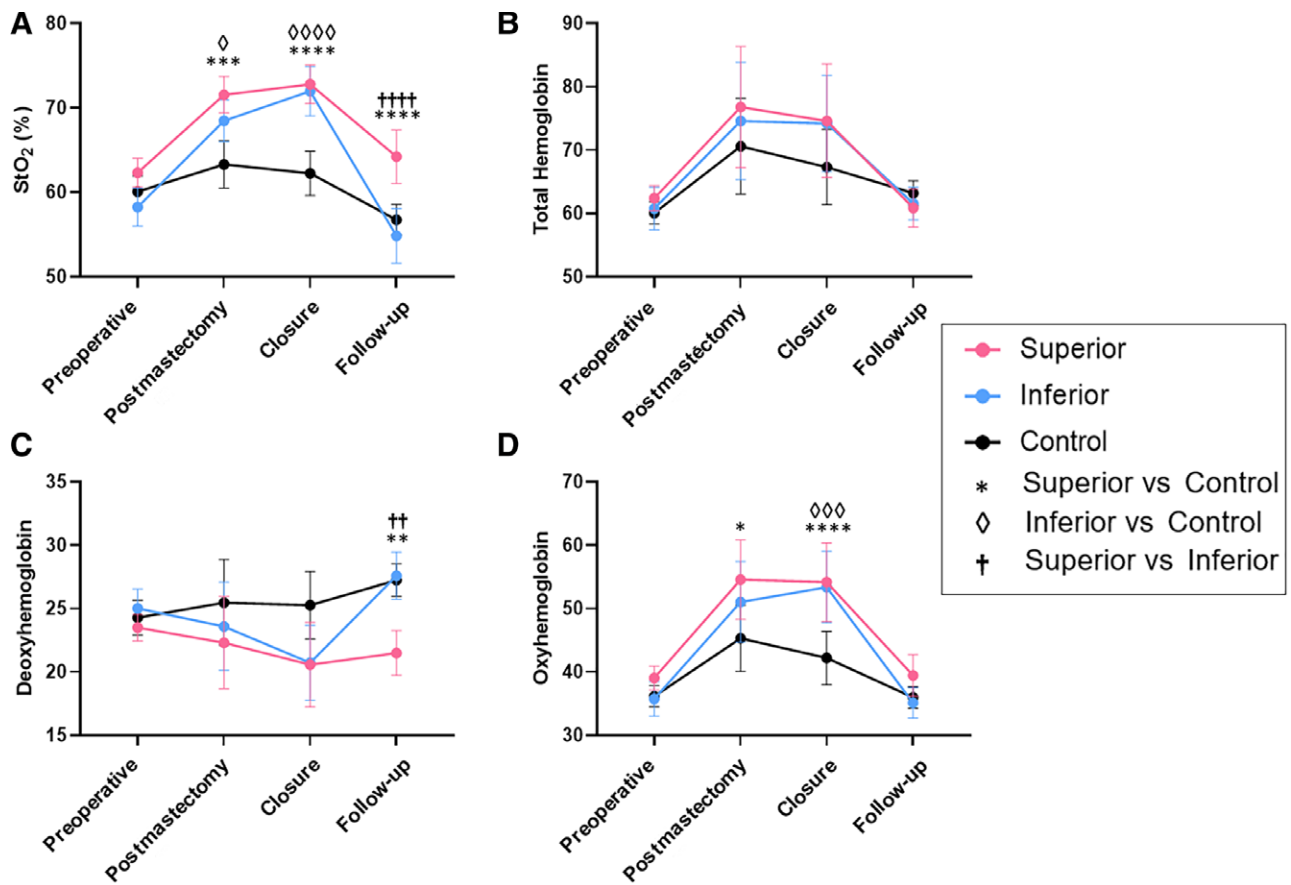


Fig. 2. Oxygenation time course of alloplastic mastectomy flaps. In alloplastic mastectomy flaps, changes in (A) StO₂, (B) total hemoglobin (C) deoxyhemoglobin, and (D) oxyhemoglobin during operative care and follow-up in the superior (pink) and inferior (blue) skin flaps and control, un-operated (black) tissue (least square mean \pm 95% CI). Significant differences in pairwise comparisons are labeled (**** P < 0.0001, *** P < 0.001, ** P < 0.01, * P < 0.05).

congestion, which may normalize over the postoperative period as arterial flow adapts to the new metabolic demands of the remaining breast tissue and skin. These transient increases in StO₂ could mask obvious hypoperfusion in flaps at risk of developing necrosis. To evaluate a tissue's risk of necrosis, it may be important for surgeons to consider the expected oxygenation patterns at the time of imaging, as these tissues may only exhibit relative hypoperfusion.

For autologous reconstructions, we did not observe the same significant increase in mastectomy flap StO₂ between images taken preoperatively and at closure, averaged over area. However, superior mastectomy flap StO₂ was higher than control tissue before surgery, after anastomosis, and at closure. As most autologous reconstructions were second-stage procedures, the elevated preoperative StO₂ is likely related to preoperative tissue expansion or implant placement. Additionally, we observed a significant decrease in StO₂ between closure and follow-up imaging averaged over area. This corresponded with a significant increase in deoxyhemoglobin. As neither mastectomy flaps nor free flaps exhibited obvious signs of venous congestion at follow-up imaging, and because we observed a similar increase in control deoxyhemoglobin over this same

time interval, it is possible that these observed changes reflect differences in skin temperature. We observed no instances of skin flap necrosis in either autologous or alloplastic reconstructions. We hypothesize that the changes in tissue oxygenation detected by the SnapshotNIR device in this study reflect normal physiology.

Although no patients enrolled in the study developed skin flap necrosis, the SnapshotNIR device did identify perfusion changes intraoperatively and at follow-up for one patient who developed fat necrosis. This patient was a 52-year-old woman who presented for a prophylactic, unilateral skin-sparing mastectomy with immediate deep inferior epigastric perforator flap-based reconstruction. She had a BMI of 38.79 kg/m² and was a former smoker. Preoperative measurements taken at the flap donor site showed an StO₂ of 53%. This study was observational, and the surgeon was blinded to all measurements. After microvascular anastomosis, the flap appeared pale and cool to the touch. The SPY Elite system revealed absent perfusion; images taken by SnapshotNIR also reflected poor perfusion, with low StO₂ and oxyhemoglobin measurements. (See figure, Supplemental Digital Content 2, which displays the color (RGB) and StO₂ images following vascular anastomosis, after closure, and at follow-up following

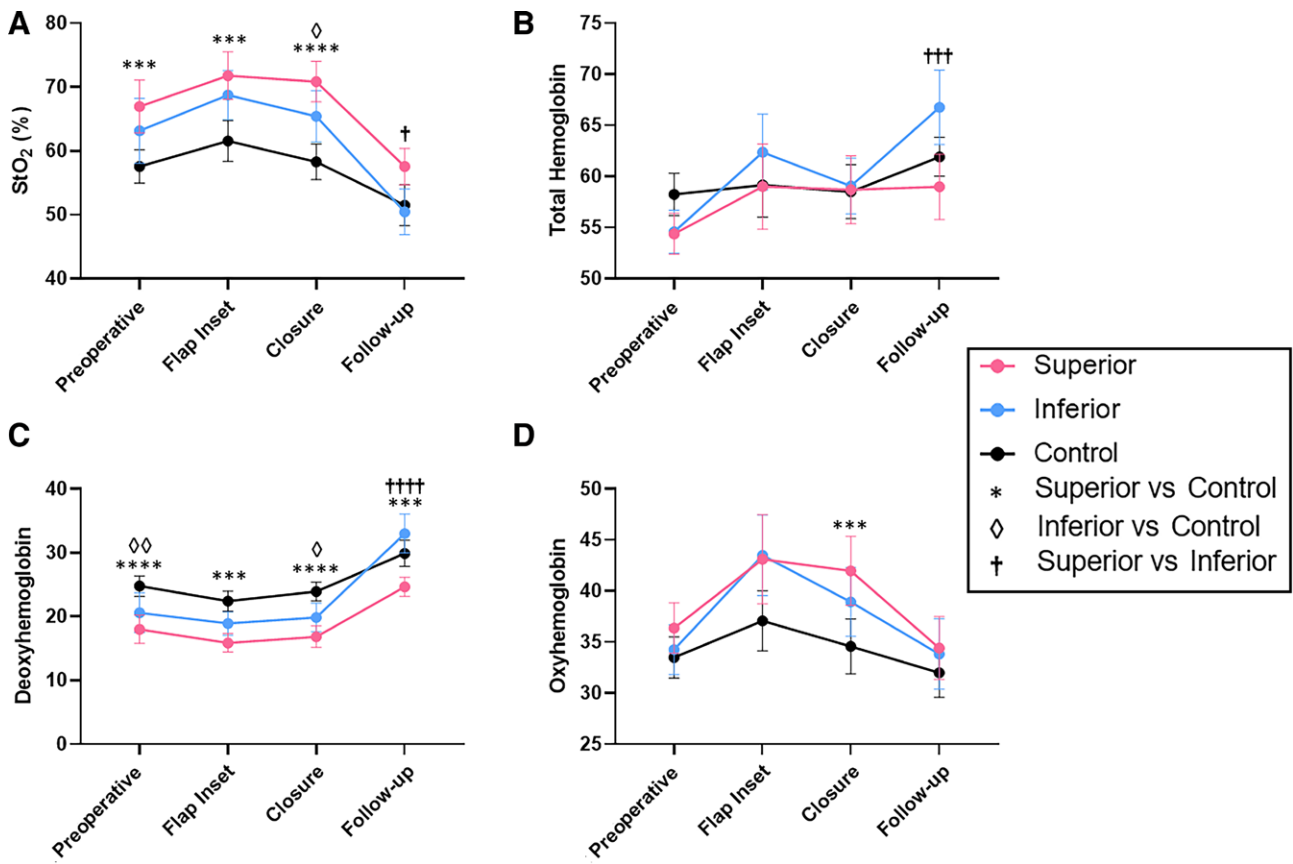


Fig. 3. Oxygenation time course of autologous mastectomy flaps. In autologous mastectomy flaps, changes in (A) StO₂, (B) total hemoglobin (C) deoxyhemoglobin, and (D) oxyhemoglobin during operative care and follow-up in the superior (pink) and interior (blue) skin flaps and control, un-operated (black) tissue (least square mean ± 95% CI). Significant differences in pairwise comparisons are labeled (*****P* < 0.0001, ****P* < 0.001, ***P* < 0.01, **P* < 0.05).

autologous reconstruction. Three weeks after the follow-up images, the breast developed liquefactive fat necrosis. <http://links.lww.com/PRSGO/C652>.)

Improvements in perfusion and oxygenation were observed with the SPY Elite and SnapshotNIR after flap repositioning. After closure, SnapshotNIR showed free flap oxygenation comparable to control tissue. Physical examination at the patient’s follow-up visit 1 week later revealed a healthy, well-perfused flap. However, images captured by SnapshotNIR indicated poor perfusion, with low StO₂ and oxyhemoglobin measurements. Three weeks later, the patient developed fat necrosis, requiring revision surgery. Although further research is required to determine if this device can predict fat necrosis in this context, this case illustrates one way that the SnapshotNIR device may be used for clinical evaluation in the future: identifying ischemia in the operating room and detecting at-risk tissues in the clinic before necrosis develops. Skin and fat have different metabolic demands, and monitoring each tissue type is of clinical importance with many flaps. Noninvasive imaging technologies like the SnapshotNIR may offer a cost-effective method of evaluating flaps for fat necrosis, a possibility that should be explored with future research.

This study builds on the literature describing the use of this device in breast reconstruction. In 2020, Hill et

al found that the intraoperative StO₂ measurements of necrotic skin flaps were 17.5% lower than unoperated control tissue from the same patients.²² Tissues at risk of necrosis had intraoperative StO₂ measurements 6.9% lower than control tissue. However, only 52% of these flaps were mastectomy flaps, and intraoperative StO₂ was only reported for flaps that eventually developed necrosis. We cannot determine if similar differences in StO₂ were observed in flaps that did not develop necrosis. As we have demonstrated in this article, SnapshotNIR detects oxygenation differences both spatially and over time in healthy tissue. To predict skin flap necrosis, surgeons will need to differentiate these normal changes in perfusion from the abnormal changes that may indicate risk of necrosis. To date, no study has reported the expected changes in oxygenation detected by this device after mastectomy and breast reconstruction. In the absence of this information, changes in tissue oxygenation might be misinterpreted as signs of malperfusion. As the body of literature describing the use of SnapshotNIR in breast reconstruction continues to grow, the findings presented here will help guide surgeons as they integrate the device into their practice.

A limitation of this study is that StO₂ can be confounded by melanin content, meaning that our results may not be generalizable to the entire population. Images from three

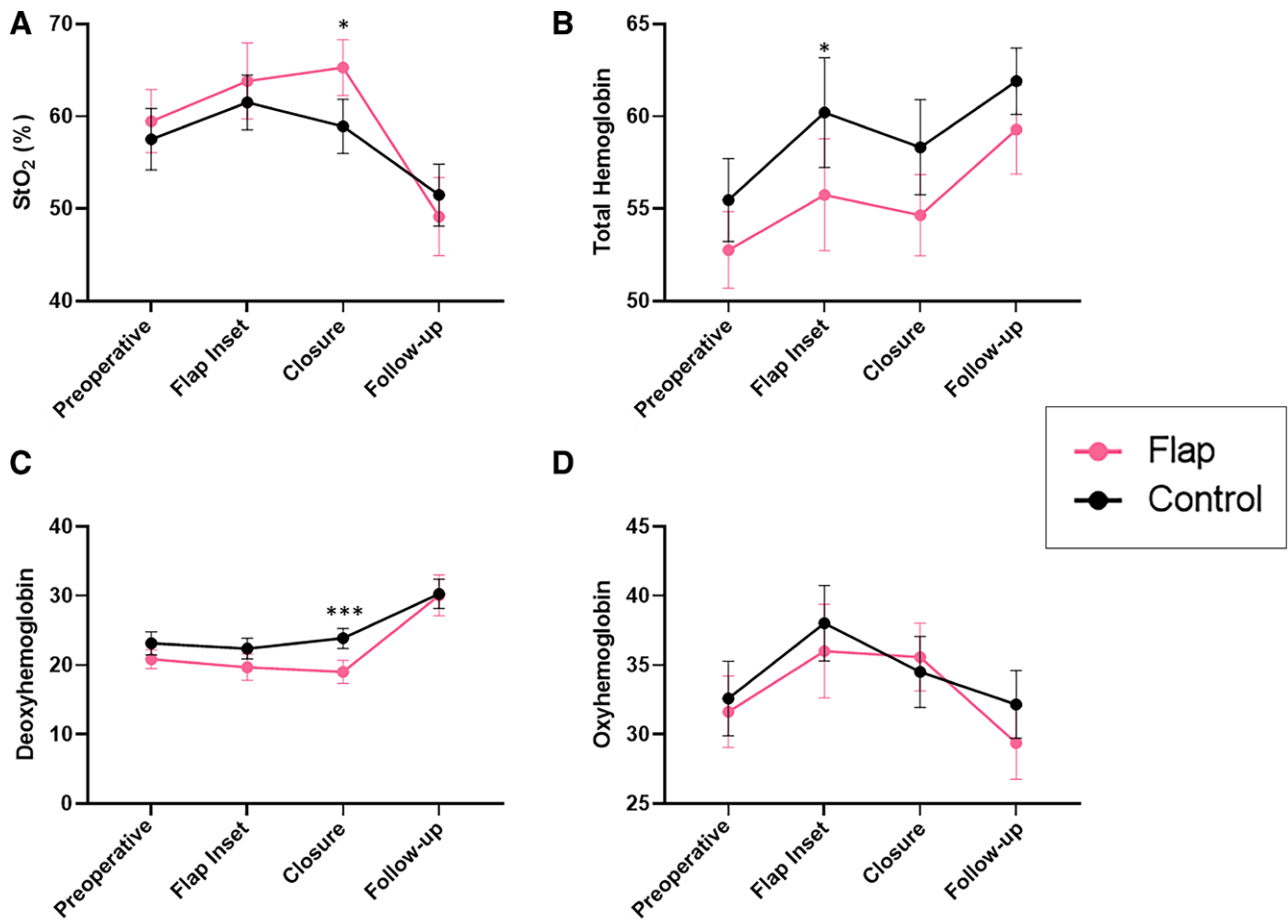


Fig. 4. Oxygenation time course of autologous free flaps. In autologous free flaps, changes in (A) StO₂, (B) total hemoglobin, (C) deoxyhemoglobin, and (D) oxyhemoglobin during operative care and follow-up in the free flap (pink) and control, un-operated (black) tissue (least square mean ± 95% CI). Significant differences in pairwise comparisons are labeled (*****P* < 0.0001, ****P* < 0.001, ***P* < 0.01, **P* < 0.05).

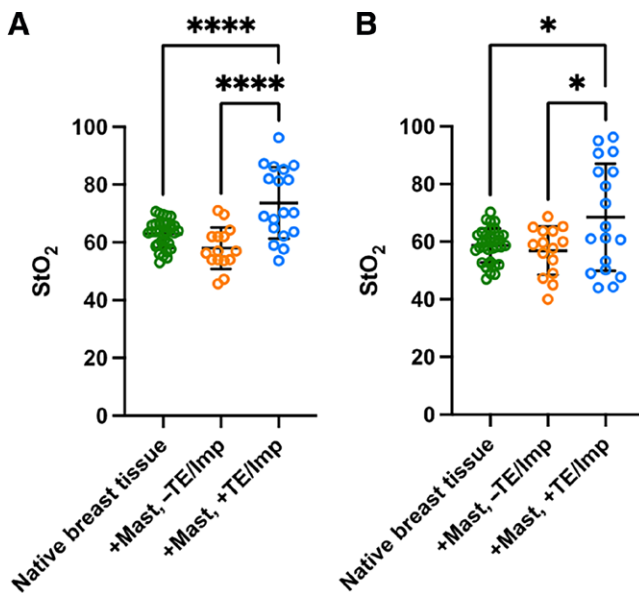


Fig. 5. Preoperative oxygenation comparison. Preoperative StO₂ measurements of the (A) superior and (B) inferior breast regions (mean ± SD; *****P* < 0.0001, **P* < 0.05).

individuals with high Fitzpatrick scores could not be analyzed due to limitations of the device. Ongoing research is focused on improving the device’s ability to accurately measure StO₂ across all skin types. Our future work will focus on deploying this device in other surgical scenarios when risk of skin flap necrosis is high, such as breast reduction. Furthermore, a multi-institutional, prospective clinical trial is needed to determine the sensitivity and specificity of this device for detecting skin flap necrosis.

CONCLUSIONS

Early detection of ischemia, venous congestion, and necrosis is an essential component of the postoperative period after breast reconstruction. SnapshotNIR allows for point-of-care perfusion assessment. It is fast, easy to use, and relatively inexpensive. Here, we report the changes in oxygenation, as measured by the SnapshotNIR device, observed throughout the course of surgical care for patients undergoing successful alloplastic and autologous reconstruction. This device may be a useful clinical tool for reconstructive surgeons, and further research is warranted to determine its ability to detect skin flap necrosis.

Amanda M. Westman, PhD

Department of Surgery

Division of Plastic and Reconstructive Surgery

Washington University School of Medicine

St. Louis, MO 63122

E-mail: a.m.westman@wustl.edu

DISCLOSURES

The SnapshotNIR devices used in this study were provided at no cost by Kent Imaging. Dr. Myckatyn receives investigator-initiated research funds from Sientra and RTI Surgical, and royalties from RTI Surgical. Dr. Sacks is a co-founder of LifeSprout Inc. (Baltimore, Md.) and holds an equity position. Dr. Sacks serves as a consultant for 3M. Dr. Westman receives research funds from 3M for preclinical studies. All the other authors have no financial interests to declare in relation to the content of this article.

ACKNOWLEDGMENTS

We thank the Alvin J. Siteman Cancer Center at Washington University School of Medicine and Barnes-Jewish Hospital in St. Louis, Missouri, for the use of the Biostatistics Shared Resource, which provided scientific computing for statistical analysis. The Siteman Cancer Center is supported in part by an NCI Cancer Center Support Grant #P30 CA091842, Eberlein, PI.

REFERENCES

- Sullivan SR, Fletcher DRD, Isom CD, et al. True incidence of all complications following immediate and delayed breast reconstruction. *Plast Reconstr Surg*. 2008;122:19–28.
- Wapnir I, Dua M, Kierny A, et al. Intraoperative imaging of nipple perfusion patterns and ischemic complications in nipple-sparing mastectomies. *Ann Surg Oncol*. 2014;12:100–106.
- Newman MI, Samson MC, Tamburrino JF, et al. Intraoperative laser-assisted indocyanine green angiography for the evaluation of mastectomy flaps in immediate breast reconstruction. *J Reconstr Microsurg*. 2010;26:487–492.
- Phillips BT, Lanier ST, Conkling N, et al. Intraoperative perfusion techniques can accurately predict mastectomy skin flap necrosis in breast reconstruction: results of a prospective trial. *Plast Reconstr Surg*. 2012;129:778–788.
- Mlodinow AS, Fine NA, Khavanin N, et al. Risk factors for mastectomy flap necrosis following immediate tissue expander breast reconstruction. *J Plast Surg Hand Surg*. 2014;48:322–326.
- Hultman CS, Daiza S. Skin-sparing mastectomy flap complications after breast reconstruction: review of incidence, management, and outcome patients and methods patient population between. *Ann Plast Surg*. 2003;50:249–255.
- Khavanin N, Qiu C, Darrach H, et al. Intraoperative perfusion assessment in mastectomy skin flaps: how close are we to preventing complications? *J Reconstr Microsurg*. 2019;35:471–478.
- Chen K, Mardini S, Chuang DCC, et al. Timing of presentation of the first signs of vascular compromise dictates the salvage outcome of free flap transfers. *Plast Reconstr Surg*. 2007;120:187–195.
- Hembs AS, Yan J, Zhu H, et al. Intraoperative assessment of diep flap breast reconstruction using indocyanine green angiography: reduction of fat necrosis, resection volumes, and postoperative surveillance. *Plast Reconstr Surg*. 2020;1:1e–10e.
- Kim JYS, Mlodinow AS, Khavanin N, et al. Individualized risk of surgical complications: an application of the breast reconstruction risk assessment score. *Plast Reconstr Surg Glob Open*. 2015;3:1–9.
- Olivier WAM, Hazen A, Levine JP, et al. Reliable assessment of skin flap viability using orthogonal polarization imaging. *Plast Reconstr Surg*. 2003;112:547–555.
- Diep GK, Hui JYC, Marmor S, et al. Postmastectomy reconstruction outcomes after intraoperative evaluation with indocyanine green angiography versus clinical assessment. *Ann Surg Oncol*. 2016;23:4080–4085.
- Lin SJ, Nguyen MD, Chen C, et al. Tissue oximetry monitoring in microsurgical breast reconstruction decreases flap loss and improves rate of flap salvage. *Plast Reconstr Surg*. 2011;127:1080–1085.
- Gurtner GC, Jones GE, Neligan PC, et al. Intraoperative laser angiography using the SPY system: review of the literature and recommendations for use. *Ann Surg Innov Res*. 2013;7:1.
- Sood M, Glat P. Potential of the SPY intraoperative perfusion assessment system to reduce ischemic complications in immediate postmastectomy breast reconstruction. *Ann Surg Innov Res*. 2013;7:1.
- Venturi ML, Mesbahi AN, Copeland-Halperin LR, et al. SPY Elite's ability to predict nipple necrosis in nipple-sparing mastectomy and immediate tissue expander reconstruction. *Plast Reconstr Surg Glob Open*. 2017;5:1–4.
- Kanuri A, Liu AS, Guo L. Whom should we SPY? A cost analysis of laser-assisted indocyanine green angiography in prevention of mastectomy skin flap necrosis during prosthesis-based breast reconstruction. *Plast Reconstr Surg*. 2014;133:448e–454e.
- Griffiths M, Chae MP, Rozen WM. Indocyanine green-based fluorescent angiography in breast reconstruction. *Gland Surg*. 2016;5:133–149.
- Munabi NCO, Olorunnipa OB, Goltsman D, et al. The ability of intra-operative perfusion mapping with laser-assisted indocyanine green angiography to predict mastectomy flap necrosis in breast reconstruction: a prospective trial. *J Plast Reconstr Aesthet Surg*. 2014;67:449–455.
- Duggal CS, Madni T, Losken A. An outcome analysis of intraoperative angiography for postmastectomy breast reconstruction. *Aesthet Surg J*. 2014;34:61–65.
- Yoo A, Palines PA, Mayo JL, et al. The impact of indocyanine green angiography on fat necrosis in deep inferior epigastric perforator flap breast reconstruction. *Ann Plast Surg*. 2022;88:415–419.
- Hill WF, Webb C, Monument M, et al. Intraoperative near-infrared spectroscopy correlates with skin flap necrosis: a prospective cohort study. *Plast Reconstr Surg Glob Open*. 2020;8:1–7.
- Su Z, Ye P, Teng Y, et al. Adverse reaction in patients with drug allergy history after simultaneous intravenous fundus fluorescein angiography and indocyanine green angiography. *J Ocul Pharmacol Ther*. 2012;28:410–413.
- Irwin MS, Thorniley MS, Dore CJ, et al. Near infra-red spectroscopy: a non-invasive monitor of perfusion and oxygenation within the microcirculation of limbs and flaps. *Br J Plast Surg*. 1995;48:14–22.
- Lohman RF, Langevin CJ, Bozkurt M, et al. A prospective analysis of free flap monitoring techniques: physical examination, external Doppler, implantable Doppler, and tissue oximetry. *J Reconstr Microsurg*. 2013;29:51–56.
- Rao R, Saint-Cyr M, Ma AMT, et al. Prediction of post-operative necrosis after mastectomy: a pilot study utilizing optical diffusion imaging spectroscopy. *World J Surg Oncol*. 2009;7:1–6.
- Kagaya Y, Miyamoto S. A systematic review of near-infrared spectroscopy in flap monitoring: current basic and clinical evidence and prospects. *J Plast Reconstr Aesthet Surg*. 2018;71:246–257.
- Khavanin N, Darrach H, Kraenzlin F, et al. The Intra.Ox near-infrared spectrometer measures variations in flap oxygenation that correlate to flap necrosis in a preclinical rodent model. *Plast Reconstr Surg*. 2021;147:1097–1104.
- Khavanin N, Yesantharao P, Kraenzlin F, et al. quantifying the effect of topical nitroglycerin on random pattern flap perfusion in a rodent model: an application of the vioptix intra.ox for dynamic flap perfusion assessment and salvage. *Plast Reconstr Surg*. 2021;148:100–107.

30. Han T, Khavanin N, Wu J, et al. Indocyanine green angiography predicts tissue necrosis more accurately than thermal imaging and near-infrared spectroscopy in a rat perforator flap model. *Plast Reconstr Surg.* 2020;146:1044–1054.
31. Luze H, Nischwitz SP, Wurzer P, et al. Assessment of mastectomy skin flaps for immediate reconstruction with implants via thermal imaging—a suitable, personalized approach? *J Pers Med.* 2022;12:1–10.
32. Jones GE, Yoo A, King VA, et al. Snapshot multispectral imaging is not inferior to SPY laser fluorescence imaging when predicting murine flap necrosis. *Plast Reconstr Surg.* 2020;145:85e–93e.
33. Bowen RE, Treadwell G, Goodwin M. Correlation of near infrared spectroscopy measurements of tissue oxygen saturation with transcutaneous pO₂ in patients with chronic wounds. *SM Vascular Medicine.* 2016;1:1006.
34. Serena TE, Yaakov R, Serena L, et al. Comparing near infrared spectroscopy and transcutaneous oxygen measurement in hard-to-heal wounds: a pilot study. *J Wound Care.* 2020;29:S4–S9.
35. Landsman A. Visualization of wound healing progression with near infrared spectroscopy: a retrospective study. *Wounds.* 2020;32:265–271.
36. Gopalakrishnan S, Niezgoda J, Hoffman B, et al. Using near infrared spectroscopy imaging to manage critical limb ischemia. *Today's Wound Clinic.* 2019.
37. Johnson TM, Lowe L, Brown MD, et al. Histology and physiology of tissue expansion. *J Dermatol Surg Oncol.* 1993;19:1074–1078.