

Thoracic Spinal Metastasis of Merkel Cell Carcinoma in an Immunocompromised Patient: Case Report

Nicholas A. Madden¹ Patricia A. Thomas² Philip L. Johnson³ Karen K. Anderson⁴ Paul M. Arnold⁴

¹School of Medicine, University of Missouri-Kansas City, Kansas City, Missouri, United States

²Department of Pathology, University of Kansas Medical Center, Kansas City, Kansas, United States

³Department of Radiology, University of Kansas Medical Center, Kansas City, Kansas, United States

⁴Department of Neurosurgery, University of Kansas Medical Center, Kansas City, Kansas, United States

Address for correspondence Paul M. Arnold, MD, Department of Neurosurgery, University of Kansas Medical Center, Stop 3021, 3901 Rainbow Boulevard, Kansas City, KS 66160, United States (e-mail: parnold@kumc.edu).

Evid Based Spine Care J 2013;4:54–58.

Abstract

Study Design Case report.

Objective Merkel cell carcinoma (MCC), an uncommon cutaneous neuroendocrine malignancy, is a rare cause of spinal metastasis, with only five cases previously reported. We report a rare case of MCC metastatic to the spine in an immunocompromised patient.

Methods A 55-year-old male with previously resected MCC, immunocompromised due to cardiac transplant, presented with sharp mid-thoracic back pain radiating around the trunk to the midline. Computed tomography of the thoracic spine showed a dorsal epidural mass from T6 to T8 with compression of the spinal cord. Laminectomy and subtotal tumor resection were performed, and pathology confirmed Merkel cell tumor through immunohistochemistry staining positive for cytokeratin 20 and negative for thyroid transcription factor-1.

Results Further treatment with radiation therapy was initiated, and the patient did well for 4 months after surgery, but returned with a lesion in the cervical spine. He then opted for hospice care.

Conclusions With an increasing number of immunocompromised patients presenting with back pain, MCC should be considered in the differential diagnosis of spinal metastatic disease.

Keywords

- ▶ carcinoma
- ▶ Merkel cell
- ▶ spinal cord compression
- ▶ thoracic
- ▶ metastasis
- ▶ immuno-compromised patient

Introduction

Merkel cell (neuroendocrine) carcinoma (MCC) is an uncommon skin malignancy with a rare incidence of distant osseous metastasis. There are only five reports of spinal metastasis from MCC in the literature^{1–5}; we report the sixth case.

The spine is the most common location of bony metastases,^{6,7} with an occurrence rate of up to 40% in patients with cancer.⁸ The thoracic spine is the most common site of disease (70%),

followed by the lumbar spine (20%) and then cervical spine (10%).^{8,9} Spinal epidural lesions are the initial manifestation of malignancy in 12 to 20% of patients with cancer.^{10,11} Only 10 to 20% of patients with bony metastases develop symptomatic spinal cord compression,^{8,9,12} and 40 to 70% of those patients will have multiple levels of involvement.^{13,14} The most common primary sites accounting for the vast majority of spinal metastases are the prostate, breast, and lung, followed by renal, gastrointestinal, lymphoreticular

received
September 24, 2012
accepted after revision
November 28, 2012

© 2013 Georg Thieme Verlag KG
Stuttgart · New York

DOI <http://dx.doi.org/10.1055/s-0033-1341597>.
ISSN 1663-7976.

(lymphoma and multiple myeloma), thyroid, skin, and sarcomas, as well as unknown etiologies.^{2,8,11,15,16}

Case Report

A 55-year-old man presented with a 3-week history of sharp, midthoracic back pain radiating around the trunk to the midline at approximately the T7 level. He denied any numbness, paresthesias, weakness, and bowel or bladder dysfunction. His history was significant for multiple malignant skin lesions, including MCC, diagnosed in 2008. He underwent

tumor resection from the right posterior cervical region via a modified radical neck dissection due to positive lymph nodes 4 months prior to this hospitalization, and was treated with subsequent radiation therapy. Also significant was his history of cardiac transplant and immunosuppression with cyclosporine. Neurologic examination was normal except for some mild lower extremity weakness (4 + /5) in both knee extensors. The patient was unable to have an MRI secondary to remaining metal fragments in his right eye following surgery in 1983. Computed tomography (CT) of the thoracic spine showed a bilobed epidural mass extending from T6 to T8 with extension into the left T6/T7 neural foramen, caudal extension into the left T8/T9 neural foramen, and marked compression and effacement of the posterior left thecal sac and spinal cord (►Fig. 1a, b). The patient underwent T6 to T8 laminectomy and subtotal resection of the epidural tumor. Frozen section revealed a metastatic neuroendocrine tumor. The tumor appeared to extend around the cord and also into the lamina and spinous processes.

Microscopic examination revealed metastatic MCC, consistent with his previous diagnosis (►Fig. 2). The diagnosis was confirmed with immunohistochemical stains positive for cytokeratin 20 (CK20) and negative for thyroid transcription factor-1 (TTF-1).

He did well postoperatively, ambulating the next day, and was discharged home. His neurologic examination became normal. Post discharge, he started radiation treatments to his back while continuing radiation treatments to his head and neck. No chemotherapy was started while awaiting his response to radiation. Use of chemotherapy with Carboplatin/VP 16 had previously been discussed with initial nodal metastasis, but concern was raised over his immunosuppression and subsequent high risk of infection. Radiation therapy was completed 4 weeks after surgery and no chemotherapy was administered. The patient did well after surgery, reporting decreased pain and showing good strength. Nine weeks after resection of the T6 to T8 epidural mass, he presented with numbness of the soles of his feet, upper back pain and left-sided rib pain, weakness in bilateral lower extremities, and progressive gait instability. Four months after his spine

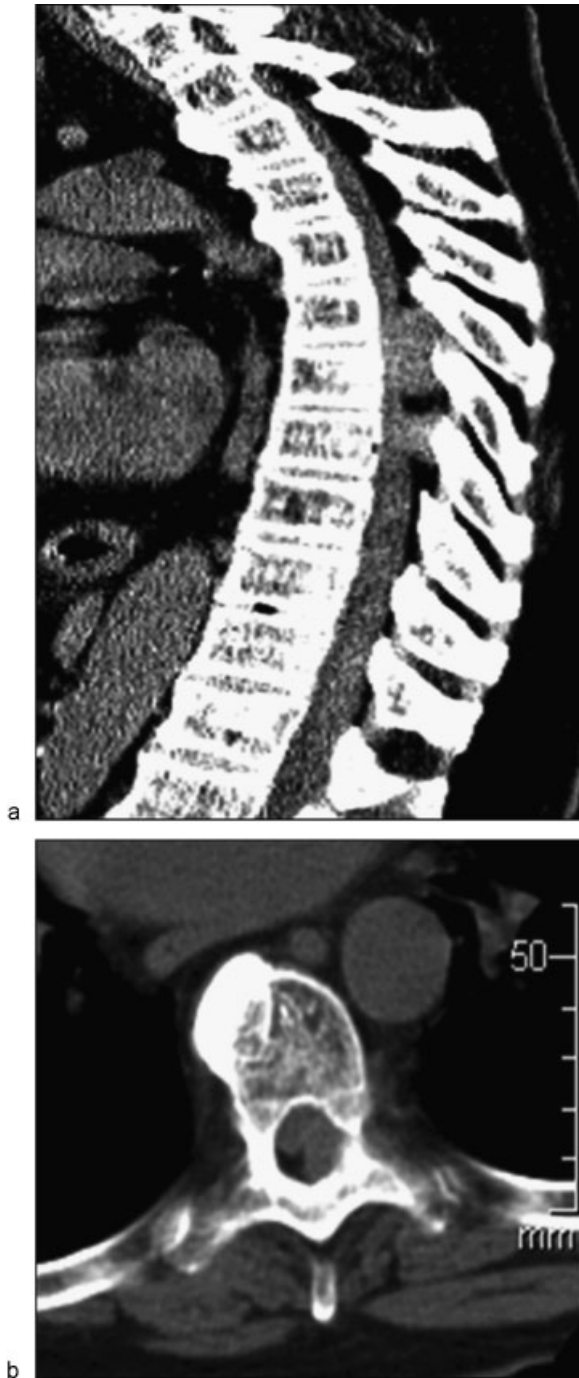


Fig. 1 (a) Sagittal CT of the thoracic spine shows bilobed tumor at T6–T8. (b) Axial CT shows tumor compressing the spinal cord.

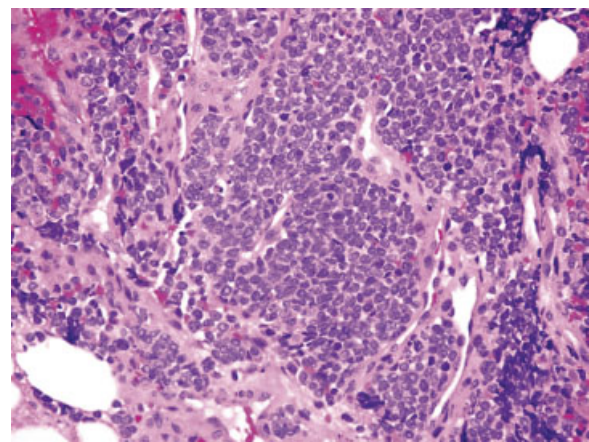


Fig. 2 Merkel cell carcinoma. Tumor cells are arranged in nests and cords with relatively uniform nuclei that are characteristically finely granular chromatin (hematoxylin and eosin, 200×).

surgery, the patient had developed a lesion in the cervical spine. The patient was offered surgery, but he declined. He was admitted to hospice due to progression of disease.

Discussion

MCC is a rare and aggressive neuroendocrine carcinoma of the skin, with a high rate of local recurrence as well as metastasis to regional lymph nodes. Toker is credited with the first description of MCC in 1972, originally naming it trabecular carcinoma.¹⁷ Neurosecretory granules in the tumor cells were identified by electron microscopic studies in 1978, indicating that trabecular carcinoma most likely originated from Merkel cells, one of the neural crest derivatives,¹⁸ from which this neoplasm now gets its name. Several functions have been hypothesized for Merkel cells, including roles in chemosensation and paracrine roles in hair development, but they have generally been presumed to be mechanoreceptors.¹⁹

MCC has an incidence of 44 per 100,000.²⁰ It is generally a disease of the elderly, with a mean age at diagnosis of approximately 70 years, with increasing incidence with age. It is more common in whites.²⁰⁻²² The most common location of the primary tumor is the head and neck, followed by extremities, trunk, and, least commonly, an unknown primary tumor.^{21,22} At the time of diagnosis, 52% of patients have regional lymph node involvement, while 34% of patients present with distant metastasis,²¹ including lungs, liver, mediastinum, para-aortic lymph nodes, and bone, in addition to local recurrence.^{23,24} Nervous system involvement is less common, though there have been eight reported cases of brain metastasis²⁴ in addition to the five previous cases of spinal metastasis.¹⁻⁵

Allen et al²⁵ found in their review of MCC patients that there was a statistically significant association between the development of distant metastasis and stage of disease at presentation. In addition, it was found that distant metastasis developed in 21% of the patients presenting with local or regional disease. Both of these findings correlate with our case and our patient's history of T2N1 Stage III MCC and regional lymph node metastases upon presentation prior to development of spinal disease.

Studies have determined several presumed risk factors for MCC, including immunosuppression.²¹⁻²³ Heath et al conducted a cohort of 195 patients and found 15, or 7.8% of the patients, were immunosuppressed. Etiologies of the immunosuppression included post-organ transplantation, like the patient in this case, HIV, and chronic lymphocytic leukemia. In addition, these patients presented with more advanced disease, though there was no age difference at presentation between immunocompetent and immunocompromised patients.²²

Diagnosing MCC can be difficult, as it grossly resembles several benign and malignant conditions. A definitive diagnosis of MCC is made by histologic examination as well as immunohistochemical analysis.^{26,27} CK20 is both sensitive and specific for MCC; 75 to 100% of cases are focally positive for CK20.²⁷⁻³⁰ In addition, TTF-1, a marker for thyroid and pulmonary neoplasms,³¹ is useful in distinguishing MCC from

small cell carcinoma of the lung (SCCL).^{25,32} MCC is consistently negative for TTF-1,^{26-28,33} whereas SCCL is positive for TTF-1 in 83 to 100% of cases. Our patient's tumor was CK20 positive and TTF-1 negative, consistent with the diagnosis of MCC.

Only five previous cases of spinal metastasis from MCC have been reported.¹⁻⁵ The patients had varying presentations including back pain; lower extremity weakness and numbness; sciatica; lower extremity spasticity, hyperreflexia and clonus; dermatomal sensory loss and incontinence. All six patients underwent surgery. After surgery, three patients received chemotherapy, and four patients received radiation. Two patients had lumbosacral metastases, three patients had thoracic metastases, and one patient had metastases at T8, L4, and S1. Our case represents the third report of thoracic metastases.

The first case involved metastasis at T3 to T4 after the primary tumor had been treated with wide excision. Treatment included steroids and emergent radiation upon diagnosis, followed by further radiation. The patient died 23 months after diagnosis.¹ The second case involved an initial tumor treated with surgical resection and chemotherapy followed by development of right lumbosacral metastasis. This was treated with radiation and no surgical intervention was performed; the patient died more than 1 year after diagnosis.² The third patient had no previous history of MCC before presenting with an epidural mass with osseous involvement at the L5 to S1 levels. This patient was treated with a laminectomy and subtotal resection followed by chemotherapy, and subsequently died 2 months after diagnosis of secondary to extensive metastasis.³ The fourth case also did not have a prior diagnosis of MCC. The patient presented with numerous neurological deficits secondary to epidural soft tissue masses causing neural compression at T8, L4, and S1. Treatment included laminectomy and tumor debulking at all three sites of compression, followed by chemotherapy and concurrent radiation. The patient died 1 month after diagnosis.⁴ The fifth case involved a patient who presented with rapidly progressive paraplegia 6 months after excision of a primary Merkel cell lesion on the left brachium. The metastatic lesion at T6 required emergency decompression and stabilization. The patient died 7 months after diagnosis.⁵ None of the other reported cases involved immunosuppressed patients.

The previous cases were consistent with dismal long-term outcomes, reflecting the poor survival rates of advanced MCC. Allen et al conducted a review of 251 MCC patients, 14 presenting with distant metastasis. These patients had a 2-year survival rate of 11%, with a median survival of only 9 months.²⁵

Conclusion

We present the third case of MCC metastatic to the thoracic spine, and to our knowledge, the first case of metastatic MCC in the thoracic spine in an immunocompromised patient. With an increasing number of immunocompromised patients

presenting, MCC should be considered part of the differential diagnosis of spinal metastatic disease.

Conflict of Interest

None

References

- Chao TC, Park JM, Rhee H, Greager JA. Merkel cell tumor of the back detected during pregnancy. *Plast Reconstr Surg* 1990;86(2):347–351
- Moayed S, Maldjianb C, Adam R, Bonakdarpour A. Magnetic resonance imaging appearance of metastatic Merkel cell carcinoma to the sacrum and epidural space. *Magn Reson Imaging* 2000;18(8):1039–1042
- Turgut M, Gökpinar D, Barutça S, Erkuş M. Lumbosacral metastatic extradural Merkel cell carcinoma causing nerve root compression—case report. *Neurol Med Chir (Tokyo)* 2002;42(2):78–80
- Vijay K, Venkateswaran K, Shetty AP, Rajasekaran S. Spinal extradural metastasis from Merkel cell carcinoma: a rare cause of paraplegia. *Eur Spine J* 2008;17(2)(Suppl 2):S267–S270
- Ng G, Lenehan B, Street J. Metastatic Merkel cell carcinoma of the spine. *J Clin Neurosci* 2010;17(8):1069–1071
- Hatrick NC, Lucas JD, Timothy AR, Smith MA. The surgical treatment of metastatic disease of the spine. *Radiother Oncol* 2000;56(3):335–339
- Böhm P, Huber J. The surgical treatment of bony metastases of the spine and limbs. *J Bone Joint Surg Br* 2002;84(4):521–529
- Klimo P Jr, Schmidt MH. Surgical management of spinal metastases. *Oncologist* 2004;9(2):188–196
- Gerszten PC, Welch WC. Current surgical management of metastatic spinal disease. *Oncology (Williston Park)* 2000;14(7):1013–1024, discussion 1024, 1029–1030
- Schick U, Marquardt G, Lorenz R. Intradural and extradural spinal metastases. *Neurosurg Rev* 2001;24(1):1–5, discussion 6–7
- Schiff D, O'Neill BP, Suman VJ. Spinal epidural metastasis as the initial manifestation of malignancy: clinical features and diagnostic approach. *Neurology* 1997;49(2):452–456
- Healey JH, Brown HK. Complications of bone metastases: surgical management. *Cancer* 2000;88(12)(Suppl):2940–2951
- Heldmann U, Myschetzky PS, Thomsen HS. Frequency of unexpected multifocal metastasis in patients with acute spinal cord compression. Evaluation by low-field MR imaging in cancer patients. *Acta Radiol* 1997;38(3):372–375
- Khaw FM, Worthy SA, Gibson MJ, Gholkar A. The appearance on MRI of vertebrae in acute compression of the spinal cord due to metastases. *J Bone Joint Surg Br* 1999;81(5):830–834
- Abdu WA, Provencher M. Primary bone and metastatic tumors of the cervical spine. *Spine (Phila Pa 1976)* 1998;23(24):2767–2777
- Solberg A, Bremnes RM. Metastatic spinal cord compression: diagnostic delay, treatment, and outcome. *Anticancer Res* 1999;19(1B):677–684
- Toker C. Trabecular carcinoma of the skin. *Arch Dermatol* 1972;105(1):107–110
- Tang CK, Toker C. Trabecular carcinoma of the skin: an ultrastructural study. *Cancer* 1978;42(5):2311–2321
- Lucarz A, Brand G. Current considerations about Merkel cells. *Eur J Cell Biol* 2007;86(5):243–251
- Hodgson NC. Merkel cell carcinoma: changing incidence trends. *J Surg Oncol* 2005;89(1):1–4
- Akhtar S, Oza KK, Wright J. Merkel cell carcinoma: report of 10 cases and review of the literature. *J Am Acad Dermatol* 2000;43(5, Pt 1):755–767
- Heath M, Jaimes N, Lemos B, et al. Clinical characteristics of Merkel cell carcinoma at diagnosis in 195 patients: the AEIOU features. *J Am Acad Dermatol* 2008;58(3):375–381
- Buell JF, Trofe J, Hanaway MJ, et al. Immunosuppression and Merkel cell cancer. *Transplant Proc* 2002;34(5):1780–1781
- Turgut M. Brain metastasis of Merkel cell carcinoma. *Neurosurg Rev* 2002;25(1–2):113–114
- Allen PJ, Bowne WB, Jaques DP, Brennan MF, Busam K, Coit DG. Merkel cell carcinoma: prognosis and treatment of patients from a single institution. *J Clin Oncol* 2005;23(10):2300–2309
- Zhan FQ, Packianathan VS, Zeitouni NC. Merkel cell carcinoma: a review of current advances. *J Natl Compr Canc Netw* 2009;7(3):333–339
- Pulitzer MP, Amin BD, Busam KJ. Merkel cell carcinoma: review. *Adv Anat Pathol* 2009;16(3):135–144
- Cheuk W, Kwan MY, Suster S, Chan JK. Immunostaining for thyroid transcription factor 1 and cytokeratin 20 aids the distinction of small cell carcinoma from Merkel cell carcinoma, but not pulmonary from extrapulmonary small cell carcinomas. *Arch Pathol Lab Med* 2001;125(2):228–231
- Calder KB, Coplowitz S, Schlauder S, Morgan MB. A case series and immunophenotypic analysis of CK20-/CK7+ primary neuroendocrine carcinoma of the skin. *J Cutan Pathol* 2007;34(12):918–923
- Bobos M, Hytiroglou P, Kostopoulos I, Karkavelas G, Papadimitriou CS. Immunohistochemical distinction between Merkel cell carcinoma and small cell carcinoma of the lung. *Am J Dermatopathol* 2006;28(2):99–104
- McCluggage WG, Kennedy K, Busam KJ. An immunohistochemical study of cervical neuroendocrine carcinomas: neoplasms that are commonly TTF1 positive and which may express CK20 and P63. *Am J Surg Pathol* 2010;34(4):525–532
- Brown JA, Smoller BR. Merkel cell carcinoma: what is it, what will it do and where will it go? What role should the pathologist play in reporting this information?. *J Cutan Pathol* 2009;36(8):924–927
- Ralston J, Chiriboga L, Nonaka D. MASH1: a useful marker in differentiating pulmonary small cell carcinoma from Merkel cell carcinoma. *Mod Pathol* 2008;21(11):1357–1362

Editorial Perspective

Our practice of spine surgery is an imperfect one, despite our best attempts to always produce the best possible results. Disease recurrence and complications of treatment are hallmarks we are measured by, mostly with little regard for the patient comorbidity and disease-specific factors. As has been previously and repeatedly pointed out, rare diseases pose a particular challenge to treatment and scientific assessment as our knowledge base is often based upon anecdotal case reports, and every patient seems to present some collection of “one-out” situations. In this era of more advanced infor-

mation systems and multicenter collaborative opportunities, rare cases such as this Merkel cell carcinoma should be sought and included in larger data repositories. The next step could then be taken, creating “biomaps” to allow for more granular, in-depth analysis of the genetic disease foundations, which is critical in advancing our ability to fight these rare diseases. The AOSpine Knowledge Forum movement offers a perfect home for surgeons interested in contributing to our information-gathering efforts to improve patient care.

Commentary

Aron Lazary¹

¹National Center for Spinal Disorders, Budapest, Hungary

Madden et al represent a case with a thoracic, epidural metastasis of a rare, aggressive neuroendocrine skin carcinoma (Merkel cell carcinoma, MCC). Looking through the report of this case, many details need further consideration. (1) The patient was immunocompromised due to cardiac transplant. (2) He had significant previous history of an advanced stage malignant skin lesion and at the time of the diagnosis of MCC, 34% of patients have distant (mainly visceral) metastasis. (3) There was no significant neurological deficit at the time of the diagnosis. (4) MRI could not be performed because of metal fragments in the patient’s eye.

In case of metastatic epidural tumors, the treatment is mostly palliative, but a proper staging should forego the treatment planning, especially in cases with positive medical history. In MCC, surgery is generally recommended only for single-site metastatic diseases and this tumor shows visceral spreading more often than bony involvement.¹ Neurological emergency can overwrite the above recommendation; an acute decompression surgery is to be considered in case of progressive motor weakness or bowel or bladder dysfunction. In the reported case, a simple CT of the thoracic spine seems to be not enough to carefully plan the treatment strategy even in the case where the histological diagnosis of the spinal metastasis is not surely known. MRI is highly recommended for imaging of epidural mass, but in case of its contraindication, CT-myelography can

also provide more detailed data on the tumor. We agree that the debulking surgery was followed by irradiation, but according to the previously published treatment algorithms of spinal² and spinal epidural³ metastases, irradiation also could have been the first treatment choice. In this reported case, 9 weeks after the subtotal resection of the thoracic epidural mass, the patient presented progressive neurological symptoms and 2 months later a cervical lesion was discovered. The judgment on indication of the index surgical treatment in the light of the progression cannot be clearly done, because in the paper, there is no information about the effectiveness of the adjuvant radiotherapy (no control CT) and about further radiological findings in these later stages.

References

- 1 Cirillo F, Vismarra M, Cafaro I, Martinotti M. Merkel cell carcinoma: a retrospective study on 48 cases and review of literature. *J Oncol* 2012;2012:749030
- 2 Gasbarrini A, Li H, Cappuccio M, et al. Efficacy evaluation of a new treatment algorithm for spinal metastases. *Spine (Phila Pa 1976)* 2010;35:1466-1470
- 3 Quraishi NA, Gokaslan ZL, Boriani S. The surgical management of metastatic epidural compression of the spinal cord. *J Bone Joint Surg Br* 2010;92(8):1054-1060