

[CASE REPORT]

Stiff-person Syndrome with Waldenström Macroglobulinemia

Kazuhiro Horiuchi¹, Yasunori Maruo¹ and Satomi Matsuoka²

Abstract:

We herein report the case of stiff-person syndrome in a 73-year-old woman. She experienced episodes of painful muscle spasms and was admitted to another hospital. She was diagnosed with Waldenström macroglobulinemia. She showed improvement in muscle spasms post-chemotherapy, which was discontinued due to pancytopenia. Six months later, she was admitted to our hospital for repeated whole-body muscle spasms, at which point she was diagnosed with stiff-person syndrome. An anti-glutamic acid decarboxylase antibody test was negative. Her muscle spasms disappeared after the administration of corticosteroids and rituximab. Stiff-person syndrome may develop with Waldenström macroglobulinemia. In the present case, corticosteroids and rituximab provided effective treatment.

Key words: stiff-person syndrome, Waldenström macroglobulinemia, rituximab, corticosteroids

(Intern Med 57: 3313-3316, 2018)

(DOI: 10.2169/internalmedicine.1043-18)

Introduction

Stiff-person syndrome (SPS) is a disabling central nervous system disorder characterized by muscle stiffness, rigidity, and episodic painful spasms that affects the axial and proximal limb muscles. Circulating antibodies against glutamic acid decarboxylase (GAD65) are characteristic of the disease and exhibit distinct epitope specificity (1, 2). Some cases of paraneoplastic SPS occur in association with anti-amphiphysin antibodies (3). In paraneoplastic SPS, cross-reactive binding of serum antibodies with malignant cells expressing neuronal antigens, such as GAD and amphiphysin, may be responsible for triggering the autoimmune response (4, 5).

We herein report a case of SPS with Waldenström macroglobulinemia where the patient showed improvement after treatment with corticosteroids and rituximab.

Case Report

We herein report a case of SPS in a 73-year-old woman. She had experienced sudden, occasional spasms of both limbs for approximately 1.5 years. She began to fall fre-

quently and was admitted to another hospital. She was found to have vitamin B₁₂ deficiency (212 pg/mL; normal range is 233 to 914 pg/mL) and was diagnosed with subacute combined degeneration of the spinal cord. She received supplementation with vitamin B₁₂, but the condition of the muscle spasms in the lower limbs did not improve. Another examination revealed immunoglobulin M (IgM) elevation (3,164 mg/dL), IgM-κ type M paraproteinemia, and plasma cell proliferation via a bone marrow biopsy (20% of cell components were CD 138-positive cells). She was diagnosed with Waldenström macroglobulinemia based on these results.

She received chemotherapy (rituximab 600 mg, cyclophosphamide 750 mg, vincristine 1 mg, and prednisolone 100 mg). After chemotherapy, IgM was decreased to 1,747 mg/dL, and the spasticity of the lower limbs also decreased. However, the muscle spasms of the lower limbs still occasionally occurred, and falls due to muscle spasms resulted in cerebral contusion and traumatic subarachnoid hemorrhaging, which caused sensory aphasia. Her sensory aphasia gradually improved. After five courses of chemotherapy, her spasms decreased markedly. Although spasticity remained, she was able to walk with a walker. For several months, she had mild spasms about only once a month. Six months be-

¹Department of Neurology, Hakodate City Hospital, Japan and ²Department of Hematology, Hakodate City Hospital, Japan

Received: February 17, 2018; Accepted: April 1, 2018; Advance Publication by J-STAGE: July 6, 2018

Correspondence to Dr. Kazuhiro Horiuchi, horiuchi-kazuhiro@hotmail.co.jp

fore hospitalization, she visited our hospital because of a change in residence. During that time, her spasms and the spasticity of her lower limbs gradually deteriorated. She was mobile on a wheelchair. The symptoms continued to deteriorate afterwards. One month prior to entering our hospital, she experienced frequent muscle cramps with severe pain in her lower limbs and eventually experienced whole-body muscle spasms. We attempted oral treatment with clonazepam and baclofen, but it was not effective. She was admitted to our hospital for the treatment of frequent whole-body muscle spasms.

On an examination, she was exhausted and frightened by the repeated whole-body muscle spasms (60 times per day). Her pulse rate, blood pressure, respiratory rate, oxygen saturation, and temperature were 68 beats/min, 128/74 mmHg, 12 breaths/min, 95%, and 36.5°C, respectively. Her height was 149 cm, and her weight was 50 kg. Her breath sounds were clear on chest auscultation. Her abdomen was flat and soft, and no mass was noticed on palpation. No lymphadenopathy was observed on palpation. Clinical manifestations of hyperviscosity syndrome, such as bleeding from mucous membranes, visual disturbances due to retinopathy, and neurologic symptoms (headache, vertigo, seizures, and coma), were not noted. On a neurological examination, the strength of her lower limbs by Manual Muscle Testing (MMT) was 3/5, accompanied by severe spasticity and hyperreflexia (the Babinski and Chaddock reflexes were difficult to evaluate because of the spasms). Her painful spasms included truncal and proximal limb stiffness, stemming from the co-contraction of agonist and antagonist muscles and leading to lumbar hyperlordosis. Reflective myoclonus was reported frequently. Stimulation induced muscle spasms, and difficulty breathing was noted during the spasms. Her spasms disappeared during sleep. Paroxysmal autonomic dysfunction with associated diaphoresis, tachycardia, pupillary dilatation, and hypertension were reported. Although the spasms disappeared after the intravenous injection of diazepam, the effects of diazepam lasted for only two hours. She did not experience sensory disturbance or dysuria.

Initial laboratory studies revealed the following findings: white blood cell count, 4,000/mm³; hemoglobin, 11.8 mg/dL; platelet count, 24.4×10³; C-reactive protein, 0.47 mg/dL; aspartate aminotransferase, 20 international units (IU)/L; alanine aminotransferase, 14 IU/L; lactate dehydrogenase, 200 IU/L; blood urea nitrogen, 20.3 mg/dL; creatinine, 0.76 mg/dL; uric acid, 5.8 mg/dL; sodium, 142 mEq/L; potassium, 3.7 mEq/L; chloride, 104 mEq/L; creatine phosphokinase, 149 U/L; glucose, 119 mg/dL; HbA1c, 5.4%; IgA, 110 mg/dL; IgG, 513 mg/dL; IgM, 1,066 mg/dL; prothrombin time, 10.5 seconds; INR 0.85, normal range <INR 1.15; activated partial thromboplastin time, 20.8 seconds, normal range <42 seconds; soluble interleukin 2 receptor (sIL2R), 613 U/L; and vitamin B₁₂, 876 pg/mL. Monoclonal IgM gammopathy was detected by serum electrophoresis in combination with immune fixation. Both anti-GAD65 antibody and amphiphysin antibody tests yielded negative results. We

checked only the IgG subclass of anti-GAD65 and amphiphysin antibodies. In the cerebrospinal fluid test, the number of cells was 3/μL (mononuclear cells, 2; multinuclear cells, 1), and the protein level was 42.2 mg/dL.

Brain magnetic resonance imaging (MRI) revealed traces of cerebral contusion in the left temporal lobe. The spinal MRI findings were normal. Needle electromyography revealed the simultaneous continuous low frequency firing of normal motor units in the agonist and antagonist muscles of the lower limbs; however, we were only able to perform this examination for a short duration because the needle puncture caused severe pain. Bone marrow biopsy findings showed no blastic proliferation. The plasma cell level was 4%, and findings suggesting macroglobulinemia were not observed. Whole-body computed tomography (CT) showed no lymph node enlargement or any other malignancy.

Based on the clinical history and significant muscle spasms with stimulation, we diagnosed her with SPS. We also identified paraneoplastic syndrome associated with Waldenström macroglobulinemia as the cause of the SPS. The clinical course is shown in Figure.

We administered clonazepam and baclofen for her muscle spasms, but these gamma-aminobutyric acid (GABA)-enhancing drugs yielded only a slight improvement. The IgM values and the results of a bone marrow biopsy showed no worsening of the Waldenström macroglobulinemia. We decided not to resume chemotherapy for macroglobulinemia, because the macroglobulinemia had not worsened and chemotherapy had been discontinued because of pancytopenia before. Given the possibility of hyperviscosity syndrome manifesting because she suffered from Waldenström macroglobulinemia, intravenous immunoglobulin was avoided. We did not consider plasma exchange for our patient because it would have been difficult to keep her at rest during the procedure due to her painful muscle spasms frequently leading to lumbar hyperlordosis. Therefore, we treated the patient with only corticosteroid and rituximab for SPS.

Corticosteroid (methylprednisolone 500 mg/day, 3 days) was partially effective. Her muscle spasms were reduced but not eliminated (down to 10 times a day from 60 times a day). Rituximab (375 mg/m² by weekly, 4 times) was dramatically effective. Her muscle spasms disappeared after rituximab therapy, and reflective myoclonus gradually disappeared after treatment. Weakness of the lower limbs (MMT 3/5) and spasticity and hyperreflexia remained but gradually improved. The severity of the spasms was not correlated with the IgM or sIL2R values. She did not experience any side effects from the medications. Corticosteroid was gradually tapered from 60 mg to 8 mg per day, and her muscle spasms did not recur. She was able to walk with a cane.

However, we must practice care, as SPS symptoms can recur with worsening of macroglobulinemia. If this occurs, we will consider chemotherapy for Waldenström macroglobulinemia again. If her SPS symptoms recur without worsening of macroglobulinemia, we will consider treat-

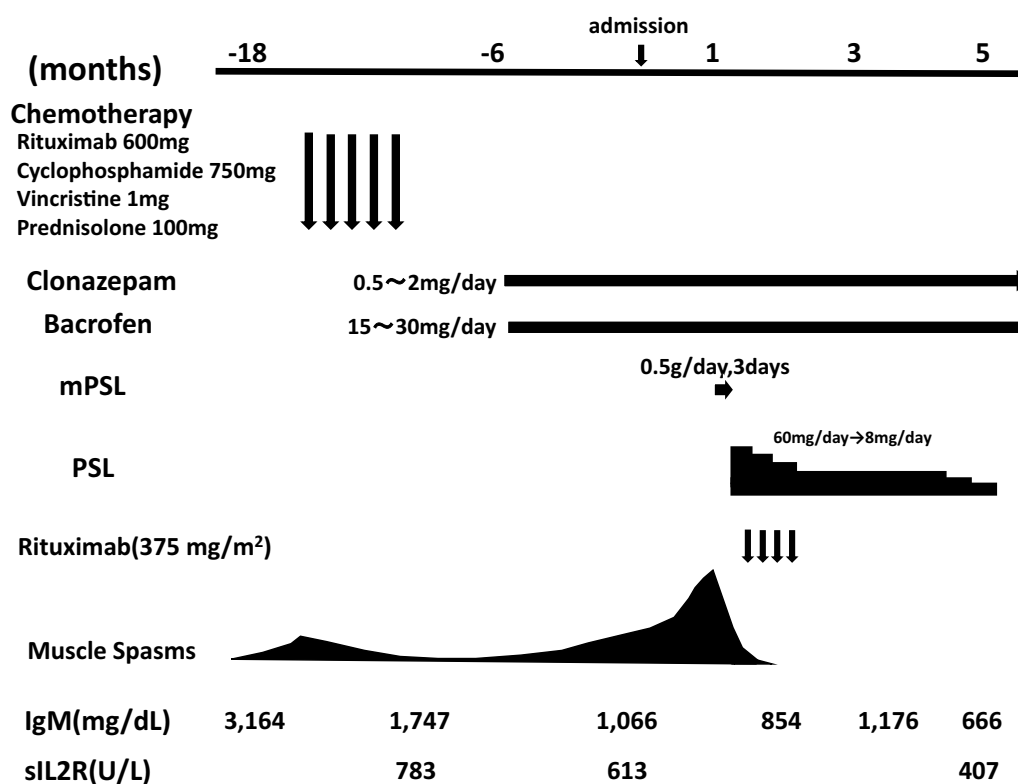


Figure. Clinical course. Muscle spasms due to paraneoplastic stiff-person syndrome (SPS) were improved by chemotherapy, corticosteroids, and rituximab. The severity of the spasms was not correlated with the IgM or sIL2R s. IgM: immunoglobulin M, mPSL: methylprednisolone, PSL: prednisolone, sIL2R: soluble interleukin receptor

ing her with high doses of corticosteroids and rituximab.

Discussion

SPS can be associated with malignancy (paraneoplastic SPS). Malignancies of the thymus, colon, and lung; Hodgkin's lymphoma; leukemia; mesothelioma; and melanoma have also been reported (6). The antibody profile of paraneoplastic SPS is varied.

Anti-GAD antibodies and anti-amphiphysin antibodies have been reported in patients with paraneoplastic SPS (6, 7); however, our patient tested negative for these antibodies. A review of the literature found that no antibodies were detected in some cases of paraneoplastic SPS (6). Because of the presence of typical symptoms of SPS, which were improved by chemotherapy for macroglobulinemia, we diagnosed the patient with paraneoplastic SPS associated with Waldenström macroglobulinemia.

Most SPS patients show improvement with GABA-enhancing drugs and intravenous immunoglobulin (8, 9); however, some respond poorly and remain disabled. We attempted treatment with GABA-enhancing drugs (clonazepam and baclofen) in the present patient, but they were not effective in relieving her severe spasms.

Some reports have found that chronic plasma exchange was effective in treating patients with SPS and a previous poor response to symptomatic and other immunomodulatory

treatments (10, 11).

Rituximab is a genetically engineered monoclonal antibody directed against CD20 that causes a swift and sustained depletion in the number of B cells and is a promising treatment for several autoimmune neurological diseases (12). Patients reportedly show a good and safe response to rituximab treatment for SPS (13, 14), but a double-blind, placebo-controlled study of rituximab for patients with SPS found no statistically significant differences in the efficacy measures between rituximab and placebo (15).

According to another report, SPS was improved by chemotherapy in a patient with cutaneous T-cell lymphoma (16). In the present case, the SPS symptoms were relieved for several months after chemotherapy for Waldenström macroglobulinemia. We believe that the SPS symptoms were improved by suppressing some factor that we were unable to detect using corticosteroids and rituximab, with the spasms disappearing after these treatments.

Conclusion

In summary, we report a case of paraneoplastic SPS with Waldenström macroglobulinemia that was improved by treatment with corticosteroids and rituximab. Clinicians should be aware that there are cases of paraneoplastic SPS with Waldenström macroglobulinemia in which SPS symptoms recur without the worsening of macroglobulinemia, as in the present patient, and treatment with corticosteroids and rituxi-

mab can be effective in such cases.

Written informed consent was obtained from the patient for publication of this case report and accompanying images.

The authors state that they have no Conflict of Interest (COI).

Acknowledgement

We would like to thank the staff of the medical unit for their help in the treatment of this patient.

References

- Dalakas MC, Fujii M, Li M, McElroy B. The clinical spectrum of anti-GAD antibody-positive patients with stiff-person syndrome. *Neurology* **55**: 1531-1535, 2000.
- Dalakas MC, Li M, Fujii M, Jacobowitz DM. Stiff person syndrome: quantification, specificity, and intrathecal synthesis of GAD65 antibodies. *Neurology* **57**: 780-784, 2001.
- Antoine JC, Absi L, Honnorat J, et al. Anti-amphiphysin antibodies are associated with various paraneoplastic neurological syndromes and tumors. *Arch Neurol* **56**: 172-177, 1999.
- Alexopoulos H, Dalakas MC. A critical update on the immunopathogenesis of Stiff Person Syndrome. *Eur J Clin Invest* **40**: 1018-1025, 2010.
- Pittock SJ, Lucchinetti CF, Parisi JE, et al. Amphiphysin autoimmunity: paraneoplastic accompaniments. *Ann Neurol* **58**: 96-107, 2005.
- Sarva H, Deik A, Ullah A, Severt WL. Clinical spectrum of stiff person syndrome: a review of recent reports. *Tremor Other Hyperkinet Mov (N Y)* **6**: 340, 2016.
- De Camilli P, Thomas A, Cofield R, et al. The synaptic vesicle-associated protein amphiphysin is the 128-kD autoantigen of stiff-man syndrome with breast cancer. *J Exp Med* **178**: 2219-2223, 1993.
- Dalakas MC. Stiff person syndrome: advances in pathogenesis and therapeutic interventions. *Curr Treat Options Neurol* **11**: 102-110, 2009.
- Dalakas MC, Fujii M, Li M, Lutfi B, Kyhos J, McElroy B. High-dose intravenous immune globulin for stiff-person syndrome. *N Engl J Med* **345**: 1870-1876, 2001.
- Nakamagoe K, Ohkoshi N, Hayashi A, Hisahara S, Shoji S. [Marked clinical improvement by plasmapheresis in a patient with stiff-man syndrome: a case with a negative anti-GAD antibody]. *Rinsho Shinkeigaku (Clin Neurol)* **35**: 897-900, 1995 (in Japanese, Abstract in English).
- De la Casa-Fages B, Anaya F, Gabriel-Ortemberg M, Grandas F. Treatment of stiff-person syndrome with chronic plasmapheresis. *Mov Disord* **28**: 396-397, 2013.
- Dalakas MC. Invited article: inhibition of B cell functions: implications for neurology. *Neurology* **70**: 2252-2260, 2008.
- Lobo ME, Araújo ML, Tomaz CA, Allam N. Stiff-person syndrome treated with rituximab. *BMJ Case Rep* **2010**: 2010.
- Qureshi A, Hennessy M. Stiff person syndrome (SPS) complicated by respiratory failure: successful treatment with rituximab. *J Neurol* **259**: 180-181, 2012.
- Dalakas MC, Rakocevic G, Dambrosia JM, Alexopoulos H, McElroy B. A double-blind, placebo-controlled study of rituximab in patients with stiff person syndrome. *Ann Neurol* **82**: 271-277, 2017.
- Rakocevic G, Hussain A. Stiff person syndrome improvement with chemotherapy in a patient with cutaneous T cell lymphoma. *Muscle Nerve* **47**: 938-939, 2013.

The Internal Medicine is an Open Access journal distributed under the Creative Commons Attribution-NonCommercial-NoDerivatives 4.0 International License. To view the details of this license, please visit (<https://creativecommons.org/licenses/by-nc-nd/4.0/>).