

The effects of hydroxyapatite implantation with the autogenous sclera cap

A cohort study

Hongwei Zhou, MD, PhD^a, Chongyan Zhu, MD^{a,*}, Kai Chen, MD^a, Xiang Zheng, MD^a

Abstract

We performed a novel hydroxyapatite (HA) prosthesis implantation method in which an HA implant was implanted into the scleral shell with an autogenous scleral cap.

Twenty-six patients who had undergone the novel HA prosthesis implantation method and 32 patients who had undergone traditional HA prosthesis implantation were retrospectively reviewed. The postoperative activity of the artificial eye was measured by the Hirschberg test combined with arc perimetry. The visual analog score (VAS) was used to evaluate 2-month postoperative pain and 2-month postoperative discomfort. HA implant vascularization was measured with enhanced magnetic resonance imaging (MRI) 2 and 6 months after the operation. The enhancement volume (V_E) and the volume of the HA implant (V_{HA}) were measured. All cases were followed up for 2 years. Measurement data were processed using SAS 6.12.

There was a statistically significant difference ($P=.016$) between the percentages of excellent grade in the two groups. Two months after implantation, the median pain scores of the study and control groups were 2 and 2.5, respectively, and there was a statistically significant difference ($W=585.0$, $P=.004$); there was a statistically significant difference ($W=535.5$, $P=.000$) between the median discomfort scores of the study group (score=1) and control group (score=2); the mean V_E/V_{HA} values of the study and control groups were 0.3075 and 0.1535, respectively, and there was a statistically significant difference ($t=-8.196$, $P=.000$). Six months after implantation, the V_E/V_{HA} values of the study and control groups were 0.9686 and 0.5934, respectively, and there was a statistically significant difference ($W=549.0$, $P=.000$). Within 2 years of postoperative follow-up, there were no serious complications in the study group.

In the study group, in which the hydroxyapatite implant was implanted into a preserved scleral shell with unaltered muscles and covered with an autogenous scleral cap, postoperative activity and the fibrovascularization of the HA implant were significantly increased, and postoperative pain and discomfort were significantly reduced.

Abbreviation: HA = hydroxyapatite.

Keywords: artificial eye activity, evisceration, hydroxyapatite prosthesis, implant complication

1. Introduction

In 1885, Nules first implanted a glass ball into the conjunctiva sac,^[1] and in 1985, Perry began implanting hydroxyapatite (HA) orbital implants to increase the beauty effect.^[2] HA has the same mineral composition as human bone tissue, good biocompatibility, light weight, no absorption, and little stimulation to surrounding tissues. HA is a novel orbital implant material that has been widely used in recent years and is conducive to the ingrowth of orbital fiber vessels.^[2] Complications of HA implants mainly include infection, implant exposure, conjunctival thinning, implant extrusion, conjunctival dehiscence,

pyogenic granuloma formation and persistent implantation, among which implant exposure is the most common, with an incidence of approximately 2.5% to 21.6%, and infection is the most serious complication.^[3]

Because of the different etiologies, the main methods of eye removal surgery include evisceration, enucleation and exenteration.^[2] At present, there are several kinds of operation methods for implanting artificial eyes after evisceration of eye contents, including buried, exposed-integrated, and buried-integrated implants.^[2] In traditional scleral implantation, after evisceration of eye contents, the optic nerve is cut or not cut, and then the incision is extended backward along the front of the scleral

Completed consent form for participation is available from the corresponding author on reasonable request.

The authors have no funding and conflicts of interest to disclose.

The datasets generated during and/or analyzed during the current study are not publicly available, but are available from the corresponding author on reasonable request.

The clinical data were related to personal information, and were not necessarily publicly available.

^aDepartment of Ophthalmology, Lianshui County People's Hospital, Nanjing Medical University, Huai'an, China

*Correspondence: Chongyan Zhu, Department of Ophthalmology, Lianshui County People's Hospital, 6# Hongri Road, Lianshui, Huai'an, Jiangsu 223400, China (e-mail: zcyeyegood@hotmail.com).

Copyright © 2022 the Author(s). Published by Wolters Kluwer Health, Inc. This is an open-access article distributed under the terms of the Creative Commons Attribution-Non Commercial License 4.0 (CCBY-NC), where it is permissible to download, share, remix, transform, and buildup the work provided it is properly cited. The work cannot be used commercially without permission from the journal.

How to cite this article: Zhou H, Zhu C, Chen K, Zheng X. The effects of hydroxyapatite implantation with the autogenous sclera cap: a cohort study. *Medicine*. 2022;101:30(e29519).

Received: 6 August 2020 / Received in final form: 6 May 2022 / Accepted: 6 May 2022

<http://dx.doi.org/10.1097/MD.00000000000029519>

shell; the HA artificial eye is directly implanted into the scleral shell, and then the anterior sclera is tightened and sutured. However, the anterior sclera is not easy to suture, and there could be some exposure of part of the front of the HA implant. Even if the anterior sclera is tightened and then sutured, the tension between the scleral flaps is often high, which can cause scleral tears, postoperative HA implant exposure, infection and other problems. Referring to orbital implantation with HA prostheses in the muscular pyramid, there are many kinds of operative methods, which can be divided into three types: scleral shell wrapped, no scleral shell wrapped and scleral flaps covered. Orbital implantation with HA prostheses in the muscular pyramid is conducive to the vascularization of HA prostheses. However, orbital implantation is associated with certain defects. The muscle is cut off and then sutured again, and then the scleral shell or muscle is covered on the surface of the HA prosthesis during the operation. These factors can change the original anatomical structure to a greater extent, resulting in an unnatural appearance and poor mobility after surgery. When the primary disease is an intraocular tumor, such as retinoblastoma and choroidal melanoma, which requires enucleation of the eyeball, we can only choose to implant an HA prosthesis in the muscular pyramid, while in absolute glaucoma and other conditions, we usually choose to eviscerate the eye contents, which will cause less damage and retain the original anatomical relationship of the muscle and nerve.^[4]

After considering the need for vascularization, reduction of suture tension of anterior sclera flaps, reduction of postoperative exposure, preservation of the original anatomical relationship of muscle to increase the activity of the artificial eye and to reduce postoperative pain and discomfort, we designed a novel HA prosthesis implantation method with the autogenous sclera covering cap, preserved sclera shell and unaltered muscles whose effects were found to be very good through clinical observation. This paper describes the details of this method.

2. Patients and Methods

This is a cohort study. We obtained approval from the institutional review board of Lianshui County People's Hospital (Approval no. 20160102-2). Informed consent was obtained from every case. The inclusion criterion was: (1) eye contents were eviscerated and HA was implanted into the preserved sclera shell. The exclusion criteria were: (1) the patients did not consent to participate in the study; or (2) the follow-up period was shorter than 2 years. We retrospectively reviewed the medical records of the study group, which included 26 eyes in 26 cases from January 8, 2010 to December 24, 2017. In all of the cases, the hydroxyapatite implant was implanted into a preserved scleral shell with unaltered muscles and covered with an autogenous scleral cap. In the study group, there were 14 males and 12 females, aged 28 to 67 years. We also retrospectively reviewed the medical records of the control group, which included 32 eyes in 32 cases from January 15, 2010 to December 1, 2017. In all of the cases, the hydroxyapatite implant was implanted into a preserved scleral shell without an autogenous scleral cap. The posterior sclera around the optic nerve and the optic nerve itself were not incised.

In the control group, there were 16 males and 16 females, aged 27 to 65 years. The main causes of evisceration of eye contents in both groups were absolute glaucoma, infectious keratitis, corneal perforation and serious extraocular rupture. Other causes included corneal leucoma, endophthalmitis and Phthisis bulbi. Systemic medical conditions included diabetes, hypertension and stroke. The associated ophthalmic conditions included cataracts, diabetic retinopathy, corneal staphyloma and retinal detachment. Systemic and ophthalmic medications included antibacterial eye-drops, oral hypoglycemic, insulin, antihypertensive, trabeculectomy, cyclocryotherapy, and extracapsular cataract extraction.

Fisher's exact test was used to test the difference between rates in both groups. The Shapiro-Wilk test was used to test whether the measurement data were normally distributed. Two independent samples *t* tests were used for the normally distributed data. If any group of data was not normally distributed, the Wilcoxon rank-sum test was used. When $P < .05$, there was a significant difference. Measurement data were processed using SAS 6.12 (SAS Institute Inc., Cary, NC).

All of the cases were followed up for 2 years. All the cases were operated on by one surgeon (CYZ). The properties of the two groups were compared. Since the age at operation in the study group was not normally distributed (Shapiro-Wilk test, $P = .039$), the Wilcoxon rank-sum test was used to test the equality of the median age at operation between the two groups. The median age at operation of the study and control groups was 50 and 52, respectively, and there was a statistically significant difference ($W = 721.5$, $P = .476$ two-tailed). There was no significant difference in the sex ratio between the two groups ($P = .797$, two-tailed). There was no significant difference in the percentage of the main causes of evisceration (eyeball defect, infectious corneal perforation, absolute glaucoma) between the two groups ($P = 1, .787, .790$, respectively, two-tailed). The main clinical characteristics of the cases are listed in Table 1.

2.1. Surgical technique

In both groups, the bulbar conjunctiva and Tenon's capsule were incised along the limbus of the cornea. The conjunctiva and Tenon's capsule were separated 5mm backward from the conjunctival incision at the corneal limbus. The sclera was incised 1mm behind the limbus at 9'o clock. The cornea was completely cut off, and the contents of the eyeball were removed with a curette. The uveal tissue was removed completely. The inner surface of the sclera was burned with tincture of iodine. Residual pigment cells were removed. The iodine was washed away twice with 75% alcohol, and then the scleral shell was rinsed with normal saline. The sclera was incised radially from the corneal limbus along the upper-nasal direction, lower-nasal direction, upper-temporal direction and lower-temporal direction to 2mm behind the eyeball equator (Fig. 1). The 4 sclera flaps were fixed using forceps.

In the study group, the sclera around the optic nerve was cut in a circular way to make the posterior sclera open like a window with a diameter of approximately 8mm. The residual end of the optic nerve was cut off, and the posterior scleral flap was removed for use (Fig. 2). A steel ball with a diameter of 22mm was inserted into the scleral shell to compress the area and stop

Table 1

The properties of the both groups.

	Age at operation	Male/Female	Indications of evisceration			Systematic or ophthalmic disorder
			Eyeball rupture	Infectious corneal perforation	Absolute glaucoma	
Study group		14/12	6	6	9	15
Control group		16/16	6	7	13	20
Statistics	$W = 721.5$					
<i>P</i>	.476	.797	.752	1	.787	.790

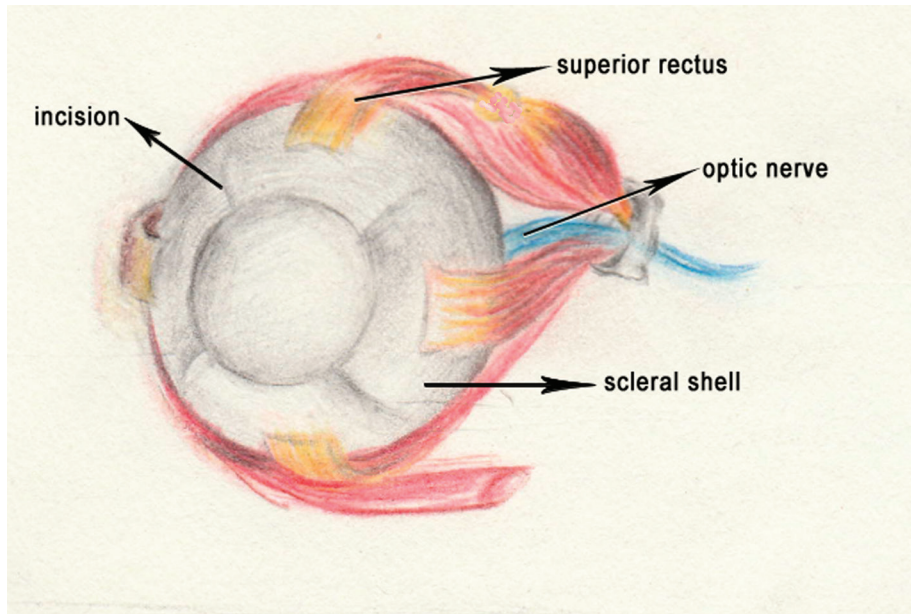


Figure 1. Incised scleral shell after evisceration.

the bleeding for 3 minutes, and then the steel ball was removed. The HA implant was pressed into the scleral shell. The aforementioned posterior scleral cap covered the surface of the HA implant, and the optic nerve end was oriented forward. The end of the optic nerve was then smoothed. The scleral shell flaps and the scleral cap were tightly sutured with 6-0 nylon thread (Fig. 3). At this time, the implant was well wrapped, and then Tenon's capsule and the bulbar conjunctiva were intermittently sutured with 8-0 absorbable thread.

In the control group, the HA implant was pressed into the scleral shell directly. The posterior sclera was unaltered, and the optic nerve was not cut. The scleral shell flaps were tightly sutured with 6-0 nylon thread. Tenon's capsule and the bulbar conjunctiva were sutured with 8-0 absorbable thread. The anterior part of the HA implant was well covered by Tenon's capsule and the bulbar conjunctiva.

2.2. Evaluation of the surgical effect

Visual analog score (VAS) was used to evaluate the 2-month postoperative pain and the 2-month postoperative discomfort. Ten had the highest score, which means that the patient felt the most severe pain and discomfort.

In both groups, HA implant vascularization was measured with enhanced magnetic resonance imaging (MRI) 2 months and 6 months after the operation. The MRI equipment was a Siemens 1.5T superconducting MRI machine with SE sequence scanning. The slice thickness was 3mm, the flash2d sequence was 3mm, and the slice spacing was 0.2mm. Scanning slice thickness MRI was performed with SE sequence, T1WI, T2WI and flash2d sequence. Both the SE sequence and flash2d sequence have transverse axial and coronal planes. Gadolinium diethyl triamine pentaacetic acid (GD DTPA) was used as a contrast enhancement agent. The enhancement volume of the HA

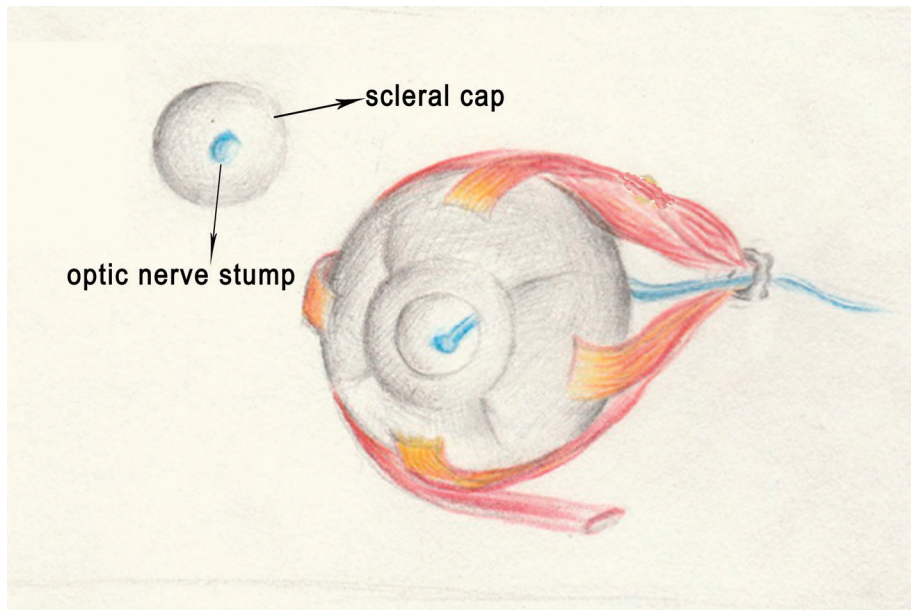


Figure 2. Posterior sclera flap and scleral shell.

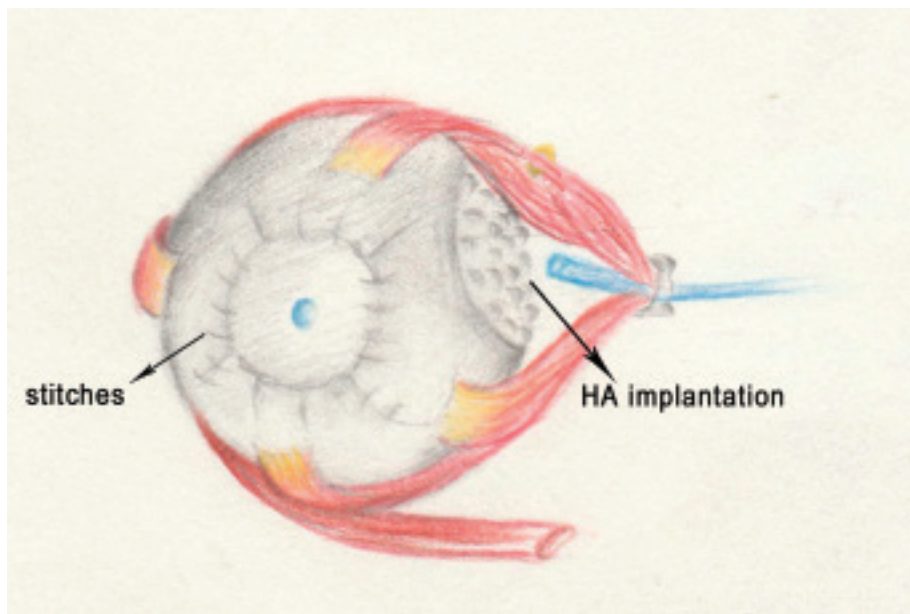


Figure 3. Hydroxyapatite implantation with the autogenous sclera cap.

implant (V_E) and the volume of the HA implant (V_{HA}) were measured, and the V_E/V_{HA} ratios were analyzed.

The 2-month postoperative activity of the artificial eye was measured by the Hirschberg test (corneal reflection) and arc perimetry. Artificial eyes with horizontal activity greater than or equal to 20° and vertical activity greater than or equal to 10° were rated as excellent grade; artificial eyes with horizontal activity less than 10° or vertical activity less than 5° were rated as poor grade; the rest of the artificial eyes were rated as good grade.

In the 2 years of postoperative follow-up, serious complications, including exposure, extrusion and infection, were recorded in both groups.

3. Results

Since the 2-month postoperative pain scores in the study and control groups were not normally distributed (Shapiro–Wilk test, $P=.055$ and $.05$, respectively), the Wilcoxon rank-sum test was used to test the equality of the median scores between the two groups. The median scores of the study and control groups were 2 and 2.5, respectively, and there was a statistically significant difference ($W=585.0$, $P=.004$ two-tailed).

Since the 2-month postoperative discomfort scores in the study and control groups were not normally distributed (Shapiro–Wilk test, $P=.000$, $.031$, respectively), the Wilcoxon rank-sum test was used to test the equality of the median scores between the two groups. The median scores of the

study and control groups were 1 and 2, respectively, and there was a statistically significant difference ($W=535.5$, $P=.000$ two-tailed).

The 2 months postoperative pain and 2 months postoperative discomfort scores are shown in Table 2.

Since the 2-month postoperative V_E/V_{HA} values in the study and control groups were normally distributed (Shapiro–Wilk test, $P=.262$, $.082$, respectively), two independent-sample t tests were used to test the difference between the two groups. The mean values of the study and control groups were 0.3075 and 0.1535, respectively, and there was a statistically significant difference ($t=-8.196$, $P=.000$ two-tailed).

Since the 6-month postoperative V_E/V_{HA} values in the study and control groups were not normally distributed (Shapiro–Wilk test, $P=.000$, $.064$, respectively), the Wilcoxon rank-sum test was used to test the equality of the median scores between the two groups. The median scores of the study and control groups were 0.9686 and 0.5934, respectively, and there was a statistically significant difference ($W=549.0$, $P=.000$ two-tailed).

The values of V_E/V_{HA} in the two groups are shown in Table 3.

The postoperative activity of the HA artificial eye was measured, and the number of cases at each grade is shown in Table 4

There was a statistically significant difference ($P=.016$ two-tailed) between the percentages of excellent grade in the two groups.

Within 2 years of postoperative follow-up, there were no serious complications in the study group. However, there were 3 cases of infection, 2 cases of exposure and 2 cases of extrusion within 2 years of postoperative follow-up in the control group. The overall serious complications were significantly

Table 2
Two months post-operative V_E/V_{HA} .

	2 months post-operative V_E/V_{HA}	6 months post-operative V_E/V_{HA}
Study group	0.3075 ± 0.0672*	0.9686 (0.7568–1)*
Control group	0.1535 ± 0.0841	0.5934 (0.4175–0.9541)
Statistics (value)	$t(-8.196)$	$W(549.0)$
P	.000	.000

2 months post-operative V_E/V_{HA} are shown as mean ± SD (standard deviation) and 6 months post-operative V_E/V_{HA} are shown as median (range).

* $P < .05$ compared with the control group.

Table 3
Post-operative activity.

Artificial eye activity grade	Excellent grade	Good grade	Poor grade
Study group	18 (69.23%)*	6 (23.08%)	2 (7.69%)
Control group	11 (34.37%)	6 (18.75%)	15 (46.88%)
P	.016	1	.001

Data are shown as number (percentage).

* $P < .05$ compared with the control group.

Table 4**Pain and discomfort 2 months after operation.**

	Post-operative pain	Post-operative discomfort
Study group	2 (0–4)*	1 (0–3)*
Control group	2.5 (0–8)	2 (0–5)
<i>W</i>	585.0	535.5
<i>P</i>	0.004	0.000

Data are shown as median (range).

P*<0.05 compared with the control group.Table 5****Serious complications in 2 years follow-up.**

	Infection, exposure and extrusion
Study group	0
Control group	7
<i>P</i>	.013

lower in the study group than in the control group (*P*=.013 two-tailed).

Serious complications within the 2-year follow-up are shown in Table 5.

4. Discussion

Compared to phase I surgery, phase II surgery is more difficult and complex due to fibrosis of the orbital tissue, retraction of the orbital socket and formation of scars on the extraocular muscles. The vascularization of HA prostheses is worse after phase II surgery, and complications such as exposure of the orbital prosthesis are more likely to occur. Therefore, if there is no special condition, the surgeon should first consider phase I implantation.^[5]

Evisceration has good aesthetic and motor properties and rapid postoperative recovery. Some researchers recommend that enucleation should only be preferred in conditions such as intraocular malignant tumors and phthisical eyes,^[2] but the incidence of HA implant exposure after evisceration is higher than is that after enucleation.^[6] This difference is mainly due to the high tension in the anterior part of the scleral shell flaps and the inability to cover all parts of the HA implant.^[1,3,7,8] Our improved surgical technique fundamentally solved this problem and thus significantly reduced the exposure of HA implants. In the study group, the front of the scleral cap was smoother, and the postoperative activity was increased. The scleral cap was closely connected with the anterior scleral shell flaps, and without destroying the recti and the blood supply of the anterior ciliary artery, healing of the anterior scleral cap and the scleral shell flaps was promoted. With less suture and less stimulation of Tenon's capsule in front of the scleral shell, postoperative pain and discomfort were significantly reduced.

In the study group, the posterior sclera was cut off in an approximately 4 to 5mm radius around the optic nerve, and the optic nerve was transected. As a result, postoperative pain was reduced, and the posterior HA implant was in direct contact with the orbit, which was conducive to the vascularization of HA implants.^[8] Thus, our improved surgery also has some advantages of orbital implantation. It has been reported that HA implants have fibrovascular ingrowth at 4 to 6 weeks and complete vascularization at 6 to 8 weeks after implantation and can generally integrate with the surrounding tissues within approximately 6 months.^[9] Incomplete vascularization is the main cause of postoperative exposure to HA implants, most of which occurs within 12 weeks.^[10] Fibrovascularization is of great importance for the long-term stability of HA implants.^[11]

Once the HA implant is completely vascularized, its stability will be further enhanced, and it cannot be easily exposed, extruded or infected. Vascularization of the HA implant is promoted in our improved surgical style largely because the posterior HA implant was directly exposed to the orbit, and thus, the postoperative complications were obviously reduced. In the study group, there were no serious complications, such as exposure, extrusion or infection after surgery.

We believe that how to reduce the tension and exposure of the front of the artificial eye and make the front of the artificial eye smooth is the key to improving the postoperative effect of artificial eye implantation. If the tension in front of the artificial eye is small, the exposure rate of the artificial eye can be reduced to reduce the incidence of infection caused by exposure and extrusion of the artificial eye. If the front of the implant is smooth, the mobility will be good. Previous studies tend to use covers to reduce the anterior tension of the artificial eye to repair artificial eye exposure. The materials used to reduce the tension in front of the artificial eye include allogeneic sclera,^[12] amniotic membrane, hard plate, fascia lata,^[13] retroauricular myoperiosteal,^[14] dermis fat graft,^[15] temporalis fascia, and a pedicled conjunctival flap from the lower eyelid and conjunctiva.^[16] Compared with other materials, such as retroauricular myoperiosteal and temporalis fascia, the sclera is closer to the anatomical and physiological status of the eyeball. Autologous sclera are more convenient to acquire than other materials. Compared with allogeneic materials such as allogeneic sclera, autologous sclera reduces the risk of immune rejection and disease transmission. Moreover, in the presence of a good blood supply, autologous sclera can heal firmly with its surrounding tissues, including the retained scleral shell, while an allogeneic scleral flap can melt^[17] if the blood supply is poor.

This study has several limitations. First, the study is retrospective in nature. Second, the reasons for evisceration of eyeball contents varied greatly. Third, the systematic and ophthalmic conditions of cases varied greatly. Fourth, the follow-up period was not long enough. Fifth, the number of cases was limited. Thus, our improved surgery needs further evaluation.

Acknowledgments

We want to give our appreciation to Fuxing Ma for helping us in drawing the figures. She is an art teacher. Her work unit is Heping Road Campus of Experimental Primary School in Donghai County, Jiangsu Province, China.

Author contributions

Conceptualization: Chongyan Zhu, Hongwei Zhou.

Investigation: Kai Chen, Xiang Zheng.

Project administration: Xiang Zheng.

Resources: Chongyan Zhu, Kai Chen, Xiang Zheng.

Supervision: Chongyan Zhu, Xiang Zheng.

Validation: Chongyan Zhu, Hongwei Zhou.

Visualization: Hongwei Zhou.

Writing – original draft: Chongyan Zhu, Kai Chen, Xiang Zheng.

Writing – review & editing: Hongwei Zhou.

References

- Aggarwal H, Kumar P, Eachempati P, Alvi HA. Different intraorbital implant situations and ocular prosthetic rehabilitation. *J Prosthodont* 2016;25:687–93.
- Catalu CT, Istrate SL, Voinea LM, Mitulescu C, Popescu V, Radu C. Ocular implants-methods of ocular reconstruction following radical surgical interventions. *Rom J Ophthalmol* 2018;62:15–23.
- Jordan DR, Bawazeer A. Experience with 120 synthetic hydroxyapatite implants (FC13). *Ophthalm Plast Reconstr Surg* 2001;17:184–90.

- [4] Lin CW, Liao SL. Long-term complications of different porous orbital implants: a 21-year review. *Br J Ophthalmol* 2017;101:681–5.
- [5] Thiesmann R. Motility and lid changes with coralline hydroxyapatite orbital implants and cryolite glass ocular prostheses. *Ophthalmologie* 2018;115:794–6.
- [6] Jordan DR, Gilberg S, Bawazeer A. Coralline hydroxyapatite orbital implant (bio-eye): experience with 158 patients. *Ophthalmic Plast Reconstr Surg* 2004;20:69–74.
- [7] Medel R, Cicinelli MV, Arboleda JC, et al. Retroauricular myoperiosteal autograft for orbital implant exposure: 11 years of experience. *Orbit* 2020;39:342–9.
- [8] Sobti MM, Shams F, Jawaheer L, Cauchi P, Chadha V. Unwrapped hydroxyapatite orbital implants: our experience in 347 cases. *Eye (Lond)* 2020;34:675–82.
- [9] Shields CL, Shields JA, Eagle RC Jr, et al. Histopathology evidences of fibrovascular in growth four weeks after placement of the hydroxyapatite orbital implant. *Am J Ophthalmol* 1991;111:363–6.
- [10] Remulla HD, Rubin PA, Shore JW, et al. Complications of porous spherical orbital implants. *Ophthalmology* 1995;102:586–93.
- [11] PopaCherecheanu A, Istrate S, Iancu R, et al. Nanostructured hydroxyapatite used as an augmenting material to expand the orbit. *Acta Ophthalmol* 2017;95. doi: 10.1111/j.1755-3768.2017.01192.
- [12] Goldberg MF. A simplified scleral graft technique for covering an exposed orbital implant. *Ophthalmic Surg* 1988;19:206–11.
- [13] Lee-Wing MW. Amniotic membrane for repair of exposed hydroxyapatite orbital implant. *Ophthalmic Plast Reconstr Surg* 2003;19:401–2.
- [14] Wang JK, Lai PC. Bioceramic orbital implant exposure repaired by a retroauricular myoperiosteal graft. *Ophthalmic Surg Lasers Imaging* 2008;39:399–403.
- [15] Lee BJ, Lewis CD, Perry JD. Exposed porous orbital implants treated with simultaneous secondary implant and dermis fat graft. *Ophthalmic Plast Reconstr Surg* 2010;26:273–6.
- [16] Pelletier CR, Jordan DR, Gilberg SM. Use of temporalis fascia for exposed hydroxyapatite orbital implants. *Ophthalmic Plast Reconstr Surg* 1998;14:198–203.
- [17] Liao SL, Kao SC, Tseng JH, Lin LL. Surgical coverage of exposed hydroxyapatite implant with retroauricular myoperiosteal graft. *Br J Ophthalmol* 2005;89:92–5.