

Inside-out abrasion and contained conductor cable externalization in a defibrillation lead with asymmetric conductor cable lumen distribution



Ernest W. Lau, MD, Michael J.D. Roberts, MD

From the Department of Cardiology, Royal Victoria Hospital, Belfast, Northern Ireland.

Introduction

Inside-out abrasion (IOA) is a distinct mode of insulation damage caused by conductor cables moving relative to the lead body, and may result in conductor cable externalization (CCE) and electric malfunction.^{1–3} IOA/CCE mainly affects defibrillation (DF) leads and has so far been observed only in models with symmetric conductor cable lumen distribution—the Riata^{1,2} and Durata^{4,5} leads by St Jude Medical/Abbott (Sylmar, CA) and the Kentrox^{6,7} and Linox⁸ leads by Biotronik (Berlin, Germany). This report describes the first case of IOA/CCE in a DF lead with asymmetric conductor cable lumen distribution: the Sprint Quattro Secure lead by Medtronic (Minneapolis, MN).

Case report

A female patient with nonischemic dilated cardiomyopathy (left ventricular ejection fraction 12%), severe mechanical dyssynchrony, and left bundle branch block (QRS duration 160 ms) underwent cardiac resynchronization therapy defibrillator (CRTD) implantation with an active-fixation single-coil DF lead (Sprint Quattro Secure 6935, Medtronic) to the right ventricle (RV), an active-fixation bipolar pacing lead (CapsureFix Novus 5076, Medtronic) to the right atrium (A), and a passive-fixation bipolar pacing lead (Attain Ability Straight 4396, Medtronic) to the left ventricle (LV) at the age of 75. Five years later, the CRTD pulse generator was replaced for battery depletion. The new pulse generator (Itre-*via* 7 ProMRI HF-T, Biotronik) was programmed to the DDD mode. Seven months later, remote alert was triggered on the new device owing to an abrupt drop in biventricular pacing

(Figure 1A), which coincided with an equally abrupt rise in the frequency of premature ventricular complexes (PVCs) (Figure 1B). When the device was interrogated, the A and LV channels showed clean signals, but the near-field (tip-to-ring) RV channel showed discrete perisystolic (just before or after atrial and ventricular electric activation) nonphysiologic noises (Figure 1C). Most noise signals were too small to be detected (RV channel sensitivity 0.8 mV; mean R-wave amplitude 4.6 mV). If detected, the noises were counted as PVCs or RV sensed events, and caused any closely coupled genuine A and RV events to be blanked out or mislabeled as ventricular fibrillation, respectively. Nonphysiologic noises were also evident in the far-field (coil-to-can) channel, but were more obvious if they occurred before (separate from) and not after (overlapped with) the much larger R waves (Figure 1D). The pacing thresholds and impedances, sensed P- and R-wave amplitudes, and shock impedance remained stable (Figure 1E). The last measured RV pacing and shock impedances were 392 Ω and 85 Ω , respectively.

DF lead failure was diagnosed and the patient was admitted for lead extraction and replacement. Pre-extraction, the tip of the DF lead was on the mid RV septum and the proximal end of the shock coil formed the “nadir” of its intracardiac course (Figure 2A). A kink existed in 1 of the 2 conductor cables just proximal to the shock coil (Figure 2B) and was not present when the lead was first implanted (Figure 2C). The turns of the shock coil were tightly packed. The DF lead was extracted with a lead locking device (Spectranetics, Colorado Springs, CO) and a rotating dilator sheath (TightRail, Spectranetics) (Figure 2D). As traction was applied, the proximal turns of the shock coil separated and the lead suddenly broke free (Figure 2E). The tip of the rotating dilator sheath was approximately 2 cm ($\approx 6 \times$ lead body width) proximal to the shock coil at that point. The lead was pulled out of the body without further active cutting by the rotating dilator sheath. A new DF lead was implanted and the pre-existent device reused. The revised CRTD system was functioning normally at 3 months follow-up.

Inspection of the extracted Sprint Quattro Secure lead immediately post extraction showed significant fibrous

KEYWORDS Inside-out abrasion; Conductor cable externalization; Sprint Quattro Secure; Defibrillation lead failure; Nonphysiologic noise; High-low voltage circuit crosstalk
(Heart Rhythm Case Reports 2018;4:121–126)

The publication fee for the article was met by an unrestricted educational grant from the Regional Medical Cardiology Centre of the Royal Victoria Hospital, Belfast, Northern Ireland. Conflicts of interest: E.W.L.: consultancy for Abbott; M.J.D.R.: none. **Address reprint requests and correspondence:** Dr Ernest W. Lau, Department of Cardiology, Royal Victoria Hospital, Grosvenor Road, Belfast BT12 6BA, UK. E-mail address: ernest.lau@btinternet.com.

KEY TEACHING POINTS

- All defibrillation lead models may be inherently vulnerable to inside-out abrasion (IOA) and conductor cable externalization (CCE), but to different extents.
- Inside-out abrasion of insulation by the ring electrode conductor cable under the right ventricular shock coil can cause intermittent physical contact between the 2 components and set up crosstalk between the high and low voltage circuits through conductive coupling.
- High-low voltage circuit crosstalk may generate only discrete, low-amplitude, perisystolic nonphysiologic noises.
- High-low voltage circuit crosstalk may or may not be detected by diagnostic algorithms based on short V-V intervals, impedance changes, or near-field/far-field electrogram discordance.
- Only systematically cross-sectioning all defibrillation leads (including those with asymmetric conductor cable lumen distribution) returned for analysis will reveal the true prevalence of IOA/CCE.

adhesions only around the proximal end of the shock coil (close to the “nadir” of the lead’s intracardiac course, [Figure 2A](#)) but not elsewhere, and very little damage to the lead by the extraction process ([Figure 2F](#)). A conductor cable protruded through a breach in the silicone insulation between the shock coil and the polyurethane overlay. Old, dark blood was seen in the lead body both close to and distant from the insulation breach. Fresh, lighter blood was seen closer to the insulation breach than old dark blood in the adjacent proximal lead body ([Figure 2G](#)). The fibrous adhesions were thicker over the proximal than toward the distal end of the shock coil ([Figure 2H](#)). The insulation breach had ragged edges and was filled with biologic debris and altered blood ([Figure 2I](#)). The conductor cable welded to the shock coil had a kink proximal to it and was distinct from the ring electrode cable protruding through the insulation breach. The proximal turns of the shock coil were displaced distally relative to their grooves in the medical adhesive.

The extracted Sprint Quattro Secure lead, which has asymmetric conductor cable lumen distribution ([Figure 3A](#)), was returned to the manufacturer for analysis. The silicone insulation had a broad linear defect approximately 5 mm long and as wide as the conductor cable under the shock coil, and a narrow irregular tear in the gap between the shock coil and the polyurethane overlay ([Figure 3B, C, and D](#)). The ethylene tetrafluoroethylene (ETFE) coating of the exposed ring electrode cable segment had a scaphoid defect with loss of material and linear scratch marks at both

ends ([Figure 3E](#)) and exposed metal (sprinkled with spalls of platinum transferred from the shock coil) in the center ([Figure 3F](#)). The manufacturer reported no issues with the lead’s production.

Discussion

The nonphysiologic noises in this case were most likely high-low voltage circuit crosstalk through conductive coupling between the RV shock coil and the ring electrode cable, and differ from those attributable to conductor fracture in being discrete (ie, not continuous), perisystolic (possibly related to cardiac motions), and low in amplitude.⁴ Most of the noise signals were not detected, and those detected were counted as PVCs rather than as ventricular tachycardia or ventricular fibrillation episodes. Noises were also present in the far-field channel, but were more obvious if they occurred in front of and did not just distort the terminal deflection of the much larger R waves. Lead failure was suspected because the nonphysiologic noises inhibited biventricular pacing, and might or might not have been detected by diagnostic algorithms based on short V-V intervals (eg, the Sensing Integrity Counter and Lead Integrity Alert by Medtronic), impedance changes, or near-field/far-field electrogram discordance (eg, the Lead Noise Algorithm by Medtronic and the SecureSense Noise Discrimination Algorithm by St Jude Medical/Abbott).⁹ The pacing and shock impedances stayed stable, probably because the shock coil and the ring electrode cable were not in physical contact when the device performed automatic impedance checks. If the shock coil and the ring electrode cable had been in physical contact, the shock coil would have greatly increased the effective surface area of the ring electrode and hence reduced the RV pacing impedance, but the ring electrode would have had minimal impact on the effective surface area of the shock coil and hence the shock impedance.⁴

The proximal end of the shock coil was fixed to the endocardial surface by fibrous adhesions ([Figure 2A, F, and H](#)). The adhesions were thinly and evenly spread over the proximal end of the shock coil, suggesting that they formed in vivo and were not displaced there from more proximal parts of the lead body during extraction. When traction was applied to the lead during extraction, the proximal end of the shock coil extended (and the turns of the coil separated, [Figure 2D and E](#)), but to a lesser degree than the underlying silicone insulation, owing to fibrous adhesions. When tension was suddenly released as the lead broke free, the turns of the proximal end of the shock coil did not return to their original positions and remained more widely spaced and displaced distally relative to the underlying silicone insulation ([Figures 2I and 3B, C, and D](#)).

The breach in the silicone insulation in the gap between the shock coil and the polyurethane overlay is consistent with abrupt rupture, with its ragged edges and little loss of material ([Figures 2I and 3B, C, and D](#)). The juxtaposition of fresh, lighter blood closer to the insulation breach than old, dark blood suggests that the tear formed during

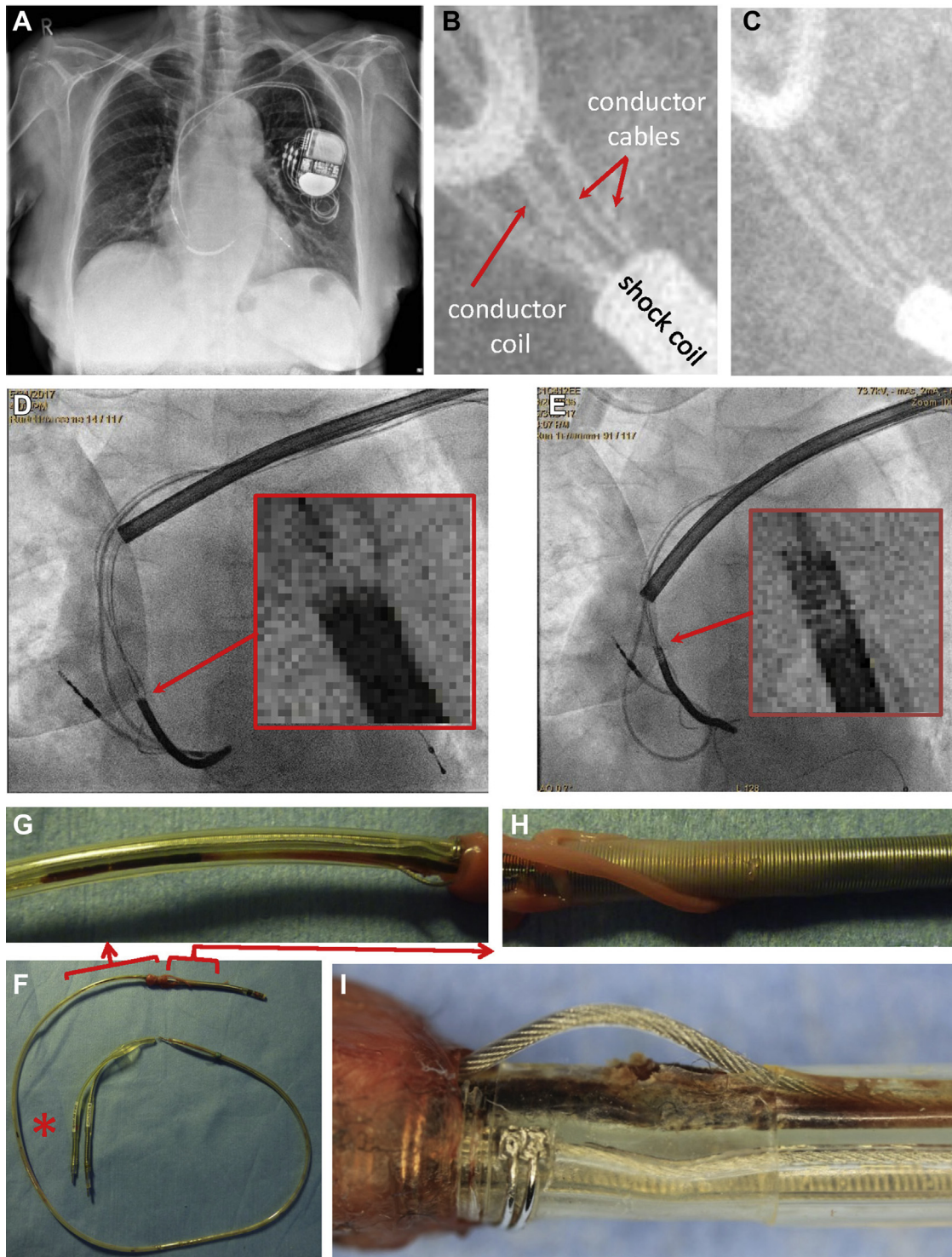


Figure 2 Failed Sprint Quattro Secure lead before, during, and after extraction. **A:** Pre-extraction chest radiograph. **B:** Kink in a conductor cable. **C:** No kink in conductor cables immediately post lead implantation. **D:** Beginning of extraction. **E:** The lead broke free. **F:** Fibrous adhesions were seen only around the proximal end of the shock coil along the entire extracted lead. A conductor cable protruded through a breach in the insulation. Old, dark blood was seen in the lead body, both close to and distant from (*red asterisk*) the insulation breach. **G:** Old, dark blood was further away than fresh, lighter blood from the insulation breach and conductor cable protrusion. **H:** The fibrous adhesions were thicker around the proximal than toward the distal end of the shock coil. **I:** The breach in the silicone insulation between the shock coil and the polyurethane overlay had ragged edges and was filled with biologic debris and altered blood. The conductor cable protruding through the insulation breach was connected to the ring electrode. The shock coil cable had a kink just proximal to its weld to the coil. The proximal turns of the shock coil were separated and displaced distally.

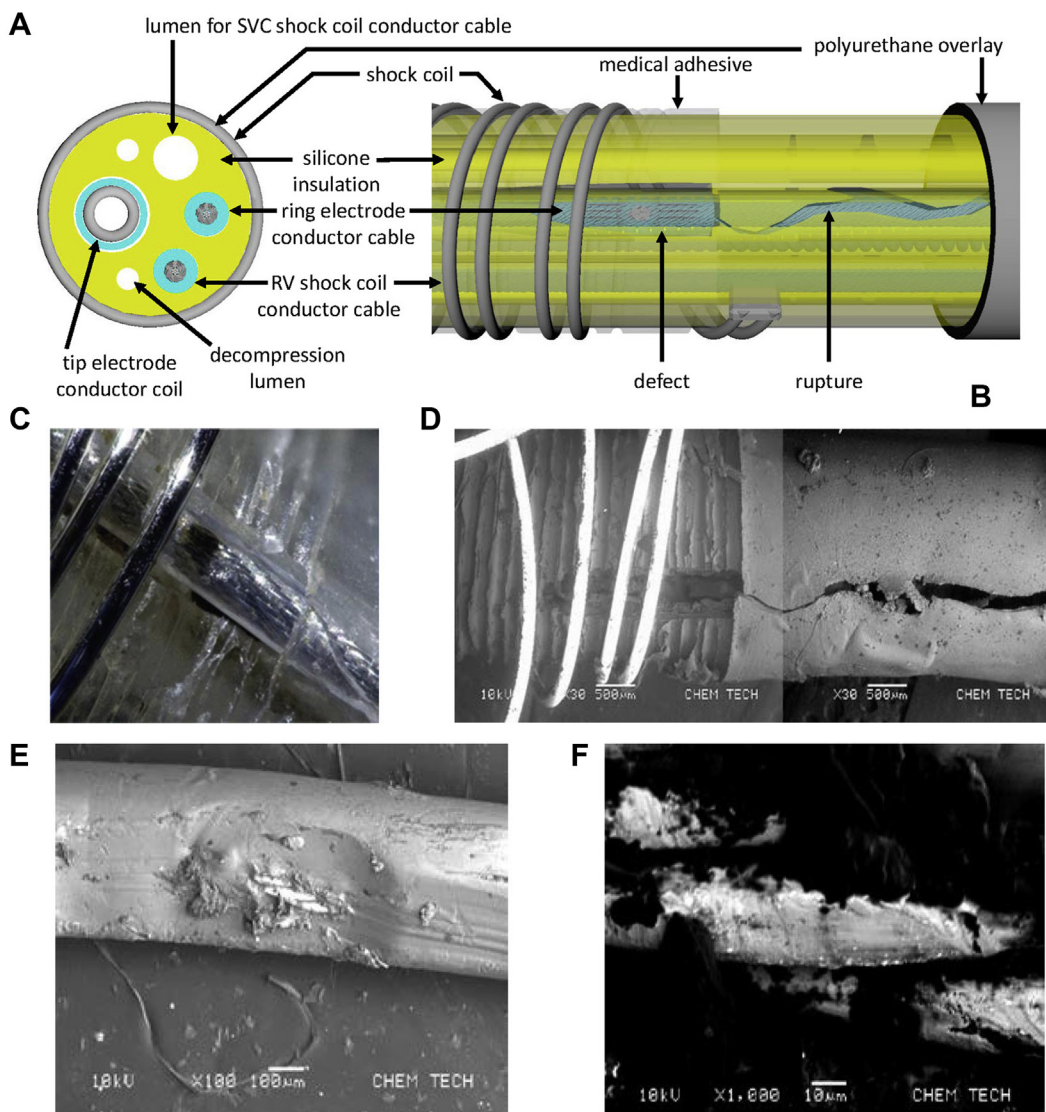


Figure 3 Structure and defects of the failed Sprint Quattro Secure lead. **A:** Cross section of the lead. SVC = superior vena cava; RV = right ventricle. **B:** Diagram of the lead damages. **C:** The externalized conductor cable loop had been pulled back inside the lead body. The proximal turns of shock coil were displaced distally from their grooves in the medical adhesive. The silicone insulation breach was a broad linear defect (loss of material) under the coil and a narrow irregular tear (ragged edges; little loss of material) between the coil and the polyurethane overlay. **D:** The ring electrode cable had been removed. The silicone insulation defect under the shock coil was “undermined” (more extensive inside than outside) and tapered toward the lead tip. **E:** The ring electrode cable segment exposed in the silicone insulation defect under the shock coil had a scaphoid defect with loss of material and linear scratch marks at both ends in its ethylene tetrafluoroethylene coating. **F:** The exposed metal strands of the conductor cable were flattened and sprinkled with spalls of platinum (bright spots) transferred from the shock coil. The dark materials were biologic debris. (Images C, D, E, and F used with permission of Medtronic, Inc.)

extraction (Figure 2G). The silicone insulation already had a breach over the ring electrode cable under the proximal end of the shock coil pre-extraction (Figure 3B, C, and D). When tension was applied to the cut-and-tied proximal end of the lead during extraction, the silicone insulation (and the conductor coil to the tip electrode) at the lead’s fixation to the RV endocardial surface by fibrous adhesions (which coincided with a bend in its anatomic course in vivo) extended in response (Figure 2D and E), but the conductor cables could not. The ring electrode cable was forced to adopt a shorter course with a lesser curvature than the lead body by protruding out of the insulation breach under the shock coil, which gave it a mechanical advantage in tearing through the immediately proximal silicone insulation. A short segment of

the ring electrode cable became externalized through the tear and formed a loop outside the lead body after tension was released, as it was longer than the tear in the silicone insulation in its unstressed state (Figure 2I).

The breach in the silicone insulation under the proximal end of the shock coil was a broad linear defect with significant loss of material (Figure 3B, C, and D). The ring electrode cable had a scaphoid defect in its ETFE coating, with loss of material, adjacent linear scratch marks (Figure 3E), and an exposed metal center sprinkled with spalls of platinum transferred from the shock coil (Figure 3F). These features strongly suggest IOA of the silicone insulation and the shock coil by the ring electrode cable: the silicone insulation was first worn through by the cable; the ETFE coating of the cable

was then scraped away by the shock coil; and finally, the shock coil and the metal conductor of the cable rubbed against each other, giving rise to nonphysiologic noises on both the near-field (tip-to-ring) and far-field (coil-to-can) channels (Figure 1C and D). The insulation breach was unlikely to have been caused by outside-in abrasion¹⁰ because of cover by fibrous adhesions and the shock coil.

The exact mechanism of IOA/CCE is not known with certainty yet, but differential lead component pulling has been proposed as a theoretical model.¹¹ The kink in the shock coil conductor cable (Figure 2B, C, F, and I) is a common manufacturing feature of the lead and does not indicate damage, but does imply cable length redistribution and provide evidence that differential lead component pulling occurred in vivo. Design features such as lead diameter (7–8F for the Riata; 7F for the Riata ST, Riata ST Optim, and Durata leads; 9.3F for the Kentrox leads; 7.8F for the Linx leads; 8.6F for the Sprint Quattro Secure leads), extra overlay (Optim for the Riata ST Optim and Durata leads, polyurethane for the Sprint Quattro Secure leads), and conductor cable lumen distribution in the lead body (symmetric for the Riata, Durata, Kentrox, and Linx leads; asymmetric for the Sprint Quattro Secure, Endotak Reliance, and Reliance 4-Front leads) do not confer complete immunity from IOA/CCE. A helical arrangement of conductor cables around the central conductor coil in the intracardiac segment of the DF lead (the Plexa Pro MRI leads, Biotronik) may reduce the local mechanical stresses and possibly the risk of IOA.

All DF lead designs may be inherently vulnerable to IOA/CCE, although to different degrees, and will manifest the phenomena, given the requisite use conditions and duration. IOA can produce high-low voltage circuit crosstalk through conductive coupling that may or may not be detectable by the existent diagnostic algorithms. Only systematically cross-sectioning all DF leads (including those with

asymmetric conductor cable lumen distribution) returned for analysis will reveal the true prevalence of IOA/CCE.

Acknowledgments

The authors thank Mark Marshall, Jennifer Miller, and Adam Himes from Medtronic for helpful comments.

References

1. Hauser RG, McGriff D, Retel LK. Riata implantable cardioverter-defibrillator lead failure: analysis of explanted leads with a unique insulation defect. *Heart Rhythm* 2012;9:742–749.
2. Parkash R, Thibault B, Mangat I, et al. Canadian registry of implantable electronic device outcomes: surveillance of the Riata lead under advisory. *Circ Arrhythm Electrophysiol* 2016;9:e004282.
3. Zeitler EP, Pokorney SD, Zhou K, Lewis RK, Greenfield RA, Daubert JP, Matchar DB, Piccini JP. Cable externalization and electrical failure of the Riata family of implantable cardioverter-defibrillator leads: a systematic review and meta-analysis. *Heart Rhythm* 2015;12:1233–1240.
4. Swerdlow CD, Kass RM, Khoynzhad A, Tang S. Inside-out insulation failure of a defibrillator lead with abrasion-resistant coating. *Heart Rhythm* 2013;10:1063–1066.
5. Mann IE, Segal OR. A case of Durata ICD lead coil externalization: inside-out lead abrasion? *HeartRhythm Case Rep* 2016;2:283–285.
6. Bogossian H, Mijic D, Frommeyer G, Winter J. Insulation failure and externalized conductor of a single-coil Kentrox lead: an ongoing story? *J Cardiovasc Electrophysiol* 2015;26:226–227.
7. De Maria E, Borghi A, Bonetti L, Fontana PL, Cappelli S. Externalized conductors and insulation failure in Biotronik defibrillator leads: history repeating or a false alarm? *World J Clin Cases* 2017;5:27–34.
8. Howe AJ, McKeag NA, Wilson CM, Ashfield KP, Roberts MJ. Insulation failure of the Linx defibrillator lead: a case report and retrospective review of a single center experience. *J Cardiovasc Electrophysiol* 2015;26:686–689.
9. Swerdlow CD, Kalahasty G, Ellenbogen KA. Implantable cardiac defibrillator lead failure and management. *J Am Coll Cardiol* 2016;67:1358–1368.
10. Kolodzinska K, Kutarski A, Grabowski M, Jarzyna I, Malecka B, Opolski G. Abrasions of the outer silicone insulation of endocardial leads in their intracardiac part: a new mechanism of lead-dependent endocarditis. *Europace* 2012;14:903–910.
11. Lau EW. Differential lead component pulling as a possible mechanism of inside-out abrasion and conductor cable externalization. *Pacing Clin Electrophysiol* 2013;36:1072–1089.