



## Midterm results of periprostatic coiling embolization in high-risk patients

Xiantao Li, Yanyan Huang, Pingfan Guo\*

Vascular Surgery Department, The First Affiliated Hospital of Fujian Medical University, Fuzhou, China



### ARTICLE INFO

**Keywords:**  
Aortic aneurysm  
Abdominal  
Radiology  
Interventional  
Endoleak  
Risk assessment

### ABSTRACT

**Background:** With increasing interest in the prevention of type II endoleaks (EII), the aim of this study was to report midterm results on the intraoperative coiling embolization of the periprostatic aneurysmal sac in patients at high-risk of EII.

**Methods:** A retrospective review study was conducted with 124 patients with infrarenal abdominal aortic aneurysm who accorded with the inclusion criteria, including 66 patients who underwent standard endovascular aortic aneurysm repair (Group A) and 58 patients who underwent aneurysmal sac coiling embolization (Group B). Baseline data and follow-up results were analyzed.

**Results:** A mean of  $2.84 \pm 1.45$  coils (range 1–9) were used in Group B. The general incidence of an EII was 15.32% (19/124) at a mean follow-up time of  $46.60 \pm 15.14$  months, with 22.7% (15/66) in Group A and 6.9% (4/58) in Group B ( $\chi^2 = 5.62$ ;  $P = 0.018$ ). Logistic multivariate analysis revealed that the independent risk factors of an EII were no sac embolization and a sac volume  $\geq 128 \text{ cm}^3$ . The Kaplan-Meier subgroup analysis showed no difference in regard to the rate of freedom from EII between the two groups either with a larger or smaller sac.

**Conclusions:** These results suggest that periprostatic coiling embolization in patients at high-risk of EII is safe and effective in the prevention of EII. The preventive effect seemed to be weakened when the sac volumes were taken into consideration at midterm follow-up.

### Introduction

Type II endoleaks (EIIs) may lead to enlargement or even rupture of the aneurysmal sac.<sup>1</sup> Vascular surgeons have developed several active measures to prevent EII, one of which is intraoperative perigraft aneurysmal sac embolization (PASE). It has been suggested that the intrasac injection of fibrin glue with or without the utilization of the coils is a safe, simple, and effective technique to reduce the incidence of EIIs<sup>2,3</sup>. However, another study demonstrated that it was only effective when used in patients at high-risk of EII<sup>4</sup>. Thus, the aim of this study was to report midterm results with intraoperative coiling embolization of the periprostatic aneurysmal sac in patients at high-risk of EII.

### Material and methods

#### Patient selection for high-risk EII

Since this study is a retrospective and observational study, informed consent was waived, though institutional review board approval was

obtained (protocol number: IEC-FOM-013-2.0). Generally, patients are considered to be at high-risk for EII when they meet one of the following conditions: (1) a patent inferior mesenteric artery (IMA)  $> 3 \text{ mm}$ ; (2)  $\geq 3$  pairs of lumbar arteries (LAs); (3) two pairs of LAs and a sacral artery or an accessory renal artery (RA) or any diameter ( $< 3 \text{ mm}$ ) patent IMA.<sup>5,6</sup>

#### Inclusion criteria

Patients in this study were selected from January 2013 through January 2017. All patients with infrarenal abdominal aortic aneurysm (AAA) treated by endovascular aortic repair that met all of the following characteristics were included: aneurysmal neck length  $\geq 15 \text{ mm}$ , neck angulation  $< 60^\circ$ , diameter of the external iliac artery  $\geq 7 \text{ mm}$ , and a distal sealing length  $\geq 20 \text{ mm}$ . Patients with Marfan syndrome, an inflammatory aneurysm, a ruptured AAA, and those who underwent complex endovascular repair (such as renal parallel grafts or fenestrated grafts), or open surgery or hybrid surgery were excluded. Patients with follow-up periods of less than 6 months were excluded from the study. Patients with type I/III endoleaks at the final angiography were also

\* Corresponding author. Vascular Surgery Department, The First Affiliated Hospital of Fujian Medical University, 350004, 20# Chazhong road, Taijiang District, Fuzhou, Fujian, China.

E-mail address: [lxtfreedom@126.com](mailto:lxtfreedom@126.com) (P. Guo).

<https://doi.org/10.1016/j.jimed.2019.10.004>

Available online 23 October 2019

2096-3602/Copyright © 2019 Shanghai Journal of Interventional Medicine Press. Production and hosting by Elsevier B.V. on behalf of KeAi. This is an open access

article under the CC BY-NC-ND license (<http://creativecommons.org/licenses/by-nc-nd/4.0/>).

excluded from the study. In total, 124 cases were selected for this study, including 66 standard endovascular aortic aneurysm repairs (EVARs) (Group A) and 58 periprosthesis aneurysmal sac coiling embolizations during EVAR (Group B). The patient characteristics are summarized in Table 1.

### Aneurysm evaluation and procedures

The computed tomography angiography (CTA) results were analyzed using Vitrea software (version 6.0; Vital Images, Inc., Minnetonka, MN USA) for aneurysmal sac volume, thrombus volume, maximum transverse aneurysm diameter, neck diameter, and neck angulation (Fig. 1). The interlocking platinum coils (Boston Scientific Corp., Marlborough, MA USA) were detachable and fibered and were used only in Group B.

Procedure: Either a cut-down or a percutaneous method was followed for accessing the bilateral femoral arteries with the standard Seldinger technique. A second puncture intended for sac embolization was made contralateral to the side of the body, just below the first femoral puncture, and a 5-F catheter was placed into the sac. Once the standard EVAR was completed, another angiogram via the reserved catheter was performed inside the aneurysmal sac using 3–5 mL of contrast agent to identify the location of the ostia of the IMA and the LAs, which were targeted by the coils subsequently. The coils were introduced through the 5-F catheter that had been previously placed inside the aneurysmal sac and outside the stent-grafts. The complete sac thrombosis usually requires more than 3 min after deployment of the coils. More coils would be advanced into the sac if the aneurysmal sac was still visible fluoroscopically.

### Definitions

Technical success was defined as the successful implantation of the stent-grafts, exclusion of the aneurysm, and no leakage of the contrast agent in the aneurysmal sac. In Group B, the technical success included

**Table 1**  
Clinical characteristics and aneurysmal sac parameters.

Factors	Group A (n = 66)	Group B (n = 58)	P
Male, n (%)	59 (89.4%)	52 (89.7%)	0.71
Age (years)	71.07 ± 6.43	72.05 ± 5.33	0.34
Age >79 years, n (%)	9 (13.6%)	6 (10.3%)	0.52
Body mass index	21.29 ± 2.79	21.65 ± 3.00	0.28
Current smoker, n (%)	15 (22.7%)	8 (13.8%)	0.09
<b>Comorbidities, n (%)</b>			
Hypertension	42 (21.2%)	43 (74.1%)	0.46
Diabetes	10 (15.2%)	4 (6.9%)	0.71
<sup>a</sup> CAD	13 (19.7%)	12 (20.7%)	0.53
<sup>a</sup> PAD	9 (13.6%)	5 (8.6%)	0.19
<sup>a</sup> AF	2 (3.0%)	1 (1.7%)	0.95
<b>Inflammatory test</b>			
<sup>a</sup> CRP (mg/L)	28.21 ± 16.58	27.12 ± 20.09	0.32
<sup>a</sup> ESR (mm/h)	18.43 ± 16.52	20.29 ± 19.80	0.36
<b>Aneurysm parameters-</b>			
<sup>b</sup> SV (cm <sup>3</sup> )	128.16 ± 64.00	130.61 ± 57.71	0.19
<sup>b</sup> MTV/SV %	–	–	0.30
0–35%, n (%)	27 (40.9%)	21 (36.2%)	–
36%–75%, n (%)	38 (57.6%)	35 (60.3%)	–
76%–100%, n (%)	1 (1.5%)	1 (1.7%)	–
<sup>b</sup> MTD (mm)	56.55 ± 9.36	57.34 ± 9.25	0.37
Patent IMA <sup>a</sup> , n (%)	52 (78.8%)	45 (77.6%)	0.22
Pairs of LAs <sup>a</sup>	2.77 ± 0.79	2.82 ± 0.57	0.64
Accessory RA <sup>a</sup> , n (%)	9 (13.6%)	9 (15.5%)	0.17
Mono-lateral IA <sup>a</sup>	17 (25.8%)	14 (21.2%)	0.71
Bilateral IA, n (%)	6 (9.1%)	4 (6.9%)	0.53

<sup>a</sup> CAD: coronary artery disease; PAD: peripheral arterial disease; AF: atrial fibrillation; ESR: erythrocyte sedimentation rate; CRP: C-reactive protein; IMA: inferior mesenteric artery; LA: lumbar artery; RA: renal artery; IA: iliac aneurysm.

<sup>b</sup> SV: Sac volume; MTV: Mural thrombus volume; MTD: maximum transverse diameter.

the successful sac coiling embolization which reached complete sac thrombosis. The endpoint was defined as any type of endoleak confirmed by CTA at 1, 3, 6, and 12 months postoperatively. The cut-off value in this paper was calculated from this single-center database. The mean aneurysmal sac volume (SV) of 887 patients with infra-renal AAA was  $128.35 \pm 67.22 \text{ cm}^3$  (35.1–414.3 cm<sup>3</sup>) (unpublished). To better understand the factors influencing the incidence of EII and conduct a sub-group analysis, a cut-off of 128 cm<sup>3</sup> was arbitrarily set. Sac volume <128 cm<sup>3</sup> was defined as small, and sac volume  $\geq 128 \text{ cm}^3$  was defined as large.

### Statistical analysis

SPSS Statistics ver. 19.0 (IBM Corp., Armonk, NY USA) was used to conduct the statistical analysis. Binary logistic multivariate analysis was used to evaluate the factors related to EII. Kaplan-Meier survival analysis was used to compare “freedom from EII” between the two groups. A level of significance was set as a P value < 0.05.

### Results

The two groups were comparable in terms of baseline characteristics and sac parameters, which are summarized in Table 1. The mean aneurysm sac volume was similar for both groups ( $128.16 \pm 64.00 \text{ cm}^3$  vs.  $130.61 \pm 57.71 \text{ cm}^3$  for Groups A and B, respectively). The LAs and accessory renal arteries were those originating from the aneurysm. An iliac aneurysm excludes an isolated aneurysm of the external iliac artery or the internal iliac artery. Each group achieved a technical success rate of 100%. The clinical success rate was 97% (64/66) in Group A due to a femoral infection and a type Ib endoleak detected within 30 days and 98.3% (57/58) in Group B due to an acute limb ischemia which was revascularized subsequently. During the procedure, local anesthesia and percutaneous EVAR was applied to 59.1% (39/66) and 22.7% (15/66) of patients in Group A, respectively, compared with 86.2% (50/58) and 82.8% (48/58), respectively, in Group B. The procedure time and radiation exposure time was  $144.58 \pm 50.12 \text{ min}$  and  $24.16 \pm 7.80 \text{ min}$ , respectively, for Group A and  $146.18 \pm 51.23 \text{ min}$  and  $25.75 \pm 8.23 \text{ min}$ , respectively, for Group B. Endografts from Medtronic (Medtronic Plc, Dublin, Ireland) were the principal devices for both groups (46/66 in Group A versus 38/58 in Group B). The mean aneurysm sac volume was similar for both groups ( $128.16 \pm 64.00 \text{ cm}^3$  vs.  $130.61 \pm 57.71 \text{ cm}^3$  in Groups A and B, respectively). Each group achieved a technical success rate of 100%. The mean number of coils used in Group B was  $2.84 \pm 1.45$  (1–9). The mean follow-up time with CTA imaging was  $47.73 \pm 18.83$  months for Group A and  $45.33 \pm 12.45$  months for Group B. The different incidence of EII at 12 months and at final follow-up evaluation are summarized in Table 2. The incidence of EII was lower in Group B than in Group A, if the ever-changing EIIs were not considered. We also analyzed what factors were related to EII among these high-risk patients after the operation, and a multivariate analysis was conducted (Table 3). All variables that potentially predict the occurrence of EII in the univariate analysis were collected in the standardized multivariate analysis which demonstrated that no sac embolization and an  $SV \geq 128 \text{ cm}^3$  were independent risk factors for EII development. To better understand the effect of sac embolization with different sac volumes, a subgroup study with a Kaplan-Meier analysis was conducted (Fig. 2a and b). This analysis showed that there were no significant differences regarding the rate of freedom from EII observed between two groups either with a larger sac volume or a smaller sac volume as the follow-up time lengthened.

### Discussion

In this study, the general incidence of EII was 15.32% (19/124) at a mean follow-up time of  $46.60 \pm 15.14$  months, which is in accordance with previous reports.<sup>6,7</sup> A key point of intraoperative perigraft aneurysmal sac embolization (PASE) refers to whether it is adequately embolized using coils or liquid embolic agents.<sup>8</sup> used a fibrin sealant for

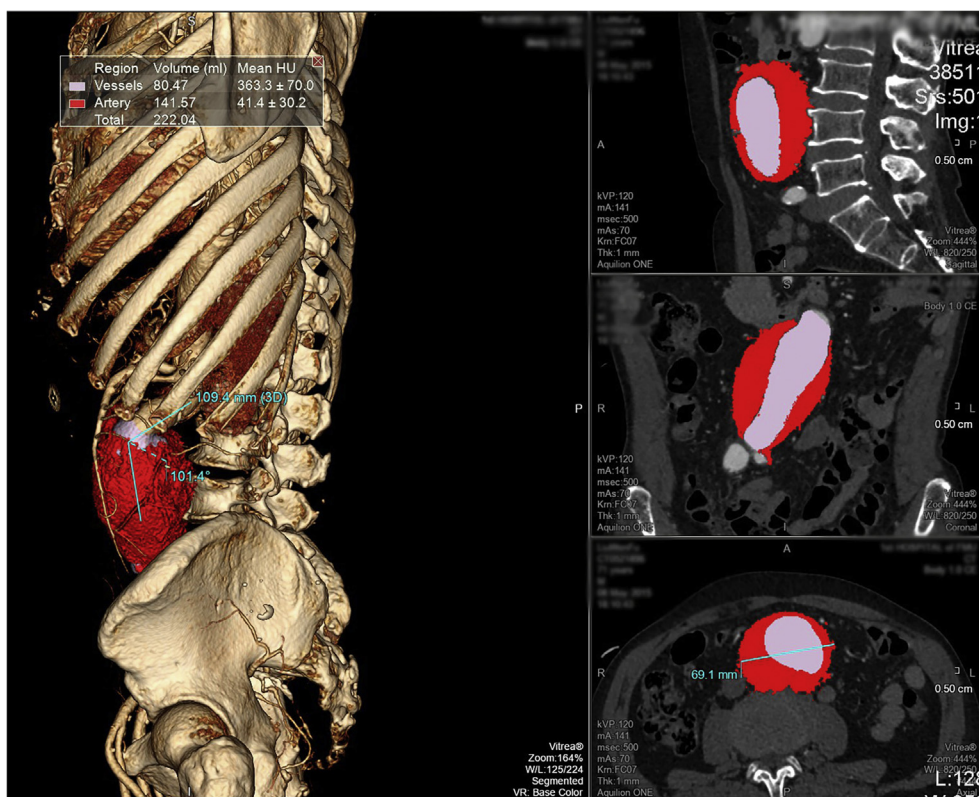


Fig. 1. Measurement of sac volume (SV) and mural thrombus volume (MTV).

Table 2  
Results of EII within follow-up time.

	12 months		Final		New EII	EII resolution		Total
	<sup>a</sup> EII	No EII	EII	No EII		Natural resolution	Re-intervention	
Group A	17 (25.8%)	49	15 (22.7%)	53	4	4	2	66
Group B	5 (8.6%)	53	4 (6.9%)	54	1	1	1	58
$\chi^2$	6.21	5.62	–	–	–	–	–	–
P value	0.013	0.018	–	–	–	–	–	–

<sup>a</sup> EII, type II endoleak.

Table 3  
Multivariate analysis of EII.

Variables	$\beta$	S.E.	Wald value	OR	95% CI	P
Male	20.45	134.9	0.011	–	–	0.91
Age >79, n	2.6	1.33	3.78	0.08	0.005–1.02	0.16
Current smoker	0.08	0.57	0.021	0.92	0.3–2.83	0.89
No embolization	1.74	0.78	4.99	5.72	1.24–26.39	0.026
<sup>a</sup> SV $\geq 128 \text{ cm}^3$	1.181	0.60	3.91	3.26	1.01–10.50	0.048
<sup>a</sup> MTV/SV <35%	20.27	2844.77	0.01	–	–	0.99
Patent IMA	1.32	0.83	2.50	0.27	0.05–1.34	0.11
Accessory RA	0.66	0.70	0.87	1.93	0.49–7.62	0.35
Pairs of Las $\geq 3$	2.78	42.4	0.12	0.34	0.09–6.32	0.86
Mono-lateral IA	0.30	0.64	0.22	1.35	0.39–4.67	0.64
Bilateral IA	1.51	1.11	1.84	0.22	0.03–1.96	0.18

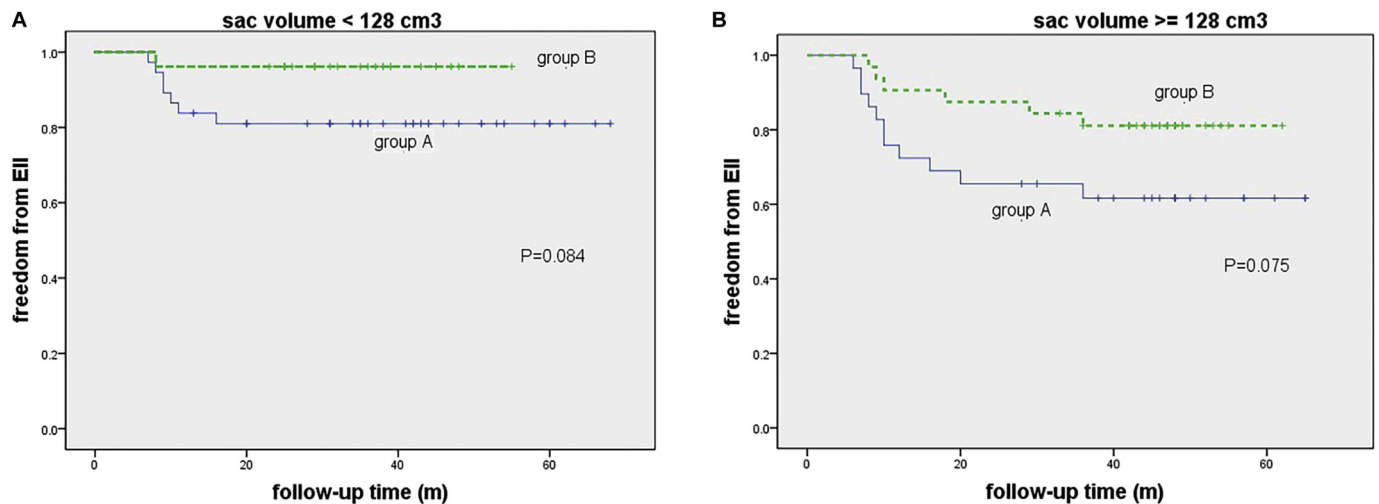
<sup>a</sup> SV: Sac volume; MTV: Mural thrombus volume; IMA: inferior mesenteric artery; LA: lumbar artery; RA: renal artery; IA: iliac aneurysm; OR, odds ratio; CI, confidence interval.

the sac embolization. <sup>9</sup> utilized fibrin glue injection with or without simultaneous deployment of the coils.<sup>3, 4</sup> used a sac volume-dependent dose of fibrin glue and coils.<sup>2</sup> used a mean of 12 coils for sac embolization. All the authors mentioned above confirmed the full sac thrombosis

and reduced the EII incidence regardless of the embolic agents. In our study, the thrombin or glue was not utilized simultaneously during the operation, and complete sac obliteration was confirmed by both aortography and sac angiogram, which was reconfirmed by the first CTA scan obtained within 7 days postoperatively. The result of this study supported the role of intraoperative sac embolization in lowering the incidence of EII at short-term follow-up time. But this advantage seemed to be weakened as follow-up time lengthened and different sac volumes were taken into serious consideration. The probable explanation is that the natural resolution and new appearance of EII is unpredictable in the long run, and large aneurysmal sac volumes influence the effectiveness of intraoperative sac embolization. Although informative, this report should be read with caution. This study was non-randomized, retrospective, and with a small cohort. We did not fully standardize the coiling protocol *per se*, and the number of coils placed inside the aneurysm sac was mainly determined according to whether the aneurysmal sac was visualized fluoroscopically. Our results could vary with different operators.

### Conclusions

The conclusions that we have drawn from this study are as follows. The performance of intraoperative sac coiling embolization in patients at



**Fig. 2.** (2a, 2b): 2a: Kaplan-Meier curve for freedom from EII in patients with sac volume <128 cm<sup>3</sup>; 2b: Kaplan-Meier curve for freedom from EII in patients with sac volume ≥128 cm<sup>3</sup>.

high-risk for EII could lower the incidence of EII at midterm follow-up. Large aneurysmal sac volume and no sac embolization are the independent risk factors associated with EII. The advantage of preventive sac embolization seemed to be weakened when the sac volumes were taken into consideration. Further randomized, prospective, controlled trials are needed to better understand the role of sac coiling embolization.

#### Funding

This study was supported by the Science & Technology Department of Fujian Province under Grant 2018Y0028; The funding sources were not involved in the study design, or in the collection, analysis, and interpretation of the data, in the writing of the report, or in the decision to submit the article for publication.

#### Author contributions

Conception and design of the study: Xiantao Li, Pingfan Guo; Acquisition of data: Xiantao Li, Yanyan Huang; Analysis and interpretation of data: Xiantao Li, Yanyan Huang, Pingfan Guo; Drafting of the manuscript: Xiantao Li; Revising the manuscript: Xiantao Li, Pingfan Guo.

#### Declaration of competing interest

The authors certify that there is no conflict of interest with any

financial organization regarding the material discussed in the manuscript.

#### References

1. Natrella M, Rapellino A, Navarretta F, et al. Embo-evar: a technique to prevent type II endoleak? A single-center experience. *Ann Vasc Surg.* 2017;44:119–127.
2. Fabre D, Fadel E, Brenot P, et al. Type II endoleak prevention with coil embolization during endovascular aneurysm repair in high-risk patients. *J Vasc Surg.* 2015;62:1–7.
3. Piazza M, Frigatti P, Scrivero P, et al. Role of aneurysm sac embolization during endovascular aneurysm repair in the prevention of type II endoleak-related complications. *J Vasc Surg.* 2013;57:934–941.
4. Piazza M, Squizzato F, Zavatta M, et al. Outcomes of endovascular aneurysm repair with contemporary volume-dependent sac embolization in patients at risk for type II endoleak. *J Vasc Surg.* 2016;63:32–38.
5. Abularrage CJ, Crawford RS, Conrad MF, et al. Preoperative variables predict persistent type 2 endoleak after endovascular aneurysm repair. *J Vasc Surg.* 2010;52:19–24.
6. Piazza M, Squizzato F, Miccoli T, et al. Definition of type II endoleak risk based on preoperative anatomical characteristics. *J Endovasc Ther.* 2017;24:566–572.
7. Beckerman WE, Tadros RO, Faries PL, et al. No major difference in outcomes for endovascular aneurysm repair stent grafts placed outside of instructions for use. *J Vasc Surg.* 2016;64:63–74.
8. Zanchetta M, Faresin F, Pedon L, et al. Intraoperative intrasac thrombin injection to prevent type II endoleak after endovascular abdominal aortic aneurysm repair. *J Endovasc Ther.* 2007;14:176–183.
9. Ronsivalle S, Faresin F, Franz F, et al. Aneurysm sac “thrombization” and stabilization in EVAR: a technique to reduce the risk of type II endoleak. *J Endovasc Ther.* 2010;17:517–524.