



Contents lists available at ScienceDirect

## International Journal of Surgery Case Reports

journal homepage: [www.casereports.com](http://www.casereports.com)

## A case report of bleeding from a duodenal varix: Rare cause of upper gastrointestinal bleeding

Vincent Khor<sup>a,b,\*</sup>, Yuen Soon<sup>b</sup>, Lwin Aung<sup>b</sup><sup>a</sup> MOH Holdings Singapore, 1 Maritime Square, #11-25 HarbourFront Centre, 099235, Singapore<sup>b</sup> Department of General Surgery, Ng Teng Fong General Hospital, National University Health System, 1 Jurong East Street 21, 609606, Singapore

## ARTICLE INFO

## Article history:

Received 4 May 2018

Accepted 25 June 2018

Available online 28 June 2018

## Keywords:

Case report

Upper gastrointestinal bleeding

Duodenal varix

## ABSTRACT

**INTRODUCTION:** Ectopic variceal bleeding is uncommon, accounts for 2–5% of variceal bleeding, of which 17% is in duodenum.**PRESENTATION OF CASE:** 62-year-old lady with newly diagnosed liver cirrhosis on admission, presented with severe upper gastrointestinal bleeding (UGIB), was ultimately diagnosed with bleeding duodenal varices with single-balloon enteroscopy, after multiple oesophagogastroduodenoscopies (OGDs) and CT scans which failed to identify the varices. She was treated successfully with duodenectomy.**DISCUSSION:** Endoscopy and CT angiography remain the diagnostic modalities of choice. However, diagnosis can be difficult as evidenced by three OGDs and two CTMAs yielding negative findings in this case. Endoscopic diagnosis is challenging and often delayed due to its rarity and unusual location.**CONCLUSION:** Ectopic variceal bleeding is a rare but important cause of UGIB. Diagnosis is challenging and management of this condition should take a multidisciplinary approach, involving experienced gastroenterologists, interventional radiologists and surgeons. Endoscopic ligation or sclerotherapy is the first-line of treatment.© 2018 The Authors. Published by Elsevier Ltd on behalf of IJS Publishing Group Ltd. This is an open access article under the CC BY-NC-ND license (<http://creativecommons.org/licenses/by-nc-nd/4.0/>).

## 1. Introduction

Ectopic bleeding varix is an uncommon but potentially life threatening cause of upper gastrointestinal bleeding. It accounts for 2–5% of variceal bleeding, of which 17% occurs in the duodenum [1]. Diagnosis can be difficult and often delayed due to lack of awareness and the unusual serosal or submucosal location of duodenal varices. It is important that the clinicians aware of ectopic variceal bleeding as a rare but important cause of UGIB. This is especially the case when patients present with profuse melena with deterioration, but conventional endoscopy and imaging failed to detect the source of bleeding. We report a rare case of UGIB caused by bleeding duodenal varix, following the SCARE guideline [2].

## 2. Case presentation

A 62-year old lady with underlying diabetes and hypertension, presented with melena, epigastric pain, tachycardia (pulse rate 118 bpm) and hypotension (90/50 mmHg). Physical examina-

tion did not reveal any stigmata of chronic liver disease. Following insertion of a nasogastric tube, gastric aspirates were noted to be coffee brown in colour. Initial blood investigations showed severe anaemia (Hb 6.2 g/dL), elevated urea (21.9 mmol/L) and compensated metabolic acidosis (pH 7.346; bicarbonate 14.3 mmol/L; base excess –10.3 mmol/L; lactate level 8.9 mmol/L). Oesophagogastroduodenoscopy was performed which showed blood clots in the stomach and a small Forrest 1b ulcer at the D1 duodenum. Haemostasis achieved with adrenaline injection and clips. However, despite adequate resuscitation after 2 units of packed cells transfusion, patient remained tachycardic and the post-transfusion haemoglobin level remained low (6 g/dL). Repeat endoscopy showed no active bleeding from the previously noted D1 ulcer.

On post-admission day 1, the patient continued to deteriorate. CTMA did not show evidence of active GI bleeding. However, CT did show a nodular liver suggestive of liver cirrhosis along with moderate ascites and mild bilateral pleural effusions. He was not known to have liver cirrhosis previously and at that point of time she was Child-Pugh Class B with normal liver enzymes and coagulation profile. Subsequently, she was intubated due to severe metabolic acidosis with impending respiratory failure. On post-admission day 2, she remained critically ill but stable. Her haemoglobin level was between 8.7 g/dL to 9.9 g/dL. Up to this point, she had been transfused a total of 10 units of packed red blood cells.

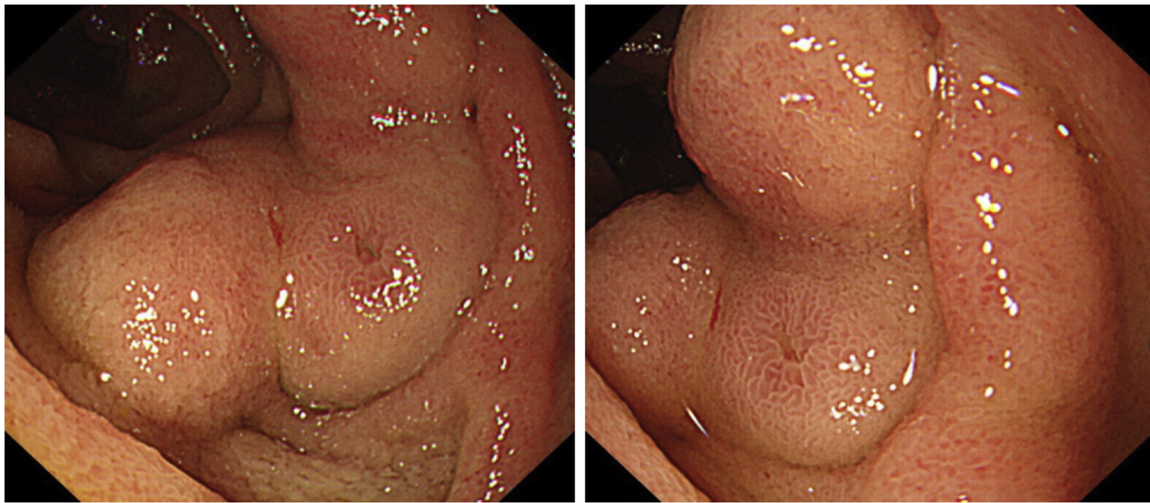
**Abbreviations:** UGIB, upper gastrointestinal bleeding; OGD, oesophagogastroduodenoscopy; CTMA, CT mesenteric angiogram; ECV, ectopic variceal.

\* Corresponding author at: MOH Holdings Singapore, 1 Maritime Square, #11-25 HarbourFront Centre, 099235, Singapore.

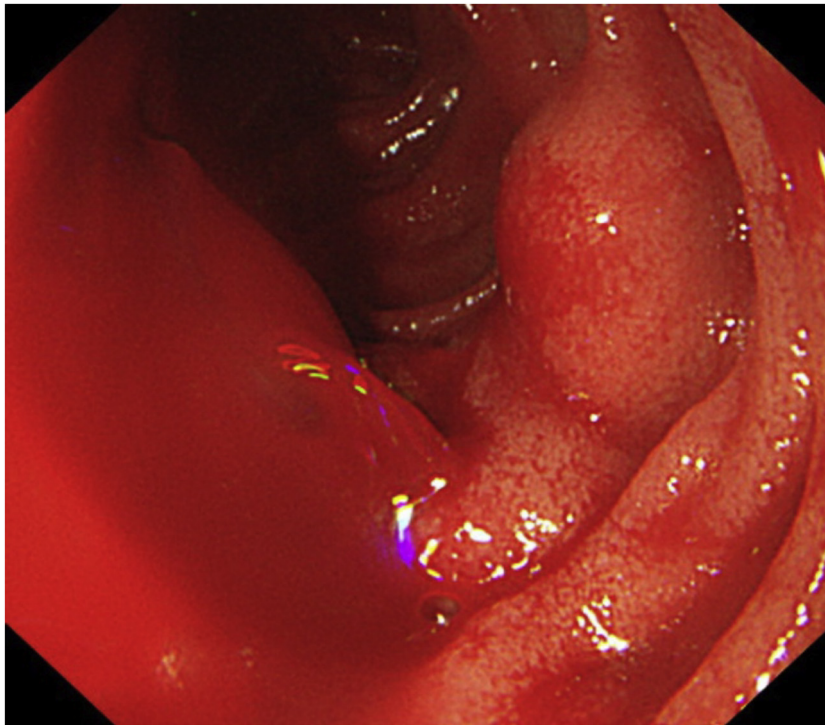
E-mail address: [vincent.khor@mohh.com.sg](mailto:vincent.khor@mohh.com.sg) (V. Khor).

<https://doi.org/10.1016/j.ijscr.2018.06.031>

2210-2612/© 2018 The Authors. Published by Elsevier Ltd on behalf of IJS Publishing Group Ltd. This is an open access article under the CC BY-NC-ND license (<http://creativecommons.org/licenses/by-nc-nd/4.0/>).



**Fig. 1.** A nodular lesion in distal duodenum/proximal jejunum with dilated veins.



**Fig. 2.** bleeding from the nodular lesion during endoscopy.

On post-admission day 3, she passed a large amount of melena accompanied by a significant drop in haemoglobin level (8.7 g/dL–6.8 g/dL). A third OGD was performed. There was no endoscopic evidence of oesophageal or gastric varices. The duodenal ulcer and clips were no longer visible and no blood was seen from oesophagus till D2. A repeat CTMA did not reveal any significant bleeding point. Decision was made to perform single balloon enteroscopy which showed blood in the small bowel and an area of nodular mucosal abnormality along the distal duodenum/proximal jejunum, which appeared like a gastrointestinal stromal tumour (GIST) or vascular malformation (Fig. 1). Torrential bleeding from the lesion occurred during endoscopy and patient deteriorated rapidly (Fig. 2). She became haemodynamically unstable. Adrenaline injection and endoscopic clipping were not successful to achieve haemostasis. Indian ink was injected just

proximal to the lesion at three points circumferentially to assist in identifying the location of lesion on laparotomy later. Enteroscopy was advanced further to position the balloon at the level of bleeding lesion and inflated to exert tamponade on bleeding point. Patient was rushed to operation theatre immediately for emergency laparotomy. There was old blood found within the grossly distended small and large bowels on laparotomy. Tattoo was seen at D2/D3 junction with hugely dilated mesenteric veins supplying D2/D3 segment. Dilated veins were clamped to control bleeding. Duodenum was kocherized, mobilized and a segment of duodenum was transected from just distal to the ampulla of Vater to 5 cm distal to the tattooed area. Side-to-side duodeno-jejunostomy was performed at first part of duodenum. The rest of small bowel and colon were examined carefully and no tumour was found. Patient recovered well from surgery and she was discharged.

The resected duodenum was sent for histopathological examination which reported the lesion as a submucosal venous malformation associated with focal mucosal ulceration. Microscopically, the small intestinal wall showed focal mucosal ulceration associated with several markedly dilated veins in the underlying submucosa, which partly protrude into the muscularis propria. The walls of the veins had discernible smooth muscle and showed some areas of eccentric fibrous thickening. She was discharged well and follow-up by the gastroenterologist.

### 3. Discussion

UGIB is one of the most common medical emergencies encountered in our day-to-day practice. The overall incidence of UGIB in the UK is 103/10,000 adults per year, with an overall mortality of 14% [3]. UGIB can be broadly classified into variceal bleeding and non-variceal bleeding. A recent audit in the UK showed a rise in the incidence of variceal bleeding, mostly contributed by the increased alcohol abuse in the last 10 years [4]. Variceal bleeding usually occurs at the gastroesophageal junction. Bleeding which occurs outside the gastroesophageal junction is known as ectopic variceal (ECV) bleeding. Our report describes an unusual presentation of UGIB arising from ECV located in between the second and third part of duodenum.

Duodenal varices were first described by Alberti in 1931 [5] and visualized endoscopically by Kunisaki et al. in 1973 [6]. Duodenal varices frequently occur as a result of liver cirrhosis and portal vein hypertension. They are commonly found at the duodenal bulb with the frequency decreasing distally in the gastrointestinal tract [7,8]. From an anatomical perspective, duodenal varix usually consists of a single vessel with associated afferent and efferent vessels forming a retroperitoneal portosystemic shunt [9]. The afferent/portal venous feeder usually arises from the pancreaticoduodenal veins (superior or inferior), cystic branches of superior mesenteric veins, pyloric vein, and gastroduodenal vein. The efferent/systemic drainage includes gonadal vein (mostly the right), capsular renal veins, and rarely paravertebral or innominate retroperitoneal veins that ultimately drain into the inferior vena cava [10]. These communications between the afferent and efferent vessels are called the vein of Retzius [11]. In cirrhotic patients, it can drain via the subcostal and ascending lumbar vein into azygous system and ultimately into the SVC [10].

Duodenal variceal bleeding can present with haematochezia, haematemesis or profuse melena. After adequate resuscitation, OGD is mandatory for both diagnostic and therapeutic purposes in patient presented with UGIB. Endoscopic diagnosis of duodenal varices can be quite difficult due to their serosal and submucosal location [9,12]. Furthermore, conventional upper endoscopy usually reaches only the second part of duodenum, and fails to detect varices in the distal duodenum. Push enteroscopy is required to look for the source of bleeding distal to the proximal duodenum. Even if varices are found, the pathology may not be recognized due to its rarity. The varix may be mistaken for other pathology such as duodenal tumour [13], ulcers and vascular malformations. CT angiography is another useful diagnostic modality to detect duodenal varices [11]. In recent reports, multislices helical CT scans with multiplanar reconstruction, in addition to endoscopy, aid in the diagnosis and management of duodenal varices [14,15]. In our case, we were misled by the initial finding of the D1 duodenal ulcer. We initially thought that the D1 ulcer was the culprit of her UGIB and we did not take the additional efforts during the subsequent two endoscopies to assess the small bowel distal to D2. The second CT would be beneficial if CT portography was performed. Capsule endoscopy which allows visualization of small intestine to detect small intestinal bleeding is of little value in acute setting.

There are currently no guidelines related to the management of this relatively uncommon problem and the available literature consists of case reports with few literature reviews. Therapeutic options can be classified into [A] **endoscopic** (banding, ligation or sclerotherapy) [B] **interventional radiology** (transjugular intrahepatic portosystemic shunt, percutaneous transhepatic embolization or balloon occluded retrograde transvenous obliteration) or [C] **surgery** (variceal ligation, duodenectomy, shunt surgery), depending on the severity of the condition, availability of the technology and expertise. Endoscopic ligation or injection sclerotherapy with cyanoacrylate is a useful first-line therapy [16–18]. However, caution must be exercised when using the cyanoacrylate injection as it can lead to complication such as migration to lungs (causing pulmonary embolism) [19], abdomen and pelvis [20]. Endoscopic haemostasis using mini loop ligation with detachable nylon loop [21], and endoscopic ultrasonography (EUS)-guided clipping [22], embolization coiling [23,24] were attempted, with good outcomes even in acute emergency setting. If the bleeding is not controlled by endoscopic therapy, the patient can either undergo interventional radiological treatment or emergency surgery, depending on the availability of expertise and status of the patient. In our case, surgery was an appropriate measure as the varix started to bleed profusely during the enteroscopy and we failed to endoscopically achieve haemostasis.

When a patient presents with profuse melena without haematemesis and no identifiable bleeding source can be found with conventional endoscopies (OGD and colonoscopy), the possibility of bleeding ectopic varices should be considered, especially in newly diagnosed cirrhotic patients with no evidence of oesophageal/gastric varices. Management requires a multidisciplinary approach involving the experienced endoscopists, interventional radiologist and surgeons. Frequent surveillance is important to prevent future massive bleeding.

### Conflict of interest

No conflict of interest.

### Source of funding

No funding.

### Ethical approval

Ethical approval is not needed for case report. Ethical approval is exempted from my institution for case report submission.

### Consent

Consent has been taken from the patient and family members are aware of this article submission.

### Authors contribution

Dr Vincent Khor – article preparation and literature review.  
Mr Aung Lwin and Mr Soon Yuen – Operating surgeons. They both helped to proof read the submitted manuscript.

### Registration of research studies

N/A.

### Guarantor

Dr Vincent Khor.



## References

- [1] I.D. Norton, J.C. Andrews, P.S. Kamath, Management of ectopic varices, *Hepatology* 28 (1998) 1154–1158.
- [2] R.A. Agha, A.J. Fowler, A. Saetta, I. Barai, S. Rajmohan, D.P. Orgill, for the SCARE Group, The SCARE Statement: consensus-based surgical case report guidelines, *Int. J. Surg.* (2016) 180–186.
- [3] T.A. Rockall, R.F.A. Logan, H.B. Devlin, T.C. Northfield, Incidence of and mortality from acute upper gastrointestinal haemorrhage in the United Kingdom, *BMJ* 311 (6999) (1995) 222–226, <http://dx.doi.org/10.1136/bmj.311.6999.222>.
- [4] S.A. Hearnshaw, R.F.A. Logan, D. Lowe, S.P.L. Travis, M.F. Murphy, K.R. Palmer, Acute upper gastrointestinal bleeding in the UK: patient characteristics, diagnoses and outcomes in the 2007 UK audit, *Gut* 60 (10) (2011) 1327–1335, <http://dx.doi.org/10.1136/gut.2010.228437>.
- [5] W. Alberti, Überden roentgenologischen nachweis von varizen in buolbus duodeni, *Fortschro Geb Koentgenstr* 43 (1931) 60–65.
- [6] T. Kunisaki, N. Someya, Y. Shimokava, Varices in the distal duodenum seen with a fiberduodenoscope, *Endoscopy* 5 (1973) 101–104.
- [7] T. Tanaka, K. Kato, T. Taniguchi, D. Takagi, N. Takeyama, Y. Kitazawa, A case of ruptured duodenal varices and review of the literature, *Jpn. J. Surg.* 18 (5) (1988) 595–600, <http://dx.doi.org/10.1007/bf02471496>.
- [8] R. Amin, R. Alexis, J. Korzis, Fatal ruptured duodenal varix: a case report and review of literature, *Am. J. Gastroenterol.* 80 (1) (1985) 13–18.
- [9] M. Hashizume, K. Tanoue, M. Ohta, K. Ueno, K. Sugimachi, M. Kashiwagi, et al., Vascular anatomy of duodenal varices: angiographic and histopathological assessments, *Am. J. Gastroenterol.* 88 (11) (1993) 1942–1945.
- [10] C.A. Philips, A. Arora, R. Shetty, V. Kasana, A comprehensive review of portosystemic collaterals in cirrhosis: historical aspects, anatomy, and classifications, *Int. J. Hepatol.* 2016 (2016) 6170243, <http://dx.doi.org/10.1155/2016/6170243>.
- [11] K. Ibukuro, T. Tsukiyama, K. Mori, Y. Inoue, Veins of Retzius at CT during arterial portography: anatomy and clinical importance, *Radiology* 209 (3) (1998) 793–800, <http://dx.doi.org/10.1148/radiology.209.3.9844676>.
- [12] M. Sukigara, I. Koyama, T. Komazaki, T. Matsuda, T. Ishii, R. Omoto, Bleeding varices located in the second portion of the duodenum, *Jpn. J. Surg.* 17 (2) (1987) 130–135, <http://dx.doi.org/10.1007/bf02470653>.
- [13] C.V. DeShazo, R.P. Belin, J.F. Lloyd, A.I. Walder, Varix of the duodenum simulating duodenal tumor, *Minn. Med.* 48 (11) (1965) 1501–1503.
- [14] S. Yoshida, H. Watabe, M. Akahane, Y. Kyoden, H. Ishikawa, A. Yamada, et al., Usefulness of multi-detector helical CT with multiplanar reconstruction for depicting the duodenal varices with multiple collateral shunt vessels, *Hepatol. Int.* 4 (4) (2010) 775–778, <http://dx.doi.org/10.1007/s12072-010-9191-5>.
- [15] D. Weishaupt, T. Pfammatter, P.R. Hilfiker, U. Wolfensberger, B. Marincek, Detecting bleeding Duodenal varices with multislice helical CT, *AJR Am. J. Roentgenol.* 178 (2002) 399–401.
- [16] A.W. Barbish, M.N. Ehrinpreis, Successful endoscopic injection sclerotherapy of a bleeding duodenal varix, *Am. J. Gastroenterol.* 88 (1) (1993) 90–92.
- [17] H.Y. Kang, W.K. Lee, Y.H. Kim, B.W. Kwon, M.S. Kang, S.B. Kim, et al., Ruptured duodenal varices arising from the main portal vein successfully treated with endoscopic injection sclerotherapy: a case report, *Korean J. Hepatol.* 17 (2) (2011) 152–156, <http://dx.doi.org/10.3350/kjhep.2011.17.2.152>.
- [18] A. Malik, N. Junglee, A. Khan, J. Sutton, J. Gasem, W. Ahmed, Duodenal varices successfully treated with cyanoacrylate injection therapy, *BMJ Case Rep.* 2011 (2011), <http://dx.doi.org/10.1136/bcr.02.2011.3913>.
- [19] J.R.Y. Chew, A. Balan, W. Griffiths, J. Herre, Delayed onset pulmonary glue emboli in a ventilated patient: a rare complication following endoscopic cyanoacrylate injection for gastric variceal haemorrhage, *BMJ Case Rep.* 2014 (2014), <http://dx.doi.org/10.1136/bcr-2014-206461>.
- [20] S. Bhagani, C. Winters, S. Moreea, Duodenal variceal bleed: an unusual cause of upper gastrointestinal bleed and a difficult diagnosis to make, *BMJ Case Rep.* 2017 (2017), <http://dx.doi.org/10.1136/bcr-2016-218669>.
- [21] G. Ghidirim, I. Mishin, A. Dolghii, G. Zastavinsky, Ruptured duodenal varices successfully treated by mini-loop ligation: report of a case, *Chirurgia (Bucharest, Romania)* 104 (5) (2009) 625–629.
- [22] I. Lienhart, A. Lesne, E. Couchonnal, J. Rivory, L. Sosa-Valencia, T. Ponchon, et al., Massive duodenal variceal bleed: endoscopic ultrasonography of ruptured varix and successful endoscopic clipping treatment, *Endoscopy* 48 (Suppl. 1) (2016), UCTN:E80-1.
- [23] J. Kinzel, N. Pichetshote, S. Dredar, H. Aslanian, A. Nagar, Bleeding from a duodenal varix: a unique case of variceal hemostasis achieved using EUS-guided placement of an embolization coil and cyanoacrylate, *J. Clin. Gastroenterol.* 48 (4) (2014) 362–364.
- [24] R.J. Mukkada, M.J. Chooracken, R. Antony, P. Augustine, EUS-guided coiling for bleeding duodenal collateral vessel, *Gastrointest. Endosc.* 84 (6) (2016) 1057–1058.

## Open Access

This article is published Open Access at [sciedirect.com](http://sciedirect.com). It is distributed under the [IJSCR Supplemental terms and conditions](#), which permits unrestricted non commercial use, distribution, and reproduction in any medium, provided the original authors and source are credited.