

*Images in Nephrology*  
(Section Editor: G. H. Neild)

## Intravascular large B-cell lymphoma diagnosed at renal biopsy

Manivarma Kamalanathan<sup>1</sup>, David Wright<sup>2</sup>, Rosalynd Johnston<sup>3</sup>, Andrew Webb<sup>4</sup> and Edward Kingdon<sup>1</sup>

<sup>1</sup>Sussex Kidney Unit, Royal Sussex County Hospital, Brighton, Sussex, UK, <sup>2</sup>Department of Histopathology, Royal Sussex County Hospital, Brighton, Sussex, UK, <sup>3</sup>Department of Haematology, Royal Sussex County Hospital, Brighton, Sussex, UK and <sup>4</sup>Department of Oncology, Royal Sussex County Hospital, Brighton, Sussex, UK

Correspondence and offprint requests to: Manivarma Kamalanathan; E-mail: mkamalan@doctors.org.uk

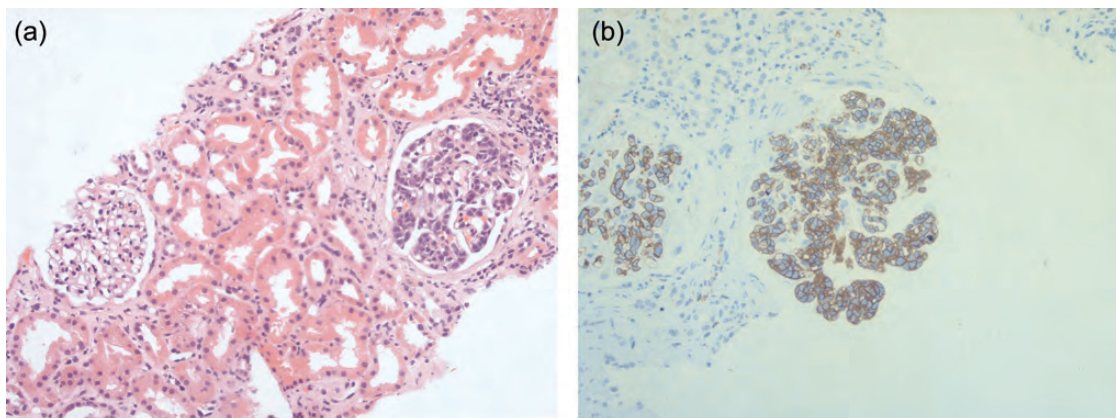
A 77-year-old woman was referred with renal impairment—serum creatinine 230 mmol/L (2.61 mg/dL) and proteinuria 2.14 g/day. The past medical history included hypertension, sicca symptoms and osteoarthritis. Her medications included amlodipine 5 mg od, omeprazole 20 mg od and prednisolone 10 mg od. Systematic enquiry revealed lethargy and 6 kg weight loss over 6 months. Examination was unremarkable. Laboratory investigations revealed normocytic normochromic anaemia with reactive thrombocytosis. Serum lactate dehydrogenase was elevated. Bone biochemistry, liver function tests, serum protein electrophoresis, immunoglobulins, anti-nuclear antibodies, anti-neutrophil cytoplasmic antibodies and complements were all negative or normal. Ultrasound showed normal-sized unobstructed kidneys of normal echogenicity.

A renal biopsy revealed an almost exclusively intraglomerular infiltrate of enlarged atypical CD20 positive B-lymphocytes filling the capillary lumens of nearly 50% of all glomeruli seen on the biopsy indicating large B-cell lymphoma of non-germinal centre immunophenotype (Figure 1a and 1b). No complement, immunoglobulin or amyloid deposits were present. Electron

microscopy of a single glomerulus did not reveal any abnormal lymphocyte, but did reveal a segmental sclerosing lesion together with widespread basement membrane thickening and wrinkling. There were no electron dense deposits.

Staging computed tomography (CT) including brain was normal and positron emission tomography scanning showed diffuse marrow activity but no abnormal renal signal. The clinical diagnosis was intravascular large B-cell lymphoma. Six cycles of standard rituximab plus multiagent chemotherapy were administered successfully. The patient was alive 4 years after completion of chemotherapy with independent renal function and modest proteinuria (serum creatinine 1.56 mg/dL, proteinuria 38 mg/day). The response CT showed continued normality.

Intravascular large B-cell lymphoma is uncommon and is usually associated with a poor prognosis [1]. Isolated glomerular infiltration is extremely rare [2] and the characteristic pathologic finding is localization of lymphoma cells within the lumina of glomerular capillaries [3]. We describe a good outcome after the conventional treatment of intravascular large B-cell lymphoma



**Fig. 1.** (a) Light microscopy showing infiltrated and non-infiltrated adjacent glomeruli. (b) Anti-CD20 antibodies reveal large atypical B-cells restricted to glomerular capillaries.

identified during the investigation of proteinuric kidney disease.

**References**

1. Kameoka Y, Takahashi N, Komatsuda A et al. Kidney-limited intravascular large B-cell lymphoma: a distinct variant of IVLBCL? *Int J Hematol* 2009; 89: 533–537

2. Gisselbrecht C. Use of rituximab in diffuse large B-cell lymphoma in the salvage setting. *Br J Haematol* 2008; 143: 607–621

3. Bai X, Li X, Wan L et al. Intravascular large B-cell lymphoma of the kidney: A case report. *Diagn Pathol* 2011; 6: 86

*Received for publication: 8.9.12; Accepted in revised form: 9.10.12*