

Decalcified choroidal osteoma found in the retina

Tadanobu Yoshikawa
Kanji Takahashi

Department of Ophthalmology, Kansai
Medical University, Hirakata Hospital,
Osaka, Japan

Abstract: Choroidal osteoma is a benign tumor of the choroid. Herein, we report a rare case of decalcified choroidal osteoma found in the retina. A 27-year-old woman presented with visual loss. Her best-corrected visual acuity was 20/50 OS. Ophthalmoscopy of the left eye revealed a yellow-white calcified region accompanied by a decalcified region of four disc diameters in size. After 6 years, spectral-domain optical coherence tomography showed a tumor projected strongly upwards from the choroid and partially through the retina with serous retinal detachment, with both a lamellar appearance and mound-like area. The calcified region became more contractive than was observed on the first visit. Conversely, the decalcified region was wider than was observed on the first visit. Her best-corrected visual acuity was 20/400 OS. Choroidal osteoma was worsened by progression of decalcification. The decalcified choroidal osteoma resulted in poor visual acuity, and projected strongly upward from the choroid and into the retina.

Keywords: osteoma, decalcification, choroidal osteoma

Introduction

Choroidal osteoma is a rare benign intraocular tumor characterized by heterotopic bone of the choroid.¹ It is often found in healthy young females and is unilateral in approximately 80% of cases.² Choroidal osteoma is usually located in the peripapillary region, which is yellow-gray or yellow-orange in appearance. The calcified region is clinically recognized as yellow-orange as a consequence of intact retinal pigment epithelium overlying the tumor. The decalcified region is recognized as a yellow-gray area, and occurs as a result of thinning and depigmentation of the overlying retinal pigment epithelium. It progressively grows and decalcifies. The decalcified subfoveal tumor causes poor visual acuity because the decalcified choroidal osteoma leads to thinning of the outer retinal layers and loss of photoreceptor layers. This is complicated by choroidal neovascularization, subretinal hemorrhage, and serous retinal detachment. Reports suggest that choroidal osteoma leads to a poor visual acuity of 20/200 or worse after 10 years in 56%–58% of individuals.^{2,3} Shields et al examined 22 cases of choroidal osteoma, and reported that decalcified subfoveal choroidal osteoma was associated with poor visual acuity.⁴ Thus, the finding of decalcification is important for the clinical prognosis.

There have been some reports in recent years of the use of spectral-domain optical coherence tomography (SD-OCT) in choroidal osteoma. However, no reports of high protrusion of choroidal osteoma into the retina were noted. In this study, we use SD-OCT to report that decalcified choroidal osteoma can break through into the retina.

Correspondence: Tadanobu Yoshikawa
Kansai Medical University, Department
of Ophthalmology Shinmachi, Hirakata,
Osaka, Japan
Tel +81 072 804 0101
Fax +81 6 6993 2222
Email yoshikat@takii.kmu.ac.jp

Case report

A 27-year-old previously healthy woman visited another hospital presenting with visual loss, and was subsequently diagnosed with choroidal osteoma. She was seen in our hospital in January 2006. Her best-corrected visual acuity was 20/20 OD and 20/50 OS and her manifest refraction was -0.5 diopters OD and -0.5 diopters OS. Intraocular pressure was 19 mmHg OD and 17 mmHg OS. Slit-lamp examination of the anterior segment in both eyes was normal. Ophthalmoscopy and fundus photograph examination revealed yellow-white lesions of approximately 4 disc diameters in size in OS (Figure 1A). There was a calcification region in the macula and a decalcified lesion in the lower macula area in OS. Fluorescein angiography demonstrated tumor vessels, called “spider” vessels, on the tumor surface, which showed late-phase hyperfluorescence. The patient was diagnosed with choroidal osteoma with decalcification, and she was followed without further treatment. Three years later, choroidal neovascularization appeared, and her best-corrected visual acuity was 20/100 OS.

In 2012, SD-OCT (Spectralis, Heidelberg Engineering, Heidelberg, Germany) revealed a layered hyper-reflective pattern, which was lamellar in appearance,⁵ and had a hyper-reflective mass pattern forming a mound-like area (Figure 2).⁵ Decalcified regions of the choroidal osteoma were raised and partially spread into the retina causing serous retinal detachment (Figure 2). The maximal diameter and thickness of the tumor, as derived from SD-OCT, was 7591 μm and 1688 μm , respectively. Ophthalmoscopy and fundus photograph examination revealed yellow-white lesions of approximately three disc diameters in size in OS, and this calcified region was more contractive than those found during the first examination (Figure 1). Conversely, the decalcified region was wider than observed in the first visit. Her best-corrected visual acuity was 20/400 in OS (Figure 1).

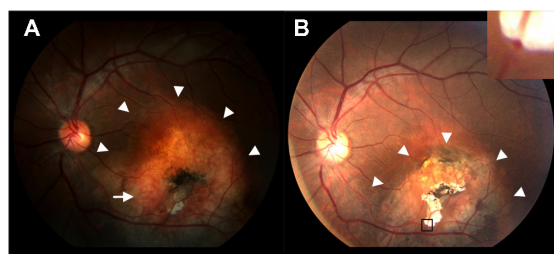


Figure 1 Fundus photograph of the left eye in (A) 2006 and (B) 2012. (A) Fundus photographs showing yellow-white calcified choroidal osteoma (arrowheads) of approximately four disc diameters in size, accompanied by a white decalcified region in the center of the tumor. There are tumor vessels (arrows), designated spider vessels, around the decalcified region. (B) The calcified regions (arrowheads) are obviously smaller and the decalcified region is wider than that observed in 2006.

Note: The retinal vessels are compressed due to the decalcified choroidal osteoma (square box).

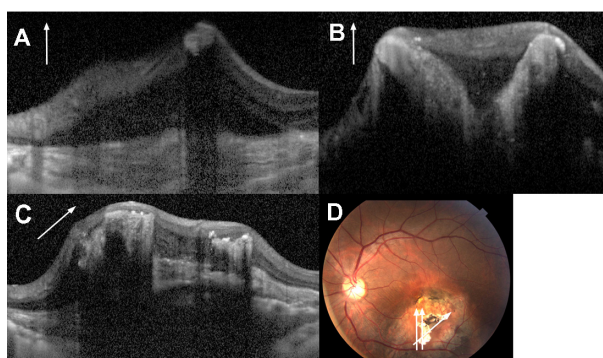


Figure 2 Spectral-domain optical coherence tomography scans of the left eye. (A) Longitudinal scan of the tumor. The round hyper-reflective mass accompanied by serous retinal detachment and disappearing posterior optical shadowing projected strongly upward from the choroid and partially broke through into the retina. Note the lamellar reflective pattern in the subretina and the disorganized structure of the retina with loss of inner and outer retinal layers. (B) Longitudinal scan of the tumor. There is a curved hyper-reflective mass similar to the finding in (A). (C) Skewed scan of the tumor. The raised hyper-reflective mass, a mound-like area, is observed in decalcified regions. (D) Fundus photograph for scan marking.

Discussion

Some have reported raised choroidal osteoma by OCT, but not severe protrusion.^{4,5} Our case demonstrated that decalcified choroidal osteoma strongly projected and partially broke through the retina and could be observed with SD-OCT. We found that SD-OCT measured tumor thickness, and diameters were larger than previously reported by Freton et al.⁶ They reported that the mean basal diameter of choroidal osteoma was 5.2 mm using fundus photographs and 6.4 mm using ultrasound images. The mean tumor thickness was 1.2 mm. In our report, tumor diameters and thickness were 7591 μm and 1688 μm , respectively. The tumor thickness observed in our studies was 1.4 times larger than previously reported.⁶

The choroidal osteoma was located between the choriocapillaris and outer choroidal tissue. The pathological tissue of the choroidal osteoma shows that the choroid was replaced by mature bone that contained bone marrow spaces with connective tissue and vessels, forming spongy bone structures. Navajas et al used SD-OCT to observe a calcified region, which histopathologically resembled a spongy bone structure.⁵ In our case, SD-OCT revealed a lamellar appearance and mound-like area in the decalcified region. Similar SD-OCT findings of these conditions were also reported by Navajas et al.⁵ They hypothesized that lamellar reflective patterns may correspond to sclera, and mound-like areas may correspond to tumor regions in which the spongy organization was lost, secondary to partial decalcification. We found similar results with our SD-OCT measurements.⁵

In the current report, the calcified region narrowed over a period of 6 years as observed from color photographs. Expansion of the decalcified region accompanied by coagulation of the calcium resulted from calcium migration. The calcium aggregates formed as a result of the migration of calcium from the decalcified osteoma. This lesion is composed of continuous tissue from decalcified osteoma. The agglomerated and decalcified region grew forward into the retina and partially broke through the retina. This tumor could, in the future, reach into the vitreous cavity.

In conclusion, although choroidal osteoma is a benign tumor, it may strongly project upward from the choroid and disorganize the retina, with loss of inner and outer retinal layers once the tumor is decalcified. We report a rare case of decalcified choroidal osteoma breaking through into the retina during long-term patient follow-up.

Disclosure

The authors report no conflicts of interest.

References

1. Shields CL, Shields JA, Augsburger JJ. Choroidal osteoma. *Surv Ophthalmol*. 1988;33:17–27.
2. Shields CL, Sun H, Demirci H, Shields JA. Factors predictive of tumor growth, tumor decalcification, choroidal neovascularization, and visual outcome in 74 eyes with choroidal osteoma. *Arch Ophthalmol*. 2005;123:1658–1666.
3. Aylward GW, Chang TS, Pautler SE, Gass JD. A long term follow-up of choroidal osteoma. *Arch Ophthalmol*. 2000;116:1337–1341.
4. Shields CL, Perez B, Materin MA, Mehta S, Shields JA. Optical coherence tomography of choroidal osteoma in 22 cases. *Ophthalmology*. 2007;114:53–58.
5. Navajas EV, Costa RA, Calucci D, Hammoudi DS, Simpson ER, Altomare F. Multimodal fundus imaging in choroidal osteoma. *Am J Ophthalmol*. 2012;152:890–895.
6. Freton A, Finger PT. Spectral domain-optical coherence tomography analysis of choroidal osteoma. *Br J Ophthalmol*. 2012;96:224–228.

Clinical Ophthalmology

Publish your work in this journal

Clinical Ophthalmology is an international, peer-reviewed journal covering all subspecialties within ophthalmology. Key topics include: Optometry; Visual science; Pharmacology and drug therapy in eye diseases; Basic Sciences; Primary and Secondary eye care; Patient Safety and Quality of Care Improvements. This journal is indexed on

Submit your manuscript here: <http://www.dovepress.com/clinical-ophthalmology-journal>

Dovepress

PubMed Central and CAS, and is the official journal of The Society of Clinical Ophthalmology (SCO). The manuscript management system is completely online and includes a very quick and fair peer-review system, which is all easy to use. Visit <http://www.dovepress.com/testimonials.php> to read real quotes from published authors.