

Surgical Microtia Reconstruction in Hemifacial Microsomia Patients: Current State and Future Directions

Gabriel Bouhadana, MD*
 Jordan Gornitsky, MD*
 Eli Saleh, MD, MSc*
 Daniel E. Borsuk, MD, MBA,
 FRCSC*
 Sabrina Cugno, MD, MSc,
 FRCSC*†

Background: Hemifacial microsomia (HFM) is one of the most common congenital craniofacial disorders. Among many other features, microtia is present in the large majority of these patients. However, mainly due to the unilateral hypoplastic anatomy, microtia reconstruction among this patient population remains a reconstructive challenge for plastic surgeons. Given that no clear standards exist, an evidence-based synthesis of the literature was devised.

Methods: A systematic search of Pubmed, Medline, and Embase was carried out, in accordance with the PRISMA guidelines. Studies discussing surgical microtia reconstruction for HFM patients were retained. Qualitative data regarding study design, challenges addressed, specific recommendations, and their respective strengths/limitations were extracted from each. Retrieved recommendations were consolidated and assigned a level of evidence grade.

Results: Although only 11 studies were included in this review, these provided 22 main recommendations regarding the eight HFM-specific challenges identified, which were of either grade C (n = 5) or D (n = 17). Included studies addressed construct location (n = 7), the low hairline (n = 6), soft tissue construct coverage (n = 6), earlobe reconstruction (n = 6), construct projection (n = 5), anomalies of the relevant neurovascular systems (n = 2), retroauricular construct coverage (n = 2), and sizing of the construct (n = 2).

Conclusions: Given the many persisting reconstructive challenges regarding surgical microtia reconstruction for HFM patients, the authors present a comprehensive and evidence-based consolidation of recommendations specific to these challenges. The authors hope this systematic review can appropriately guide plastic surgeons and will ultimately improve care for this patient population. (*Plast Reconstr Surg Glob Open* 2022;10:e4486; doi: [10.1097/GOX.0000000000004486](https://doi.org/10.1097/GOX.0000000000004486); Published online 24 August 2022.)

INTRODUCTION

Second to only cleft lip and palate, hemifacial microsomia (HFM), also referred to as craniofacial microsomia,¹ is one of the most common congenital craniofacial anomalies.^{2,3} Now recognized as a spectrum, HFM mainly affects the derivatives of the first and second branchial arches in a unilateral manner, primarily manifesting through the orbit, mandible, auricle, facial nerve, and/or soft tissue.³

In fact, it has been posited that microtia is in itself an iso-type of HFM.⁴ Although many technical advancements have been made over the years, microtia reconstruction remains a challenge among this patient population.

From the *Division of Plastic and Reconstructive Surgery, Université de Montréal, Montreal, Quebec, Canada, †Division of Plastic and Reconstructive Surgery, McGill University, Montreal, Quebec, Canada. Received for publication May 17, 2022; accepted June 27, 2022.

Copyright © 2022 The Authors. Published by Wolters Kluwer Health, Inc. on behalf of The American Society of Plastic Surgeons. This is an open-access article distributed under the terms of the [Creative Commons Attribution-Non Commercial-No Derivatives License 4.0 \(CCBY-NC-ND\)](https://creativecommons.org/licenses/by-nc-nd/4.0/), where it is permissible to download and share the work provided it is properly cited. The work cannot be changed in any way or used commercially without permission from the journal.

DOI: [10.1097/GOX.0000000000004486](https://doi.org/10.1097/GOX.0000000000004486)

Disclosure: None of the authors has a financial interest in any of the products, devices, or drugs mentioned in this article. The authors declared no potential conflicts of interest with respect to the research, authorship, and publication of this article. This paper was written in the context of a Master's degree, funded by the Biomedical Sciences Recruitment Grant from the University of Montreal, the Canada Graduate Scholarship – Master's (CGSM) from the Canadian Institutes of Health Research (CIHR) and the Master's Training Award from the Fonds de recherche du Québec – Santé (FRQS).

Related Digital Media are available in the full-text version of the article on www.PRSGlobalOpen.com.

Microtia is present in up to 66%–99% of all HFM cases^{5–7} and has been shown to significantly hinder patients' psychosocial well-being.^{8,9} The reconstructive principles and techniques pertaining to microtia reconstruction are less reliable in this patient population due to the ipsilateral microsomia and subsequent asymmetry. Firstly, relying on contralateral measurements relative to the midline often results in the auricular construct being positioned too posteriorly.¹⁰ Also, the remnant earlobe and/or vestige skin is often located too anterior/inferior, and therefore cannot be used as an indication to the ear's ideal location.¹¹ This also makes reconstructing the earlobe more technically challenging.¹² Furthermore, in patients with more severe facial asymmetry and hypoplasia, creating a construct identical in size to the contralateral side's may result in an ear that appears disproportionately large.¹⁰ Classical coverage techniques are also unsuitable, mainly due to the taut and thin retroauricular skin,^{13,14} the underdeveloped temporoparietal fascia and underlying temporal muscle,^{12,15} the low hairline causing a lack of non-hair-bearing skin,¹³ and the unreliable arterial anatomy.^{14,16} These factors, combined with a depressed temporal bone, may also hinder successful ear elevation with an appropriate projection and cranioauricular angle.^{12,17}

In light of the many unique challenges plastic surgeons face regarding microtia reconstruction in HFM patients, the authors aimed to synthesize the literature to retrieve challenge-specific recommendations and highlight the strengths and limitations of each. Given the high degree of variability among observed techniques and the lack of a gold standard for treatment, a systematic review of the literature was deemed of utmost importance. The authors hope this review can provide an evidence-based guide for plastic surgeons and will ultimately improve surgical care for this patient population.

MATERIALS AND METHODS

A systematic search of the Pubmed, Medline, and Embase databases was carried out in line with the Preferred Reporting Items for Systematic Reviews and Meta-Analyses (PRISMA) guidelines,¹⁸ using the following search strategy: (“otoculoauriculovertebral” OR “Goldenhar” OR “hemifacial microsomia” OR “craniofacial microsomia” OR “otomandibular dysplasia”) AND (“microtia” OR “ear”). The search was confined to the English and French languages, and articles from all years were considered. Following duplicate removal, the resultant articles were assessed by two independent reviewers according to strict inclusion and exclusion criteria (Fig. 1). Discrepancies were resolved by means of consensus. All studies that discussed their surgical microtia reconstruction technique in the context of HFM patients were included, regardless of study design. Those that were nonspecific to HFM, that discussed other types of craniofacial anomalies (eg, Treacher Collins), that did not touch on their microtia reconstruction technique, that described prosthetic-based reconstruction, or that did not have a retrievable full text were excluded. Qualitative data regarding study design, type and number of patients, surgical modalities used,

Takeaways

Question: What are the available surgical modalities and their respective levels of evidence when it comes to microtia reconstruction in hemifacial microsomia (HFM) patients?

Findings: Through a systematic review of the literature, eight main HFM-specific challenges were identified. A total of 22 recommendations were retrieved pertaining to such. These were found to be of either grade C (n = 5) or D (n = 17).

Meaning: Many persisting reconstructive challenges regarding surgical microtia reconstruction for HFM patients exist, and their surgical solutions are mainly based on low levels of evidence.

follow-up times, surgical results, challenges addressed, specific recommendations, and their respective strengths/limitations were extracted. All included studies were assessed for level of evidence according to the Oxford Centre for Evidence Based Medicine criteria¹⁹ and all recommendations retrieved were given a grade according to the ASPS Scale for Grading Recommendations.²⁰

RESULTS

Following the removal of duplicates, the search yielded 762 studies, of which 11 met the inclusion criteria (Fig. 1). The majority were case series (n = 7/11), and follow-up times varied from 3 months to 10 years, with five studies not reporting any follow-up time. The majority of the studies utilized autologous rib graft as their surgical modality (n = 9/11). Both two-stage (n = 6) and three-stage techniques (n = 5) were described. In terms of level of evidence, seven studies were assigned a grade 4 level, while the remaining four were considered level 2b. These findings are summarized in Table 1. Regarding challenges addressed, seven studies (64%) presented techniques for the ideal placement of the construct,^{10,12,21–23,25,26} six (55%) addressed the low-set hairline,^{12–14,22,25,26} six commented on primary coverage of the constructed auricle,^{12–14,24–27} another six commented on how to utilize the remnant earlobe/vestige skin,^{11–14,25,26} five (46%) provided recommendations to improve construct projection,^{12,13,22,23,25,27} two studies (18%) commented on the anomalous course of the neighboring neurovascular systems,^{22,26} two expounded on their techniques for retroauricular coverage of the construct,^{24,25} and finally, two provided tips on how to achieve the most appropriate construct size^{10,25} (See table, Supplemental Digital Content 1, which displays the challenge-specific recommendations and their respective advantages/disadvantages. <http://links.lww.com/PRSGO/C145>.) The individual recommendations from each study were consolidated, yielding a total of 22 that were of either grade C (n = 5) or D (n = 17) (Table 2).

DISCUSSION

To the best of our knowledge, this is the first systematic review addressing microtia reconstruction in HFM

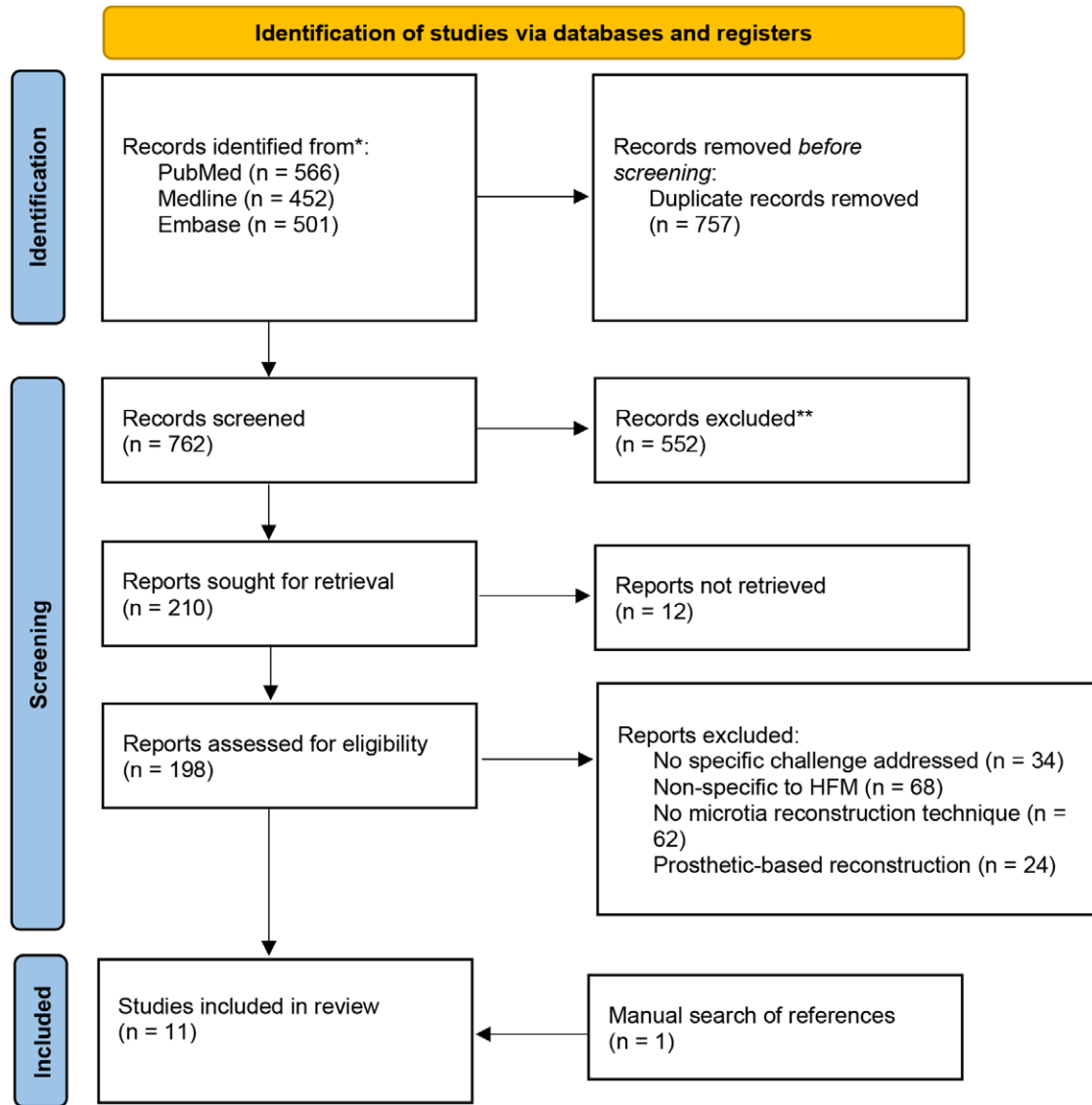


Fig. 1. PRISMA flow chart for systematic review.

patients. This is an especially important endeavor given the relatively low quality of evidence regarding auricular reconstruction²⁸ and the many persisting surgical challenges associated with this patient population. Eleven studies were included in this review, and these yielded 22 graded recommendations regarding the eight HFM-specific challenges identified (Fig. 2). Most recommendations were found to be of low level of evidence, although all authors report successful outcomes with their respective techniques.

Challenges Addressed

Regarding placement of the constructed auricle, most authors agree that the appropriate vertical location can be accurately determined while in the front-facing position, using the healthy earlobe as a guide to the inferior-most position.^{12,25} The main problem arises when attempting to determine the ear's antero-posterior location. Mirroring

distances from the lateral canthus to the helix and from the oral commissure to the lobule, as classically taught, will result in an ear positioned far too posteriorly. Using such principles as a guide, the surgeon must then subjectively determine the optimal placement to produce a more harmonious aesthetic result.²² Although no universal consensus exists to remedy this problem, multiple options have been proposed. Park and Park²⁵ suggest using the posterior margin of the mandibular ascending ramus as a guide, while Qian et al¹² propose placing the crus of the helix 1.5 to 2 cm from the temple. Regarding the ear's proper axis, the literature is no different from classical microtia reconstruction in that it recommends referencing the line along the nasal dorsum, and using the contralateral ear to determine the appropriate cranioauricular angle.^{12,25} Other studies propose novel methods of determining the ear's ideal location, such as using stereophotogrammetry-based morphing of the unaffected ear onto the affected side through

landmark-based facial proportions¹⁰ or by using a 3D printed model of the patient's head and subjectively determining the best possible location.²³ Some even advocate for skeletal correction before ear placement²⁶ or waiting until at least 8 years of age²¹ to mitigate this challenge. Although auricle positioning was the most commonly addressed issue, some studies were nevertheless vague regarding their technique for placement of the construct,^{13,14,24} which is concerning given that this can be a major determinant of overall surgical success. Interestingly however, through their precise computer modeling, Coward et al¹⁰ showed that freehand techniques yield fairly precise placement, potentially obviating the need for more sophisticated methods.

Regarding the abnormally low-set hairline, most authors are proponents of laser hair removal before undergoing two-stage reconstruction.^{13,25,26} Preoperative laser epilation facilitates construct inset and prevents potential thermal damage to the construct and overlying soft tissue. However, in three-stage reconstruction with an expander, Chen et al¹⁴ demonstrate in their case series of 41 patients that treatment during the expansion period required fewer sessions than if started pre-operatively ($P < 0.001$). Qian et al¹² echo this, and explain that laser hair removal is more effective when the skin is thinner. Finally, Firmin²² also stresses the importance of sideburn reconstruction for optimal aesthetic appearance, through either a scalp transposition flap or a hair transplant.

Regarding soft tissue coverage of the constructed auricle, most of the included articles advocate for a three-stage technique, whereby the first consists of expanding the retroauricular skin. Tissue expansion obviates the need for a fascial flap and skin grafts, which have been reported to result in uneven spotty skin, more visible scars, and alopecia.¹²⁻¹⁴ Despite slightly prolonging the overall treatment duration, it renders better aesthetic outcomes and preserves the temporal fascia for potential management of framework exposure in the third stage if necessary.¹²⁻¹⁴ However, in a large comparison of three coverage techniques, Park and Park²⁵ conclude that in addition to being slow and cumbersome, the expansion technique yields the poorest results. They recommend the “embedded and elevation” technique in mild cases (mild to moderate degree of low hairline, usable remnant vestiges, mastoid skin available) and a grafted temporoparietal fascia flap in severe cases (mastoid depression, low hairline, small and/or remarkably low-set ear vestiges). It should be noted that some cases of fascial flap reconstruction resulted in poorly defined anteroauricular subunits from thick or contracted fascia and color mismatch from the scalp graft. This was, however, easily remedied by secondary debulking and re-grafting with contralateral postauricular skin.²⁵ Should surgeons still prefer the two-stage method, Yamada et al²⁶ suggest using a mastoid flap with a subcutaneous pedicle, combined with a temporoparietal fascia flap and skin graft, whereas Nuri et al²⁴ suggest using a pericranial flap instead. Surgeons should also remain suspicious of the quality of the vascular supply to the fascial flap, and may need to raise the superficial/deep temporal fascia in one piece.²⁶

Regarding earlobe reconstruction and usage of the remnant vestige skin, most authors propose carrying out a retrograde lobular transposition at either the first stage (in two-stage reconstruction) or the third stage (three-stage expander-based reconstruction).¹¹⁻¹³ It provides a natural appearance and ideal location, and allows for earrings. However, it can sometimes require future revision due to an “arch bridge” deformity.¹¹ Retrograde lobular transposition is indicated when the vestige ear is located lower than usual (which is most often the case), but a mix of a V-Y advancement, Z-plasty, and/or lobular transposition may be used when the vestige is slightly higher than that.^{12,14} If one finds that the vestige skin cannot be used, it can safely be removed, in which case the earlobe is to be included in the construct design through a long helix and addition of remnant cartilage.¹⁴ Some even propose using the removed vestige skin as a skin graft for coverage of the fascial flap.²⁵

Regarding construct projection, surgeons need to take into account the degree of hypoplasia of the structures upon which the ear sits (mastoid, zygomatic process, temporal condyle).²² Lee and Oh¹⁷ also surmise that hypoplasia of the superficial temporal artery and its posterior branches might create an unfavorable environment for graft take, leading to partial graft loss, secondary wound contracture, and eventually insufficient projection. Regardless, the literature agrees that this should be compensated for, mainly by placing the conchal bowl more superiorly, to the upper, flat, and solid part of the temporal bone.^{12,13} In their embedded and elevation technique, Park and Park²⁵ suggest inserting a preserved cartilage block underneath the framework during elevation. Similarly for porous polyethylene (PPE)-based reconstruction, Kimura et al²³ propose determining the correct projection with the help of a 3D printed model of the patient's head, and then re-creating it intra-operatively by augmenting the construct with separate PPE blocks.

Regarding the anomalous superficial temporal artery and facial nerve, Firmin²² first suggests the use of a pre-operative Doppler to map out the artery's location, as it is often more posterior than expected. Surgeons should also be mindful as to the possible aberrant course of the facial nerve while elevating flaps. Firmin²² describes a case of iatrogenic injury to the frontal branch of the facial nerve coursing through the vestige skin resulting in ipsilateral paralysis of the frontalis. Yamada et al²⁶ also promote caution while raising the fascial flap, to avoid violation of the temporal branch of the facial nerve, and warn surgeons to be wary of the popular belief that an incision is “safe within the hairline.” The literature even reports a case of Frey's syndrome following microtia reconstruction in a HFM patient, due to this aberrant nerve anatomy.²⁹

Regarding retroauricular coverage of the constructed auricle, skin grafting is most commonly used; however, the presence of arterial anomalies can negatively affect its healing process.¹⁴ Nuri et al²⁴ thus recommend using a free serratus fascial flap to cover the posterior aspect of the cartilage, whereas Park and Park²⁵ describe a fan-shaped mastoid fascia flap.

Table 1. Summary of Included Studies

Author (Year)	Study Design	Level of Evidence	Patients	Surgical Modality	Follow-up	Challenge(s) Addressed	Results
						Earlobe reconstruction/usage of vestige skin Coverage of the construct	— <ul style="list-style-type: none"> • 90.2% were satisfied with the reconstructed ear, the rest were partially satisfied, none were unsatisfied • Expander leakage happened in five cases (12.2%) in late expansion period and were managed by expander replacement operation under local anesthesia • Similar rate of hospital stay (about 4 d to 1 wk for each stage) and recovery time (6 mo–1 yr)
						Location of the construct Low hairline	— <ul style="list-style-type: none"> • Patients starting the intense pulse light depilation during the expansion period required less sessions than those who started before the operation • Epifolliculitis occurred in seven cases (17.1%), and were managed by conservative treatment
Chen et al. (2020) ¹⁴	Case series	4	n = 41	Autologous rib graft 3-stage	13.3 mo (range: 10 mo–4 yr)		
Cheng et al. (2015) ¹¹	Case series	4	Moderate/severe HFM Lobule-type microtia n = 42	Autologous rib graft 2 and 3-stage (mixed)	NS	Earlobe reconstruction/usage of vestige skin	<ul style="list-style-type: none"> • All lobular transpositions survived • Delayed healing due to local hematoma (n = 2) • Vaulted earlobes (n = 4)
Chowchuen et al. (2011) ²¹	Case series	4	n = 23	Autologous rib graft 2-stage	NS	Location of the construct	—
Coward et al. (2014) ¹⁰	Case series	4	n = 10	Not specified	NS	Location of the construct	<ul style="list-style-type: none"> • Morphed ears were positioned slightly farther forward on the face than the natural ears in relation to nasion and subnasale (due to their smaller dimensions) • The vertical positions were generally very similar • Length, width, and insertion lengths of the natural ears generally were very similar to the morphed and artificial ears, and no statistically significant differences were found. • 1 case of iatrogenic frontalis paralysis
Firmin et al. (2001) ²²	Case series	4	n = 139	Autologous rib graft 2-stage	NS	Size of the construct Anomalous course of frontal branch of facial nerve Anomalous course of superficial temporal artery Projection of the construct Location of the construct Low hairline	— — — — —
Kimura et al. (2021) ²³	Prospective cohort	2b	n = 6 grade III microtia	Porous polyethylene 1-stage	3–4 months	Projection of the construct Location of the construct	— —
Nuri et al. (2017) ²⁴	Case series	4	n = 2	Autologous rib graft 2-stage	4 yr	Retroauricular coverage	<ul style="list-style-type: none"> • At 4 yr follow-up, in both cases and projections of the constructed ears were satisfactorily maintained.
Park and Park (2018) ²⁵	Retrospective chart review	2b	n = 52	Autologous rib graft 2, 3, and 4-stage (separate)	33 mo (range: 6 mo–0 yr)	Location of the construct Coverage of the construct	— <ul style="list-style-type: none"> • Early postoperative infections or delayed healing of the coverage tissue did not occur in any of the reconstructed cases. • 11 cases (21.2%) showed delayed resorption of the grafted cartilage
						Location of the construct Low hairline Projection of the construct Retroauricular coverage Size of the construct	— — — — —

(Continued)

Table 1. (Continued)

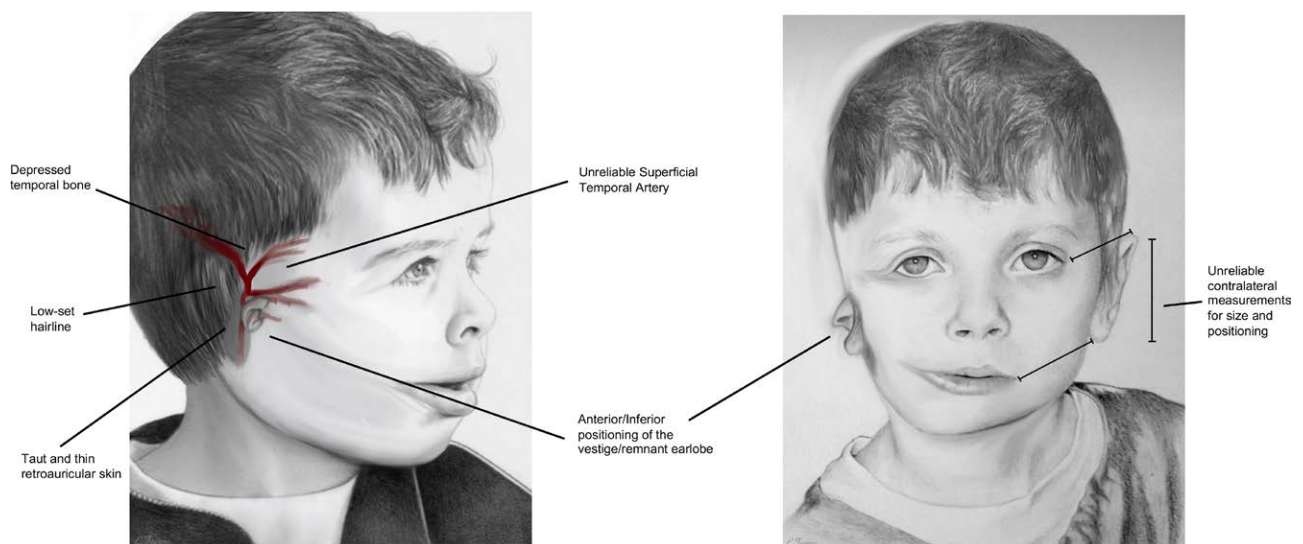
Author (Year)	Study Design	Level of Evidence	Patients	Surgical Modality	Follow-up	Challenge(s) Addressed	Results
Qian et al (2017) ¹²	Retrospective chart review	2b	n = 111	Autologous rib graft 3-stage	8.3 mo (range: 5–20 mo)	Coverage of the construct	<ul style="list-style-type: none"> • 103 patients (92.8%) had satisfactory outcomes, seven patients (6.3%) had partially satisfactory outcomes, and one patient (0.9%) had an unsatisfactory outcome. • First stage: hematoma in two cases (1.8%), infection of the tissue expander in one case (0.9%), necrosis of expanded skin in two cases (1.8%), and leakage of the tissue expander in one case (0.9%). • Second stage: poor skin graft survival in one case (0.9%) and cartilage framework exposure in two cases (1.8%).
Xing et al (2020) ¹³	Retrospective chart review	2b	n = 69 Goldenhar syndrome 53 lobule-type microtia, 16 conchal-type	Autologous rib graft 3-stage	(range: 6 mo–7 yr)	<p>Earlobe reconstruction / usage of vestige skin</p> <p>Location of the construct</p> <p>Low hairline</p> <p>Projection of the construct</p> <p>Coverage of the construct</p>	<ul style="list-style-type: none"> • One case suffered expander leakage • Hematoma occurred in four cases • One case suffered skin necrosis and cartilage exposure • The reconstructed ears showed correct position, clear outline, invisible scarring and contended bilateral symmetry. Sixty-three patients and their families (91.3%) responded satisfied or partially satisfied outcomes.
Yamada et al (2009) ²⁶	Case series	4	n = 6	Autologous rib graft 2-stage	NS	<p>Earlobe reconstruction / usage of vestige skin</p> <p>Location of the construct</p> <p>Low hairline</p> <p>Projection of the construct</p> <p>Anomalous course of facial nerve</p> <p>Coverage of the construct</p>	<ul style="list-style-type: none"> • In types 1 and 2, the size of the reconstructed ear and the definition of the auricle seem to be well maintained, whereas in type 3 hemifacial microsomia, the auricle shrinks and the definition becomes poor over time.

Table 2. Graded Recommendations Stratified by Challenge Addressed

Challenge	Recommendation	Grade of Recommendation
Anomalous course of the facial nerve and superficial temporal artery	• Be mindful during dissection and while raising flaps in the region	C
	• Preoperative Doppler to map out artery location	D
Construct coverage	• Three-stage technique, where the first consists of expanding the retroauricular skin	C
	• Two-stage technique using a mastoid flap with a subcutaneous pedicle, combined with a temporoparietal fascia flap and skin graft	D
	• Embedded and elevation technique in mild cases and a temporoparietal flap in severe cases	D
Earlobe reconstruction/usage of vestige skin	• Mobilize with retrograde transposition if at usual low location (1st stage in Nagata, 3rd stage in expander)	C
	• Mobilize with V-Y advancement, Z-plasty, and/or transposition if at abnormally high location	D
	• If remnants unusable, removed them and use as skin graft for coverage of the fascia flap and/or include earlobe structure in construct design (long helix + remnant cartilage)	D
Location	• For vertical position, using the healthy earlobe as a guide to the inferior-most position and determine while in front-facing position	D
	• For horizontal position, use the posterior margin of the mandibular ascending ramus as a guide or place the crus of the helix 1.5 to 2 cm from the temple	D
	• For axis/angle, use dorsum of the nose and the contralateral ear	D
	• Use a computer-based morphing system to predict all three positions, relying on landmark-based facial proportions	D
	• Determine all three positions pre-operatively by subjectively placing ear on 3D model of patient's face	D
Low hairline	• Pre-operative laser hair removal (in 2-stage or severe cases)	C
	• Peri-inflation laser hair removal (in 3-stage)	D
	• Recreate the side-burns (by a transposition flap or hair transplant)	D
Projection	• Increase the placement height of the concha	C
	• Determine by subjectively placing ear on 3D model of patient's face and augment construct using PPE blocks	D
Retroauricular Coverage	• Use a free serratus fascial flap	D
	• Use a fan-shaped mastoid fascia flap (for embedded and elevation technique)	D
Size	• Vertical length of the construct should be made slightly smaller than the normal side's (in severe cases)	D
	• Copying the normal ear's size by freehand method is reliable, although it can be done with a highly precise computer-based morphing system	D

Finally, regarding sizing of the constructed auricle, Park and Park²⁵ note that the vertical length should be made slightly smaller in severe HFM cases. This is due to

the illusory effect that the reconstructed ear's uppermost portion is higher than that of the contralateral ear when placing its lobule at the same height. Most authors do not


Fig. 2. Illustration of challenges for microtia reconstruction among hemifacial microsomia patients.

specify their technique for sizing, and likely replicate the normal ear's size by freehand techniques. This seems to be a fairly reliable method, as Coward et al¹⁰ demonstrated that as per their highly precise computer-based morphing technique, no appreciable differences were detected between their predicted construct size and those of the already reconstructed artificial ears in their HFM cohort.

Other Considerations

It is worth mentioning that many of the categories discussed above may be impacted by the type of construct used (ie, PPE vs. autologous rib graft). The use of a PPE-based construct may require some form of adaptation to the challenges encountered. Namely, given the precarious nature of the superficial temporal system, classical coverage with a superficial temporal fascia flap may need to be revisited. Also, staged hair removal may need reconsideration, as this procedure is usually done in one stage when a polyethylene framework is used. Another option always available is an ear prosthesis, despite most surgeons agreeing that microtia is best addressed among HFM patients through surgical means.³⁰ Many studies have shown that prostheses can be reliably used in the HFM population, and with fairly low complication rates.^{31–33} Finally, it is also important to be mindful that microtia often presents with concomitant hearing loss.³⁴ Surgeons should consider treatment of the external ear and the hearing apparatus as a unified system, especially since treating hearing impairment has been suggested to have an even greater positive psychosocial impact than microtia reconstruction.³⁵ Obtaining a CT-scan of the temporal bone between 5 and 6 years of age to assess the external ear canal and the middle/inner-ear structures should be standard of care.²¹

Limitations and Future Directions

The main limitation of this review is the low level of evidence of the included studies, decreasing the strength of the conclusions drawn from this synthesis. This review serves to further emphasize the need for large, prospective studies to determine the optimal surgical modalities for treating microtia in hemifacial microsomia patients. While 3D printing is becoming more accessible, some authors have proposed creating personalized splints anchored on the maxilla to guide proper placement in microtia reconstruction.³⁶ Although this exact model cannot be used in HFM patients, perhaps an adaptation of such could be devised. This is especially intriguing, considering that many authors hold that the auricle is in reality not located in the face mask, but rather on the temporal bone and thus its proportions with cranium should be unaffected.^{22,26} Other than construct placement, there is yet to be a consensus regarding the superiority of construct coverage techniques, which may steepen the learning curve for young surgeons. This question would benefit from future, multi-center studies, as the relative rarity of this condition likely explains the paucity of a consensus. It is also curious to note that the majority of the studies included in this review originate from centers located in Asia. This points at a potential publication bias and a lack of general interest among researchers from other parts of

the world. Given that this condition is no less common in North America, the authors hope this review encourages surgeons to continue reporting their outcomes in the field. Finally, although not a classical indication, surgeons should expect that in the wake of the COVID-19 pandemic, more patients may seek microtia reconstruction in general to allow for adequate mask wear, further strengthening the timeliness of such a consolidation.³⁷

CONCLUSIONS

Although HFM is one of the most common craniofacial anomalies and most of its population has microtia, many challenges regarding its surgical treatment have persisted. This is why the authors sought to retrieve evidence-based recommendations regarding these challenges, which are graded and presented in this review. By providing surgeons with a consolidation of available options and their respective level of evidence, the authors hope a transition toward a more evidence-based care for microtia reconstruction in HFM patients will be facilitated.

Sabrina Cugno, MD, MSc, FRSCS, FACS, FAAP
Division of Plastic Surgery, McGill University
Montreal Children's Hospital
1001 Décarie Boulevard
B05.3310 Montreal
Quebec H4A 3J1
Canada
E-mail: scugno@hotmail.com

REFERENCES

- Birgfeld C, Heike C. Craniofacial microsomia. *Clin Plast Surg.* 2019;46:207–221.
- Paul MA, Opyrchal J, Knakiewicz M, et al. Hemifacial microsomia review: recent advancements in understanding the disease. *J Craniofac Surg.* 2020;31:2123–2127.
- Gougoutas AJ, Singh DJ, Low DW, et al. Hemifacial microsomia: clinical features and pictographic representations of the OMENS classification system. *Plast Reconstr Surg.* 2007;120:112e–113e.
- Bennun RD, Mulliken JB, Kaban LB, et al. Microtia: a microform of hemifacial microsomia. *Plast Reconstr Surg.* 1985;76:859–865.
- Luquetti DV, Heike CL, Hing AV, et al. Microtia: epidemiology and genetics. *Am J Med Genet A.* 2012;158A:124–139.
- Poon CC, Meara JG, Heggie AA. Hemifacial microsomia: use of the OMENS-Plus classification at the Royal Children's Hospital of Melbourne. *Plast Reconstr Surg.* 2003;111:1011–1018.
- Park JU, Do TH, Kwon GY, et al. Statistical analysis using the OMENS classification in Oriental patients with hemifacial microsomia: a comparative analysis with Western centers. *Ann Plast Surg.* 2014;72:50–55.
- Jiamei D, Jiake C, Hongxing Z, et al. An investigation of psychological profiles and risk factors in congenital microtia patients. *J Plast Reconstr Aesthet Surg.* 2008;61 Suppl 1:S37–S43.
- Hamilton KV, Ormond KE, Moscarello T, et al. Exploring the medical and psychosocial concerns of adolescents and young adults with craniofacial microsomia: a qualitative study. *Cleft Palate Craniofac J.* 2018;55:1430–1439.
- Coward TJ, Richards R, Scott BJ. Development of a morphing technique for predicting the position and size of an artificial ear in hemifacial microsomia patients. *Int J Prosthodont.* 2014;27:451–457.

11. Cheng L, Hu JT, Zhou X, et al. The retrograde transposition of the remnant earlobe in patients with low-set microtia. *J Craniofac Surg*. 2015;26:2177–2179.
12. Qian J, Li Z, Liu T, et al. Auricular reconstruction in hemifacial microsomia with an expanded two-flap method. *Plast Reconstr Surg*. 2017;139:1200–1209.
13. Xing W, Qian J, Wang B, et al. Auricular reconstruction with modified expanded two-flap method in Goldenhar syndrome: 7-year experiences. *Int J Pediatr Otorhinolaryngol*. 2020;139:110228.
14. Chen Q, Wang B, Wang Y, et al. Using an expanded scalp flap without fascial flap harvest or skin grafting for total auricular reconstruction in hemifacial microsomia with low hairline. *Int J Pediatr Otorhinolaryngol*. 2020;128:109726.
15. Park C, Lew DH, Yoo WM. An analysis of 123 temporoparietal fascial flaps: anatomic and clinical considerations in total auricular reconstruction. *Plast Reconstr Surg*. 1999;104:1295–1306.
16. Serafin D. *Atlas of microsurgical composite tissue transplantation*. Durham, NC: WB Saunders Company; 1996.
17. Lee KT, Oh KS. Predictors for unfavorable projection of the constructed auricle following ear elevation surgery in microtia reconstruction. *Plast Reconstr Surg*. 2018;141:993–1001.
18. Moher D, Liberati A, Tetzlaff J, et al; PRISMA Group. Preferred reporting items for systematic reviews and meta-analyses: the PRISMA statement. *PLoS Med*. 2009;6:e1000097.
19. Centre for Evidence-Based Medicine. Oxford Centre for Evidence-Based Medicine: Levels of Evidence (March 2009). Available at <https://www.cebm.ox.ac.uk/resources/levels-of-evidence/oxford-centre-for-evidence-based-medicine-levels-of-evidence-march-2009>. Accessed November 17, 2021.
20. American Society of Plastic Surgeons (ASPS). *ASPS Scale for Grading Recommendations*. Available at <https://www.plasticsurgery.org/documents/medical-professionals/health-policy/evidence-practice/ASPS-Scale-for-Grading-Recommendations.pdf>. Accessed November 17, 2021.
21. Chowchuen B, Pisek P, Chowchuen P, et al. Craniofacial microsomia: goals of treatment, staged reconstruction and long-term outcome. *J Med Assoc Thai*. 2011;94 Suppl 6:S100–S108.
22. Firmin F, Guichard S. [Microtia in cases of oto-mandibular dysplasia]. *Ann Chir Plast Esthet*. 2001;46:467–477.
23. Kimura K, Davis S, Thomas E, et al. 3D Customization for microtia repair in hemifacial microsomia. *Laryngoscope*. 2021;132:545–549.
24. Nuri T, Ueda K, Yamada A. Application of free serratus anterior fascial flap for reconstruction of ear deformity due to hemifacial microsomia: a report of two cases. *Microsurgery*. 2017;37:436–441.
25. Park JY, Park C. Microtia reconstruction in hemifacial microsomia patients: three framework coverage techniques. *Plast Reconstr Surg*. 2018;142:1558–1570.
26. Yamada A, Ueda K, Yorozuya-Shibazaki R. External ear reconstruction in hemifacial microsomia. *J Craniofac Surg*. 2009;20 Suppl 2:1787–1793.
27. Alfi D, Lam D, Gateno J. Branchial arch syndromes. *Atlas Oral Maxillofac Surg Clin North Am*. 2014;22:167–173.
28. Li Y, Zhang R, Li D. A systematic review of levels of evidence in auricular defects literature: how far has it been during the past three decades? *J Craniofac Surg*. 2015;26:2062–2066.
29. El-Muttardi N, Jabir S, Bulstrode N. Frey's syndrome following total ear reconstruction in hemifacial microsomia. *J Plast Reconstr Aesthet Surg*. 2014;67:e256–e257.
30. Wang RR, Andres CJ. Hemifacial microsomia and treatment options for auricular replacement: a review of the literature. *J Prosthet Dent*. 1999;82:197–204.
31. Hamming KK, Lund TW, Lander TA, et al. Complications and satisfaction with pediatric osseointegrated external ear prostheses. *Laryngoscope*. 2009;119:1270–1273.
32. Lim SK, Tong J, Cheng AC. Maxillofacial prosthetic management of an auricular defect for a young patient with hemifacial microsomia: a clinical report. *Singapore Dent J*. 2011;32:33–38.
33. Chng CK, Gandedkar NH. Implant-retained prosthetic auricular reconstruction in a hemifacial microsomia individual: a clinical report. *Int J Prosthodont*. 2017;30:54–57.
34. Rahbar R, Robson CD, Mulliken JB, et al. Craniofacial, temporal bone, and audiologic abnormalities in the spectrum of hemifacial microsomia. *Arch Otolaryngol Head Neck Surg*. 2001;127:265–271.
35. Mandelbaum RS, Volpicelli EJ, Martins DB, et al. Evaluation of 4 outcomes measures in microtia treatment: exposures, infections, aesthetics, and psychosocial ramifications. *Plast Reconstr Surg Glob Open*. 2017;5:e1460.
36. Beckers O, Coppey E, Mommaerts MY. Computer-aided design and manufacturing construction of a pilot guide for a bone-anchored epithesis to replace an absent pinna. *Int J Oral Maxillofac Surg*. 2021;50:815–819.
37. Susarla SM, Park J, Sie K. Mask wear: an important consideration in patients with microtia. *J Oral Maxillofac Surg*. 2022;80:590–591.