

Primary ectopic frontotemporal extradural craniopharyngioma

Reza Pourkhalili, Ahmad Shekarchizadeh¹, Bahram Seif

Department of Neurosurgery, Alzahra Hospital, ¹Department of Neurosurgery, Kashani Hospital, Isfahan University of Medical Sciences, Isfahan, Iran

Abstract We present a case of primary ectopic frontotemporal extradural craniopharyngioma. Primary ectopic craniopharyngiomas are very rare and have been reported involving the fourth ventricle, infrasellar region, lateral ventricle, temporal area, cerebellopontine angle, clivus, corpus callosum, and prepontine cistern. There was just 1 case of craniopharyngioma previously presented in the literature, with nearly same location as the presenting case.

Key Words: Ectopic craniopharyngioma, extradural tumor, extradural cystic lesion

Address for correspondence:

Dr. Bahram Seif, Department of Neurosurgery, Kashani Hospital, Isfahan University of Medical Sciences, Isfahan, Iran. E-mail: bahramseif@yahoo.com

Received: 20.07.2015, **Accepted:** 20.10.2015

INTRODUCTION

Craniopharyngiomas are relatively benign neoplasms (WHO Grade I) and account for 2.5–4% of all intracranial tumors.^[1] They typically arise in the sellar and suprasellar regions.^[2] Primary ectopic craniopharyngiomas are very rare and have been reported involving the fourth ventricle, infrasellar region, lateral ventricle, temporal area, cerebellopontine angle, clivus, corpus callosum, and prepontine cistern.^[3-10] We present a case of primary ectopic frontotemporal extradural craniopharyngioma that treated surgically.

CASE REPORT

The patient is a 17-year-old girl, with chief complaint of severe headache for 4 months. The headache was mostly sensed in the frontal region and vertex, and sometimes followed by the episodes

of nausea and vomiting. Past medical history and drug history were not significant. Neurologic examination revealed no localized findings and neurological deficits.

The patient underwent brain magnetic resonance imaging (MRI). There was an extra axial heterogeneous mixed solid and cystic mass at the left frontal and temporal areas. Its measurement was 18 mm × 36 mm × 66 mm. High signal intensity in T1, and hyposignal to isosignal T2 was noted inside the lesion. There was no remarkable enhancement after the contrast administration [Figure 1].

She underwent surgery and total tumor resection was done via the left frontotemporal craniotomy. There were 2 extradural cystic lesions contain dark gray opaque fluid [Figure 2]. There was also a solid component into each cyst. Postoperative MRI revealed no signs of tumor residual.

Access this article online	
Quick Response Code:	Website: www.advbiores.net
	DOI: 10.4103/2277-9175.180989

This is an open access article distributed under the terms of the Creative Commons Attribution-NonCommercial-ShareAlike 3.0 License, which allows others to remix, tweak, and build upon the work non-commercially, as long as the author is credited and the new creations are licensed under the identical terms.

For reprints contact: reprints@medknow.com

How to cite this article: Pourkhalili R, Shekarchizadeh A, Seif B. Primary ectopic frontotemporal extradural craniopharyngioma. Adv Biomed Res 2016;5:77.

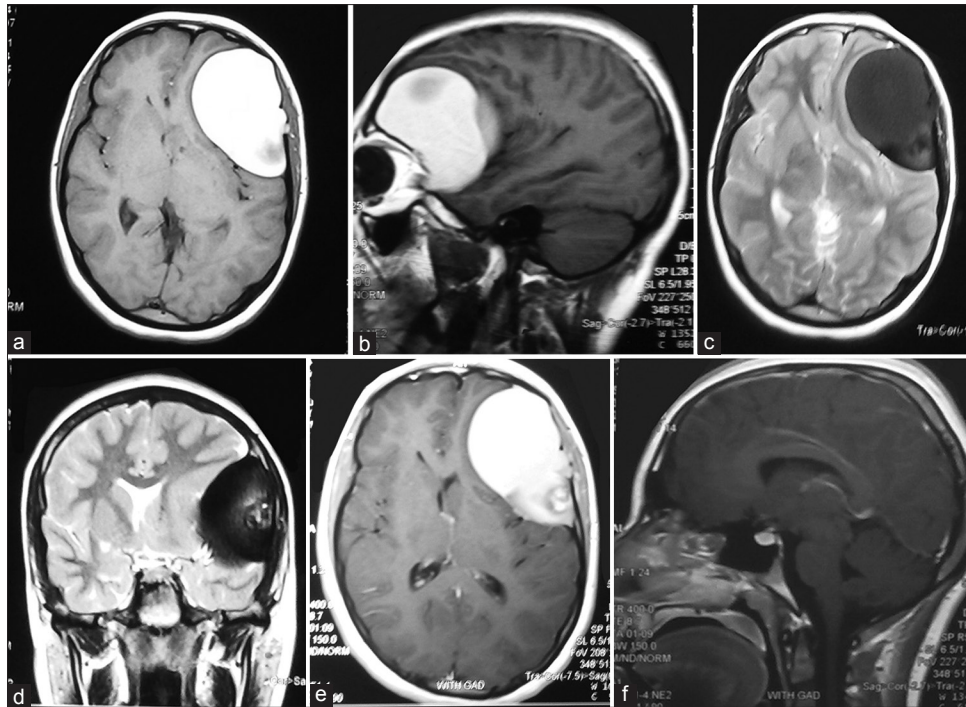


Figure 1: Magnetic resonance imaging studies showing an extra axial heterogeneous mixed solid and cystic mass at the left frontal and temporal areas. (a) Axial T1-weighted magnetic resonance imaging and (b) sagittal T1-weighted magnetic resonance imaging exhibiting a high signal intensity extra axial mass. (c) Axial T2-weighted magnetic resonance imaging and (d) coronal T2-weighted magnetic resonance imaging showing a hyposignal to isosignal mass. (e) Axial T1-weighted magnetic resonance imaging with gadolinium showing no remarkable enhancement after contrast administration. (f) In sagittal T1-weighted magnetic resonance imaging with gadolinium sellar and suprasellar region appear normal

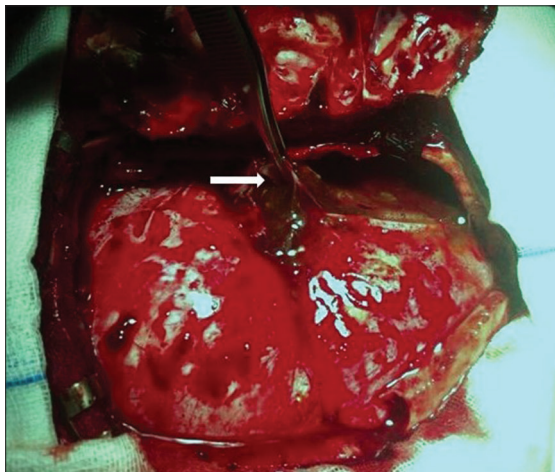


Figure 2: After removal of the bony flap, we saw extracranial cystic lesions contain dark gray opaque fluid

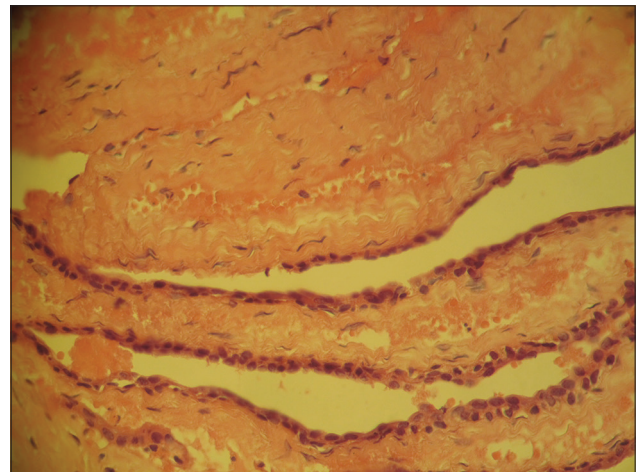


Figure 3: Pathological light microscopy analysis of the lesions shows cystic areas covered by squamous and basaloid epithelium that contain homogenous eosinophilic contents. In some parts of cyst walls, there were infiltration of inflammatory cells, cholesterol cleft formation and calcification (H and E, x200)

The pathological light microscopy analysis of lesions revealed, cystic areas covered by squamous and basaloid epithelium that contain homogenous eosinophilic contents. In some parts of cyst walls, there were infiltration of inflammatory cells, cholesterol cleft formation, and calcification [Figure 3]. These findings were correlating with an ectopic craniopharyngioma.

DISCUSSION

Ectopic presentation of craniopharyngioma is rare. In most cases, ectopic seeding occurs secondary and after the removal of primary suprasellar tumors by direct mechanical implantation of the tumor cells,

or via meningeal seeding.^[6] There was just 1 case of primary craniopharyngioma previously presented in the literature nearly at the same location, as the case we presented above. Ectopic migration of cell remnants of the obliterated craniopharyngeal canal might be the cause.

CONCLUSION

We presented a case of primary ectopic frontotemporal extradural craniopharyngioma. As the treatment of choice for these mass lesions, aggressive surgical resection of the lesion was done. We plan to follow this case with serial brain MRI. Craniopharyngioma should be mentioned as a differential diagnosis for intracranial extradural mass lesions.

Financial support and sponsorship

Nil.

Conflicts of interest

There are no conflicts of interest.

REFERENCES

1. Tayari N, Etemadifar M, Hekmatnia A, Mahzouni P, Maghzi AH, Rouzbahani R. Intrinsic third ventricular craniopharyngioma: A case report. *Int J Prev Med* 2011;2:178-85.
2. Falavigna A, Kraemer JL. Intrasellar craniopharyngioma: Case report. *Arq Neuropsiquiatr* 2001;59:424-30.
3. Shah GB, Bhaduri AS, Misra BK. Ectopic craniopharyngioma of the fourth ventricle: Case report. *Surg Neurol* 2007;68:96-8.
4. Nourbakhsh A, Brown B, Vannemreddy P, Lian T, Nanda A, Guthikonda B. Extracranial infrasellar ectopic craniopharyngioma: A case report and review of the literature. *Skull Base* 2010;20:475-80.
5. Singh J, Ganesan K, Desai SB, Kohli A, Kaushik E. Lateral ventricle craniopharyngioma – MRI demonstration of migratory nature of ectopic craniopharyngioma from the suprasellar region. *Neuroradiology* 2003;13:427-9.
6. Banczerowski P, Bálint K, Sipos L. Temporal extradural ectopic craniopharyngioma. Case report. *J Neurosurg* 2007;107:178-80.
7. Sharma M, Mally R, Velho V, Hrushikesh K. Primary isolated cerebellopontine angle papillary craniopharyngioma. *Neurol India* 2012;60:438-9.
8. Kawamata T, Kubo O, Kamikawa S, Hori T. Ectopic clival craniopharyngioma. *Acta Neurochir (Wien)* 2002;144:1221-4.
9. Sangiovanni G, Tancioni F, Tartara F, Gaetani P, Rindi G, Passeri F, *et al.* Ectopic craniopharyngioma: Presentation of a case arising from the corpus callosum. *Acta Neurochir (Wien)* 1997;139:379-80.
10. Lee IH, Song CJ, Yeon JS, Kim SH, Song KS, Yeo MK. Craniopharyngioma in the prepontine cistern. *AJNR Am J Neuroradiol* 2011;32:E57.