

# A Safe Quick Technique for Placement of the First Access Port for Creation of Pneumoperitoneum

Ahmed Khan Sangrasi, FCPS, Amir Iqbal Memon, FCPS, Muhammad Munir Memon, FCPS, Mujeeb Rehman Abbasi, FRCS, Abdul Aziz Laghari, FRCS, Jawaid Naeem Qureshi, FRCS

## ABSTRACT

**Introduction:** Closed and open techniques for creation of pneumoperitoneum are being used simultaneously with varying frequencies. Some studies analyzing slight modifications to both approaches have been published and others are under way. We conducted this study to eliminate some of the disadvantages of the open technique, an already proven safer technique.

**Patients & Methods:** In a total of 1250 consecutive patients, who underwent various laparoscopic procedures, a modified open technique was used. This technique involves identification and incision of a point at a junction of the umbilical stalk and linea alba infraumbilically. With this technique, penetration of a blunt trocar was possible under direct vision with minimal and controlled axial force. Time needed to induce pneumoperitoneum, intraoperative (vascular and other organ injury) and postoperative complications were recorded, and data were analyzed.

**Results:** Intraabdominal access was successfully achieved in all cases without any vascular or solid organ injury except in 3 (0.24%) cases. In these 3 cases, the procedure failed due to severe adhesions, because of previous abdominal surgeries. Mean time taken to induce pneumoperitoneum was 4.0 minutes (range, 2 to 9.5), while time required to close the first access port was 4.5 minutes (range, 3 to 8). Enterotomy occurred in 2 (0.16%) cases, while a postoperative port-site hernia occurred in 2 (0.16%) cases. Port-site infection occurred in 6 (0.48%) cases, and port-site hematoma in 4 (0.32%) cases. Gas spillage was recorded in only 6 (0.48%) cases.

**Conclusion:** We recommend a modified open technique as the technique of choice in all cases requiring laparo-

scopic surgery in general and developing countries in particular where intraabdominal adhesions are not uncommon.

**Key Words:** Laparoscopy, Pneumoperitoneum, Open technique.

## INTRODUCTION

Despite tremendous recent technical advances in minimally invasive surgical techniques, creation of pneumoperitoneum is still a prerequisite for laparoscopy. The correct method for gaining access into the abdominal cavity is a dilemma, and complications related to the entry technique could be a cause of death.<sup>1-3</sup>

The Veress needle technique is the most commonly used method, but it is associated with slow insufflation rates and potentially life-threatening complications.<sup>4</sup> Hasson introduced an open technique method for port insertion for laparoscopy in 1971.<sup>5</sup> Many studies evaluating advantages and disadvantages of closed or open methods for creation of pneumoperitoneum have been conducted. However, randomized, multicenter clinical studies have not been able to provide a definite answer to which of the 2 methods is safer.<sup>6</sup> Both closed and open techniques are being used simultaneously with varying frequencies. Some studies with slight modifications of both basic approaches have been published and others are on trial. We have been using the open technique with some modification at our institution for various laparoscopic procedures for 10 years with much satisfaction and comfort. Our aim was to present this modified open technique for establishment of the pneumoperitoneum to share our experience with the international community. This study was conducted to examine our experience with the open technique with the objective of evaluating time consumed during creation of pneumoperitoneum, closure of the first port, and to observe complications occurring during the procedure.

## PATIENTS AND METHODS

This prospective nonrandomized observational study was conducted from 2004 to 2009, at Liaquat University of

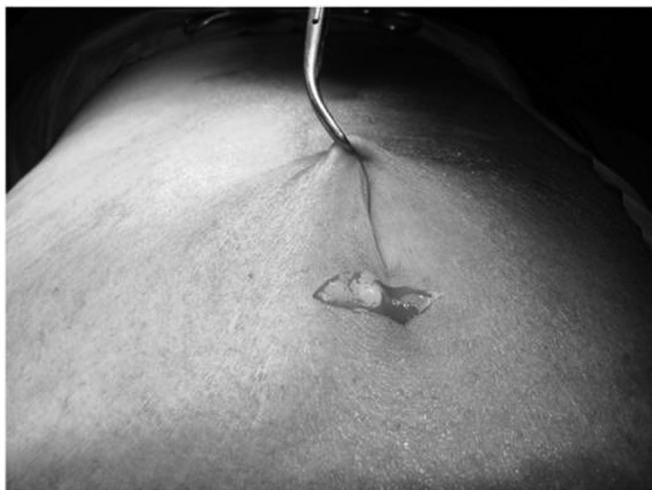Liaquat University of Medical & Health Sciences Jamshoro, Sindh, Pakistan (all authors).

This work was presented as an oral scientific presentation at the 19th SLS Annual Meeting and Endo Expo 2010, New York, USA, September 1-4, 2010.

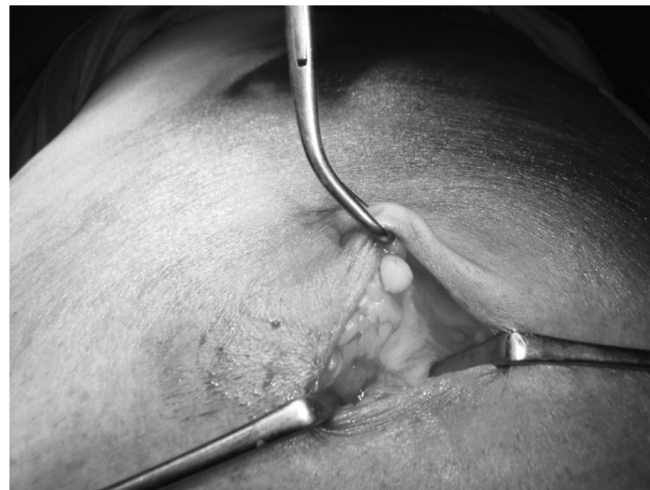Address correspondence to: Ahmed Khan Sangrasi, H.no: 212, Block-G, Citizen Co-operative Housing Society, Hyderabad, Sindh, Pakistan. Telephone: +92-22-2611471, E-mail: ahmedsangrasi@hotmail.com

DOI: 10.4293/108680811X13176785204238

© 2011 by JSLS, *Journal of the Society of Laparoendoscopic Surgeons*. Published by the Society of Laparoendoscopic Surgeons, Inc.



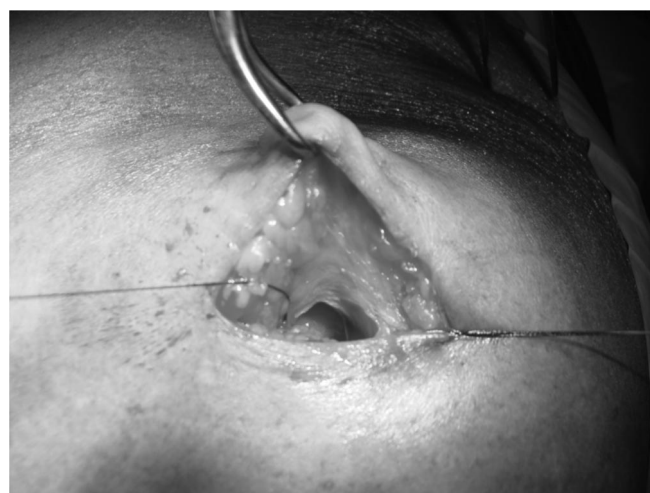**Figure 1.** A small 1-cm to 2-cm infraumbilical incision.



**Figure 2.** Point of incision at the junction of the umbilical stalk and linea alba.

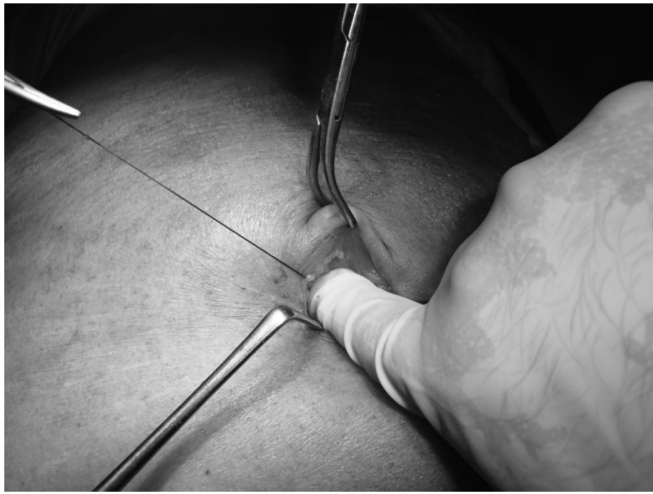Medical & Health Sciences, Jamshoro, Pakistan. In a total of 1250 consecutive patients, who underwent various laparoscopic procedures, a simple modified open technique was used in a general surgical department. All operations were performed by 2 surgeons who are experienced in laparoscopic surgery. The open technique used in this series was similar to the conventional Hasson<sup>7</sup> technique with some modifications as follows:

A small 1-cm to 2-cm transverse incision is made infraumbilically (**Figure 1**). After the separation of the subcutaneous tissue, the umbilical stalk is followed up to its junction with the linea alba. Skin edges are retracted by small Langenbeck retractors to identify the point being incised. The correct identification of this point is important, as this is the point where peritoneum is consistently adherent to the overlying fascia (**Figure 2**). This is in contrast with the original Hasson technique in which an incision is made a little lower down where technically many layers are encountered to get entry into the peritoneum. A towel clamp is applied to the umbilical stalk to retract the umbilicus and abdominal wall. Two stay sutures of Vicryl 1 are placed above and below the point to be incised. These stay sutures are placed just to facilitate closure of the port at the end of procedure. Sometimes, we place these sutures after opening the peritoneum by making small incisions. Whereas, in the conventional Hasson technique, 2 stay sutures are mandatory and incision is made layer by layer. Next, a small incision (<5mm) is made at this point by scalpel or scissors to prevent subsequent loss of insufflation around the cannula (**Figure 3**). In the majority of cases, this small incision gives direct access into the peritoneal cavity. Alternatively, perito-

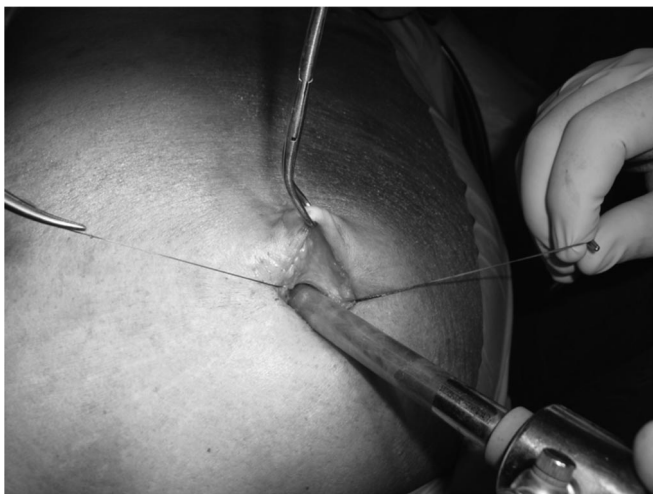


**Figure 3.** A small incision made in fascia at the junction of the umbilical stalk and linea alba.

neum is gently entered with the tip of the index finger or blunt artery forceps. The tip of the index finger is also used to dilate the small facial defect and to feel and divide the periumbilical adhesion, if present (**Figure 4**). A blunt tip reusable cannula is then inserted through the incision under direct vision (**Figure 5**). The cannula is fixed to the abdominal wall after placing wax gauze around it to prevent gas leakage. After high-flow insufflations, a laparoscope is introduced, and organs below the entry site and the remainder of the abdominal cavity are examined in the usual manner. Time is recorded from incision to insertion of the laparoscope, and taken as the time consumed for creation of pneumoperitoneum. Closure of the



**Figure 4.** Index finger inserted to dilate the facial incision and to separate peri-umbilical adhesions.



**Figure 5.** Blunt tip canula inserted under direct vision.

port site was done under direct vision with Vicryl 1 and was greatly facilitated by placement of prior stay sutures. Time of closure of the first port wound and complications during the operative and postoperative periods were recorded and the data analyzed.

## RESULTS

Intraabdominal access was successfully achieved in all cases except 3 (0.24%), in whom the procedure failed due to severe adhesions, because of previous abdominal surgeries, and the operations were converted to open surgery. The mean time taken to induce pneumoperitoneum was 4.0 minutes (range, 2 to 9.5), while time required to

**Table 1.**

Complications	N (%)
Enterotomy	2 (0.16)
Port site hernia	2 (0.16)
Port site infection	6 (0.48)
Port site hematoma	4 (0.32)
Gas leakage	6 (0.48)
Failure of procedure	3 (0.24)

close the first access port was 4.5 minutes (range, 3 to 8). Postoperative mortality was zero and no vascular or solid organ injury was observed. In 23 patients, other minor postoperative complications were recorded and are listed in **Table 1**. Enterotomy was recorded in only 2 (0.16%) cases; both of these patients had severe adhesions due to previous midline laparotomies. Both of these enterotomies were observed immediately and repaired during the same procedure. Other minor complications shown in **Table 1** resolved spontaneously on conservative management. Postoperative port-site hernia was recorded in 2 (0.16%) cases. Both umbilical port hernias were diagnosed during 6 months of follow-up after surgery.

## DISCUSSION

The 2 basic techniques used to gain access into the peritoneal cavity during laparoscopic procedures are blind Veress needle/trocar insertion and the open technique by placement of the trocar under direct vision. Both of these techniques have proponents and opponents with various advantages and disadvantages. Major vascular injury during insertion of a Veress needle or of the first trocar is the most dangerous and life-threatening complication. Major retroperitoneal vessels involved include the vena cava, aorta, right renal vessels, iliac or mesenteric vessels with a mortality of 15%.<sup>8-10</sup> The benefits of the open technique for gaining access into the abdominal cavity were described by Hasson about 3 decades ago.<sup>11</sup> Direct vision allows safe entry by avoiding bowel injury, and even if it occurs, allows immediate recognition and surgical repair. In a pursuit to minimize the complications that occur during gaining access into the abdominal cavity, studies using modified techniques of both open<sup>12</sup> and closed<sup>13</sup> basic approaches have been carried out while others are underway.

There are many older randomized controlled<sup>14-18</sup> as well as recent studies<sup>12,19-21</sup> reporting the open technique as quick and associated with fewer minor com-



plications. We are in agreement with all the present series that report that this technique can be used routinely in the obese and in patients with previous abdominal surgery.<sup>22</sup>

This modified open technique for gaining access into the abdominal cavity affords several distinct advantages over the conventional direct open technique or Veress needle. This is a simple, safe method for penetration under direct vision without cumbersome aspects of the conventional open technique. This modified open technique has some important technical differences with the conventional Hasson technique, which enable quicker and safer entry as well as rapid closure of the port. The point of entry at the junction of the umbilical stalk and linea alba provide a single layer of fascia with firmly adherent peritoneum, without encountering any muscular layer, whereas in the conventional Hasson technique, stay sutures are mandatory and entry into the peritoneum is layer by layer. This technique entails minimal gas leakage around the cannula, compared with the traditional open technique. This is because we make the facial defect smaller than the size of the cannula that is to be inserted. Important factors involved in laparoscopic access injuries include inadequate stabilization of the abdominal wall, excessive resistance to the trocar insertion and misdirected or poorly controlled force along the axis of the trocar,<sup>2</sup> while the safety of laparoscopic entry depends on the control of axial force<sup>2</sup> and controlled entry into the peritoneal cavity.<sup>23</sup> Considering the above safety factors, the modified open technique seems to be ideal. As umbilical fascia is incised at a point where peritoneum is adherent to the fascia, both are incised together; therefore, the resistance to insertion is negligible.

Added benefits of this technique include insertion of the trocar under direct vision and traction of the umbilical stalk by a towel clamp, which increases the distance between the abdominal wall and intraabdominal organs. There are a few other studies that are similar to our study<sup>12,19–21</sup>; authors report similar advantages and encouragement using a modified open technique. There are slight differences in these techniques compared to our techniques; however, the basic steps of lifting the abdominal wall and making an incision at the junction of the umbilical stalk and rectus sheath under direct vision are the same. Encouraged by the excellent results of this study and similar results from other studies as discussed above, we recommend this technique as a simple, safe, and quick approach to be used routinely.

## CONCLUSION

In our experience using this technique, placement of the first access port is simple, safe, and rapid. We recommend the open technique for placement of the first access port as a routine approach in laparoscopy including previous abdominal surgery and obesity.

## References:

1. Philips PA, Amaral JF. Abdominal access complications in laparoscopic surgery. *J Am Coll Surg.* 2001;192:525–536.
2. Bhojru S, Vierra MA, Nezhat CR, et al. Trocar injuries in laparoscopic surgery. *J Am Coll Surg.* 2001;192:677–683.
3. Curet MJ. Special problems in laparoscopic surgery. Previous abdominal surgery, obesity, and pregnancy. *Surg Clin North Am.* 2000;80:1093–1110.
4. Agresta F, DeSimone P, Ciardo LF, et al. Direct trocar insertion vs Veress needle in nonobese patients undergoing laparoscopic procedures: a randomized prospective single-center study. *Surg Endosc.* 2004;18:1778–1781.
5. Hasson HM. A modified instrument and method for laparoscopy. *Am J Obstet Gynecol.* 1971;15:110:886–887.
6. Larobina M, Nottle P. Complete evidence regarding major vascular injuries during laparoscopic access. *Surg Laparosc Endosc Percutan Tech.* 2005;15:119–123.
7. Hasson HM. Open laparoscopy: a report of 150 cases. *J Reprod Med.* 1974;12:234–238.
8. Fitzgibbons RJ Jr., Annibali R, Litke BS. Gallbladder and gallstone removal, open versus closed laparoscopy, and pneumoperitoneum. *Am J Surg.* 1993;165:497–504.
9. Oshinsky GS, Smith AD. Laparoscopic needles and trocars: an overview of designs and complications. *J Laparoendosc Surg.* 1992;2:117–125.
10. Bongard F, Dubecz S, Klein S. Complications of therapeutic laparoscopy. *Curr Probl Surg.* 1994;31(11):857–924.
11. Hasson HM. Open laparoscopy vs. closed laparoscopy: a comparison of complication rates. *Adv Plan Parent.* 1978;13:41–50.
12. Lal P, Singh L, Agarwal PN, et al. Open port placement of the first laparoscopic port: a safe technique. *JLS.* 2004;8:364–366.
13. Perunovic RM, Scepanovic RP, Stevanovic PD, et al. Complications during the establishment of laparoscopic pneumoperitoneum. *J Laparoendosc Adv Surg Tech A.* 2009;19:1–6.
14. Borgatta L, Gruss L, Barad D, et al. Direct trocar insertion vs. Veress needle use for laparoscopic sterilization. *J Reprod Med.* 1990;35:891–894.

15. Byron JW, Markenson G, Miyazawa K. A randomized comparison of Veress needle and direct trocar insertion for laparoscopy. *Surg Gynecol Obstet.* 1993;177:259–262.
16. Cogliandolo A, Manganaro T, Saitta FP, et al. Blind versus open approach to laparoscopic cholecystectomy: a randomized study. *Surg Laparosc Endosc.* 1998;8:353–355.
17. Peitgen K, Nimtz K, Hellinger A, et al. Open approach or Veress needle in laparoscopic interventions? Results of a prospective randomized controlled study. *Chirurg.* 1997;68:910–913.
18. Saunders CJ, Battistella FD, Whetzel TP, et al. Percutaneous diagnostic peritoneal lavage using a Veress needle versus an open technique: a prospective randomized trial. *J Trauma.* 1998;44:883–888.
19. Gett RM, Joseph MG. A safe technique for the insertion of the Hasson cannula. *Aust N Z J Surg.* 2004;74(9):797–798.
20. Antevil JL, Bhoyrul S, Brunson ME, et al. Safe and rapid laparoscopic access—a new approach. *World J Surg.* 2005;29:800–803.
21. Long JB, Giles DL, Cornella JL, et al. Open laparoscopic access technique: review of 2010 patients. *JLS.* 2008;12:372–375.
22. Garry R. Complications of laparoscopic entry. *Gynaecol Endosc.* 1997;6:319–329.
23. Munro MG. Laparoscopic access: complications, technologies, and techniques. *Curr Opin Obstet Gynecol.* 2002;14:365–374.