

Case Report

Atypical Osteomyelitis Caused by *Mycobacterium chelonae*—A Multimodal Imaging Approach

Roland Talanow,¹ Hendryk Vieweg,² and Reimer Andresen²

¹ EduRad, Lincoln, CA, USA

² Institute of Diagnostic and Interventional Radiology/Neuroradiology, Westküstenklinikum Heide, Academic Teaching Hospital of the Universities of Kiel, Luebeck and Hamburg, Germany

Correspondence should be addressed to Hendryk Vieweg; hvieweg@wkk-hei.de

Received 2 February 2013; Accepted 12 March 2013

Academic Editors: M. Caira and J.-F. Faucher

Copyright © 2013 Roland Talanow et al. This is an open access article distributed under the Creative Commons Attribution License, which permits unrestricted use, distribution, and reproduction in any medium, provided the original work is properly cited.

We present an unusual case of a biopsy-proven *Mycobacterium chelonae* infection (MCI) of skin and soft tissue, which led to osteomyelitis in a 55-year-old Caucasian male. We provide clinical data and discussion about MCI and its diagnostic workup and demonstrate comprehensive imaging findings, including clinical pictures, radiographs, three-phase bone scintigraphy, and combined SPECT/CT findings of this entity, which have not yet been presented in the medical literature.

1. Introduction

Mycobacterium chelonae is an atypical mycobacterium which does not cause tuberculosis or leprosy in humans. They are known for infections of skin, lungs, eyes, and soft tissue. People with immunodeficiency are more likely to contract an infection although a minority of concerned patients were reported to be primary healthy. The identification of the agent is performed by bacterial cultures, polymerase chain reaction (PCR), and DNA sequencing [1].

Bone and joint infections are extremely rare in the context of atypical mycobacterium infections [2].

Osteomyelitis is mostly caused by staphylococcus aureus (75–80%), infrequently also by other bacteria, viruses, and fungi [2, 3].

In the medical literature we found only 2 cases of *Mycobacterium chelonae* osteomyelitis visualized by multiple diagnostic imaging modalities [2, 4]. To our best knowledge SPECT/CT findings have not yet been published at all.

2. Clinical Presentation

The patient is a 55-year-old Caucasian male with an unclear redness and swelling at the right medial malleolus without any noticed trauma. His medical record includes ulcerative

colitis and sarcoidosis treated with prolonged cortisone therapy and liver transplant for treatment of primary sclerosing cholangitis (PSC) 14 years ago.

Tentative diagnosis was gout because of high uric acid in blood testing but common ambulant drug therapy with colchicine and indomethacin did not improve the condition. Spreading of the swelling and redness in combination with increasing inflammation parameters was interpreted as possible phlegmon and treated with penicillin. However no regression was observed and the patient developed additional nodular lesions spreading from the ankle to the anterior medial lower leg. Visible were 12–15 nodular lesions, the newest and proximal lesions were erythematous, and the older ones were darker and violaceous with some scaling (Figure 1).

In the following, punch biopsies were performed, which microscopically showed positive results on gram staining and acid resistance on Ziehl-Neelsen staining, matching with mycobacteria. Bacteria cultures revealed rapidly growing mycobacteria of Runyon group IV.

Additional PCR and sequencing of the amplified DNA detected *Mycobacterium chelonae*.

In the course of the events several diagnostic imaging modalities were conducted to find out about a possible osseous involvement, which is important for the appropriate selection of antibiotics.

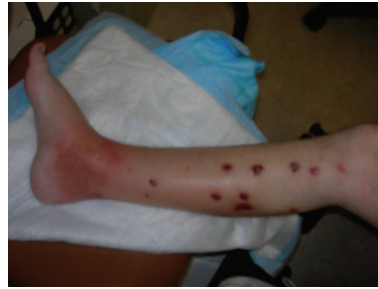

FIGURE 1: Clinical picture shows swelling and erythema over the medial aspect of the right ankle. In addition nodular lesions on the lower leg are seen.

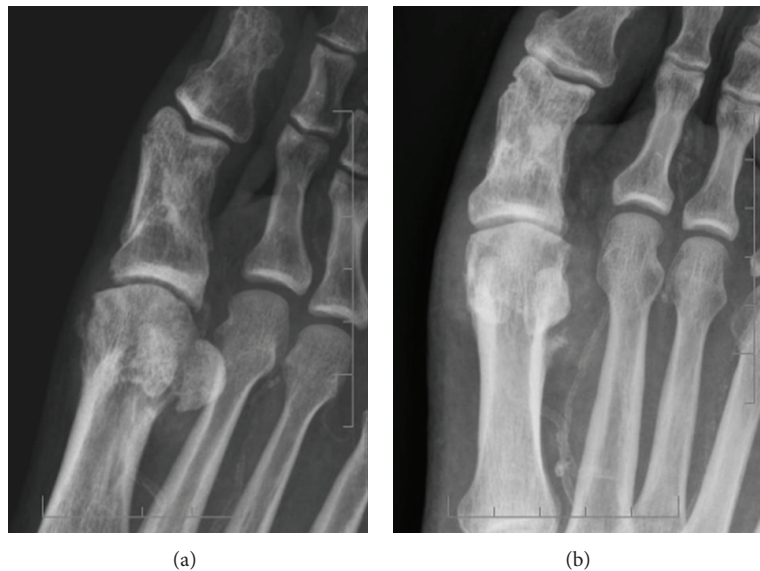

FIGURE 2: Initial radiographs show focal soft tissue reaction around the first MTP joint (emphasized by softer image windowing on (b)) without signs of bone affection. Healed fracture of the proximal first phalanx.

Initially radiographs of the right ankle, tibia, and fibula were obtained, showing moderate circumferential soft tissue swelling around the metatarsophalangeal joint I (MTP I). The ankle mortise was intact with the underlying bony structures appearing normal, beside a healed fracture at the proximal first phalanx (Figure 2).

For further investigation MRI was scheduled but even with sedation refused by the patient due to claustrophobia.

Instead a three-phase bone scan (33 mCi Tc-99 m MDP IV with 24-hour delay) was performed which showed local hyperemia at the right distal lower leg and the MTP I on perfusion phase, surrounding soft tissue tracer uptake on blood pool phase and increased bone remodeling on bone phase, also at the right distal lower leg and the MTP I (Figure 3, bone phase).

Subsequently, using the already given tracer, a combined SPECT/CT was conducted which provides the advantages of better localization and demonstration of morphological changes, compared with scintigraphy.

In the merged pictures we could localize the increased tracer uptake exactly at the distal tibia and the MTP I

(Figure 4). The CT data showed evidence of soft tissue and periosteal reaction and osseous disruption at the MTP I (Figure 5).

The combination of findings was indicative for a soft tissue infection with additional multifocal osteomyelitis, at the MTP I already with initial osseous destructions.

Antibiotic therapy was adjusted, following antibiogram, to a combination of azithromycin, moxifloxacin, and meropenem under which the patient improved. He could be discharged from our hospital in a good condition 2 weeks later.

3. Discussion

Mycobacteria are a heterogeneous group of aerobic bacteria. There are significant differences in the appropriate treatment so that it is important to distinguish between the agents.

The group can be detected by being gram positive and acid-fast on gram and Ziehl-Neelsen staining. The Runyon classification divides into 4 groups, based on growth rates in bacterial cultures. PCR and DNA sequencing are helpful to detect the agent.

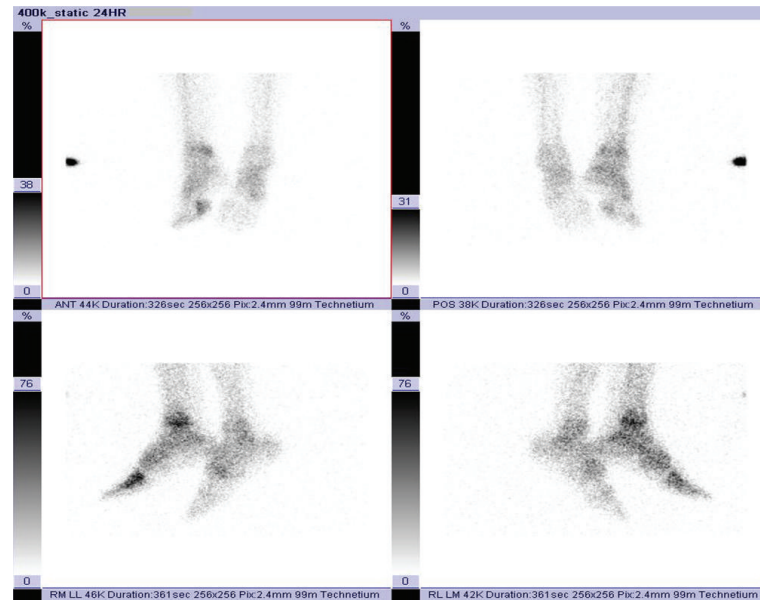


FIGURE 3: Three-phase bone scan was performed, with attention to the ankles and feet (33 mCi Tc-99 m MDP injected IV). The images demonstrate areas of increased delivery of tracer at the right distal lower extremity and around MTP I on bone phase.

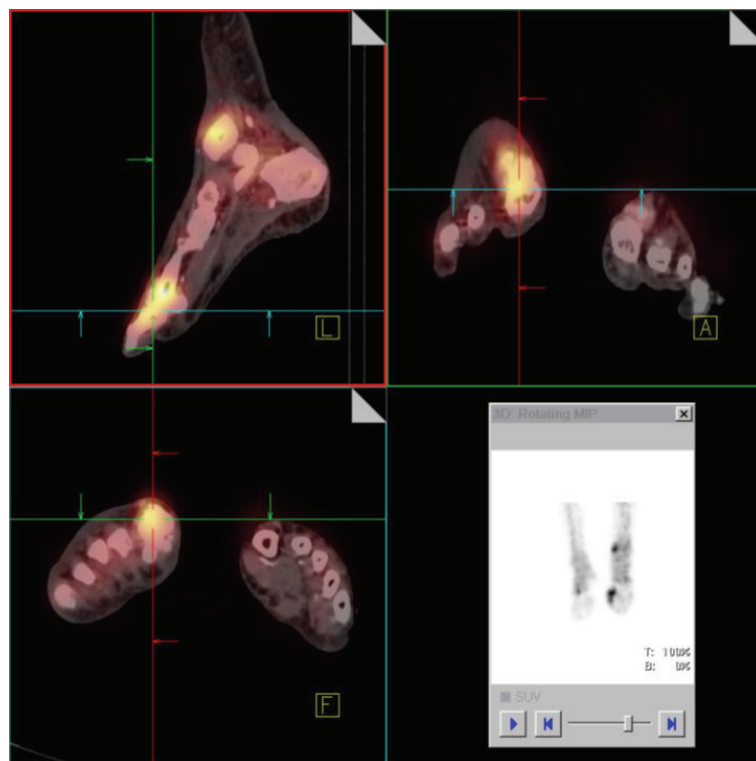


FIGURE 4: Merged SPECT/CT imaging of the lower extremities localizes the increased tracer uptake exactly at the distal tibia and MTP I.

The most familiar mycobacteria are *Mycobacterium tuberculosis* and *Mycobacterium leprae*, both listed in Runyon Group III.

Mycobacterium chelonae is a rapidly growing species (Runyon group IV) of mycobacteria other than tuberculosis

(MOTT). Those do not respond to first-line antituberculosis drugs.

It is found in natural and processed water sources and known to be responsible for a distinct number of primary infections of the skin, lung, eyes, and soft tissue [2, 5–7].

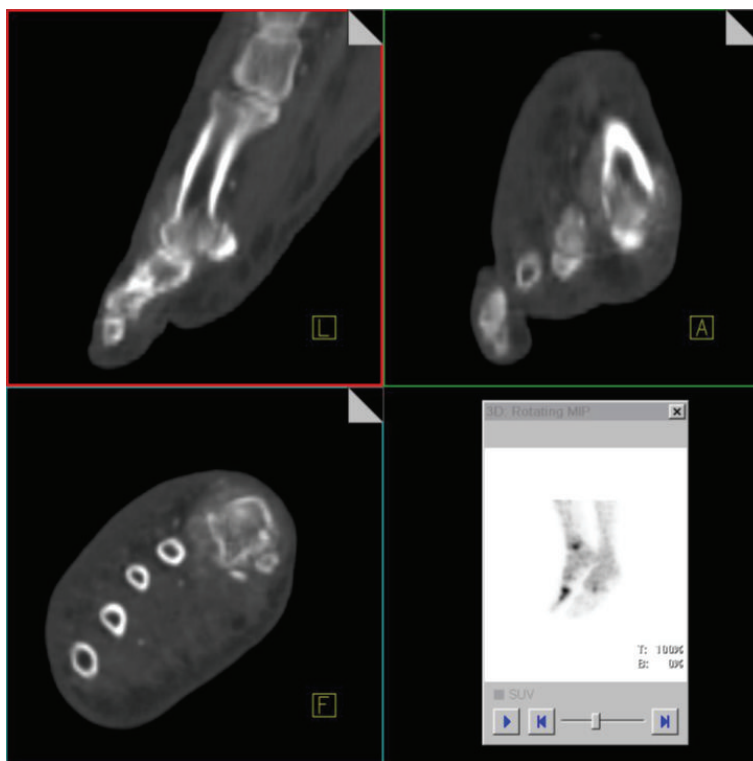


FIGURE 5: CT-data of the combined SPECT/CT demonstrates soft tissue and periosteal reaction and mild osseous disruptions at the MTP I.

As an opportunistic pathogen it should be considered when unclear skin and soft tissue infections occur on immunosuppressed patients like patients on corticosteroid therapy, after organ transplantation and with immunodeficiency or autoimmune disorders.

Infections of the bone and joints by nontuberculous mycobacteria, such as *Mycobacterium chelonae*, are extremely rare and often overlooked with less than a dozen reported cases in the medical literature [2, 8]. However for the selection of antibiotic therapy and for avoidance of chronification, it is of high priority to be aware of possible bone affection.

The disease is often a disseminated cutaneous infection [9, 10], like in our case. If osteomyelitis takes place in this regard, it is usually localized [9, 11] with only one reported case of multifocal osseous involvement [2]. Our findings are indicative for bifocal affection of the distal tibia and the MTP I.

Osteomyelitis by *Mycobacterium chelonae* has occurred occasionally in the sternum after cardiac operations [12, 13] or in immunocompromised patients [8, 10, 14, 15]; however recent publications reported also occurrence in previously healthy patients [4, 6]. Sternal osteomyelitis is associated with a poor clinical prognosis, perhaps related to late diagnosis and consecutive late onset of specific treatment [12].

To our best knowledge only 2 manuscripts have been published, describing *Mycobacterium chelonae* osteomyelitis on imaging [2, 4]. So far no literature has been published, describing SPECT/CT imaging findings of osteomyelitis caused by atypical mycobacteria, especially by *Mycobacterium chelonae*.

All previous reports demonstrated advanced bone changes on imaging, already visible on X-ray. In our case, the initial radiograph was unremarkable for osteomyelitis but we were able to detect the infection with MDP bone scan and get information about localization and morphological changes with a combined SPECT/CT, facilitating appropriate antibiotic therapy.

Conflict of Interests

The authors declare that they have no conflict of interests.

References

- [1] J. M. Lim, J. H. Kim, and H. J. Yang, "Management of infections with rapidly growing mycobacteria after unexpected complications of skin and subcutaneous surgical procedures," *Archives of Plastic Surgery*, vol. 39, no. 1, pp. 18–24, 2012.
- [2] D. S. Korres, P. J. Papagelopoulos, K. A. Zahos, M. D. Kolia, G. G. Poulakou, and M. E. Falagas, "Multifocal spinal and extra-spinal *Mycobacterium chelonae* osteomyelitis in a renal transplant recipient," *Transplant Infectious Disease*, vol. 9, no. 1, pp. 62–65, 2007.
- [3] A. Widaa, T. Claro, T. J. Foster, F. J. O'Brien, and S. W. Kerrigan, "Staphylococcus aureus protein A plays a critical role in mediating bone destruction and bone loss in osteomyelitis," *PLoS One*, vol. 7, no. 7, Article ID e40586, 2012.
- [4] R. S. Kim, J. S. Kim, D. H. Choi, D. S. Kwon, and J. H. Jung, "M. chelonae soft tissue infection spreading to osteomyelitis," *Yonsei Medical Journal*, vol. 45, no. 1, pp. 169–173, 2004.

- [5] A. M. Hernandez Garcia, A. Arias, A. Felipe, R. Alvarez, and A. Sierra, "Determination of the in vitro susceptibility of 220 *Mycobacterium fortuitum* isolates to ten antimicrobial agents," *Journal of Chemotherapy*, vol. 7, no. 6, pp. 503–508, 1995.
- [6] H. Gollwitzer, R. Langer, P. Diehl, and W. Mittelmeier, "Chronic osteomyelitis due to *Mycobacterium chelonae* diagnosed by polymerase chain reaction homology matching: a case report," *Journal of Bone and Joint Surgery A*, vol. 86, no. 6, pp. 1296–1301, 2004.
- [7] S. M. Cook, R. E. Bartos, C. L. Pierson, and T. S. Frank, "Detection and characterization of atypical mycobacteria by the polymerase chain reaction," *Diagnostic Molecular Pathology*, vol. 3, no. 1, pp. 53–58, 1994.
- [8] V. Roy and D. Weisdorf, "Mycobacterial infections following bone marrow transplantation: a 20 year retrospective review," *Bone Marrow Transplantation*, vol. 19, no. 5, pp. 467–470, 1997.
- [9] S. Sungkanuparph, B. Sathapatayavongs, and R. Prachartam, "Infections with rapidly growing mycobacteria: report of 20 cases," *International Journal of Infectious Diseases*, vol. 7, no. 3, pp. 198–205, 2003.
- [10] R. J. Wallace Jr., B. A. Brown, and G. O. Onyi, "Skin, soft tissue, and bone infections due to *Mycobacterium chelonae* chelonae: importance of prior corticosteroid therapy, frequency of disseminated infections, and resistance to oral antimicrobials other than clarithromycin," *Journal of Infectious Diseases*, vol. 166, no. 2, pp. 405–412, 1992.
- [11] N. J. Suttner, Z. Adhami, and A. R. Aspoas, "Mycobacterium chelonae lumbar spinal infection," *British Journal of Neurosurgery*, vol. 15, no. 3, pp. 265–269, 2001.
- [12] F. Robicsek, P. C. Hoffman, T. N. Masters et al., "Rapidly growing nontuberculous mycobacteria: a new enemy of the cardiac surgeon," *Annals of Thoracic Surgery*, vol. 46, no. 6, pp. 703–710, 1988.
- [13] L. E. Samuels, S. Sharma, R. J. Morris et al., "Mycobacterium fortuitum infection of the sternum: review of the literature and case illustration," *Archives of Surgery*, vol. 131, no. 12, pp. 1344–1346, 1996.
- [14] T. C. Pruitt, L. O. Hughes, R. D. Blasier, R. E. McCarthy, C. M. Glasier, and G. J. Roloson, "Atypical mycobacterial vertebral osteomyelitis in a steroid-dependent adolescent: a case report," *Spine*, vol. 18, no. 16, pp. 2553–2555, 1993.
- [15] S. Wilson, B. Cascio, and H. R. Neitzschman, "Radiology case of the month. Nail puncture wound to the foot. *Mycobacterium chelonae* osteomyelitis," *The Journal of the Louisiana State Medical Society*, vol. 151, no. 5, pp. 251–252, 1999.