



Small Intestine Perforation in a 69-Year-Old Man with COVID-19

Arash Miroliaee¹, Najmeh Aletaha^{2*}, Nasser Ebrahimi Daryani³, Foroogh Alborzi Avanaki¹

¹ Assistant Professor, Department of Gastroenterology, Imam Khomeini Hospital, Tehran University of Medical Sciences, Tehran, Iran

² Associate Professor, Department of Gastroenterology, Imam Khomeini Hospital, Tehran University of Medical Sciences, Tehran, Iran

³ Professor, Department of Gastroenterology, Imam Khomeini Hospital, Tehran University of Medical Sciences, Tehran, Iran

ABSTRACT

Coronavirus disease 2019 (COVID-19) had caused pandemia with a high rate of mortality and morbidity. Lung involvement is the main cause of mortality, but central nervous system and cardiac disease, and thromboemboli may participate in increasing mortality. A wide spectrum of organs involvement and complication has been reported as data gathering during the pandemia has progressed. We report a 69-year-old man who was admitted to Imam Khomeini hospital in Tehran and complained of severe abdominal pain and fever. He had been admitted 10 days earlier because of dyspnea and fever. At the first admission, based on the findings in the lung computed tomography (CT) and a positive nasopharyngeal polymerase chain reaction (PCR) test for COVID-19, he was treated with intravenous remdesivir for 5 days and prophylactic anti-coagulant heparin during hospital admission. Two days before the new admission, he was discharged with relative recovery. During the new admission, because of the absence of hypoxemia and leukocytosis diagnostic approach to abdominal pain was planned. In abdominal imaging, evidence of bowel perforation appeared. In laparotomy, suppurative peritonitis and proximal jejunal perforation without definite etiology were seen, and bowel resection and primary anastomosis were done. After 5 days, the patient was discharged in good condition. This case is reported to inform that bowel perforation due to ischemia or vasculitis may complicate the course of COVID-19 and, in cases of gastrointestinal symptoms, should be considered.

KEYWORDS:

COVID-19, Intestine perforation, Peritonitis, Abdominal pain, Fever, Complication

Please cite this paper as:

Miroliaee A, Aletaha N, Ebrahimi Daryani N, Alborzi Avanaki F. Small intestine perforation in a 69-year-old man with covid-19. *Middle East J Dig Dis* 2022;14(2):265-267. doi: 10.34172/mejdd.2022.283.

INTRODUCTION

The coronavirus disease 2019 (COVID-19) is now a global pandemic with millions of people affected and millions more at risk for contracting the infection. The COVID-19 virus, severe acute respiratory syndrome coronavirus 2 (SARS-CoV-2), affects multiple organs, especially the lungs.¹

COVID-19 has extrapulmonary involvement, including smelling sensation, and neurological, cardiovascular, digestive, hepatobiliary, renal, endocrinologic, and dermatologic systems, among the others.²⁻⁴

Digestive symptoms, including anorexia, nausea, vomiting, and diarrhea, are not uncommon in patients with COVID-19, and in some cases, digestive symptoms may occur in the absence of any respiratory symptoms. Furthermore, SARS-CoV-2 could be detected in the stool of infected patients, implicating the possibility of fecal-oral transmission.

*Corresponding Author:

Najmeh Aletaha, MD
Department of Gastroenterology, Imam Khomeini Hospital, Tehran University of Medical Sciences, Tehran, Iran.
Telefax: + 98 21 66581650
Email: n-aletaha@sina.tums.ac.ir

Received : 09 Sep. 2021
Accepted : 15 Jan. 2022
Published: 30 Apr. 2022



© 2022 The Author(s). This work is published by Middle East Journal of Digestive Diseases as an open access article distributed under the terms of the Creative Commons Attribution License (<https://creativecommons.org/licenses/by-nc/4.0/>). Non-commercial uses of the work are permitted, provided the original work is properly cited.

Attention should also be paid to monitoring liver function during the course of COVID-19, especially in patients with higher disease severity.⁵⁻⁷

Although abdominal pain is one of the main gastrointestinal symptoms secondary to SARS-CoV-2 infection,⁶ attention to the acute abdomen and the need for surgery should be considered.

17.6% of patients with COVID-19 had gastrointestinal symptoms. Virus RNA was detected in stool samples of 48.1% of the patients, even in cases who had negative nasopharyngeal polymerase chain reaction (PCR) tests.^{8,9}

CASE REPORT

In May 2021, a 69-year-old man came to the emergency ward of Imam Khomeini hospital in Tehran, Iran, with complaints of fever and abdominal pain. He had been discharged 2 days earlier from the hospital after 5 days of treatment for COVID-19 with remdesivir & anti-coagulants. At discharge time, he had relative improvement but suffered from a slight stomachache. During the two days next, his abdominal pain became aggravated, and his temperature raised. Feeding accelerated pain and vomiting after that occurred in the disease course.

In the examination, he was febrile, and his body temperature was 38°C. Physical examination showed generalized abdominal tenderness, more severe in the right lower quadrant. There was a dullness in abdominal percussion.

He had a bowel habit the previous day and had stable vital signs. Main laboratory tests abnormality was 27400/cc leukocytosis with 85% polymorphonuclear, N-terminal pro b-type natriuretic peptide (NT-proBNP): 354 pg/mL, LDH: 995 U/L, and D-dimer: 6.23 mg/L.

Lung computed tomography (CT) showed ground glasses view and air-bronchogram, as of late COVID 19 appearance in both lungs (Figure 1). Abdominal ultrasonographic examination revealed incidental situs inversus and moderate ascites. Abdominal CT showed a proximal jejunal wall defect and 70 mm collection adjacent to it (Figure 2).

After an urgent surgical consult, the patient was operated on, and a jejunal perforation about 20 cm next to the ligament of Treitz was detected, and resection

and primary anastomosis were performed.

The pathology report mentioned: small intestine ischemic changes, focal perforation, acute transmural inflammation, and no evidence of vasculitis and thrombosis of large vessels (Figure 3).

The patient's post-surgical course was unremarkable, and 48 hours after surgery, he was afebrile, and leukocyte count decreased to 8500/mL. Five days later, he was discharged as he was on oral feeding and completely healthy.

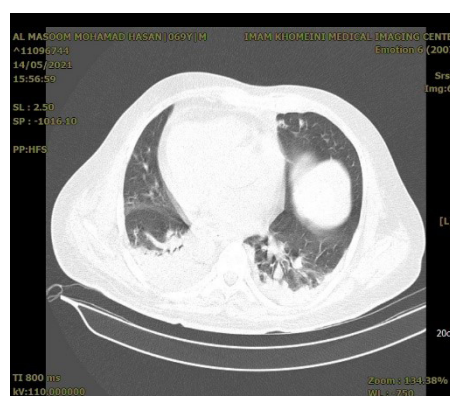


Fig. 1: Ground glass appearance and air-bronchogram in lung computed tomogram.

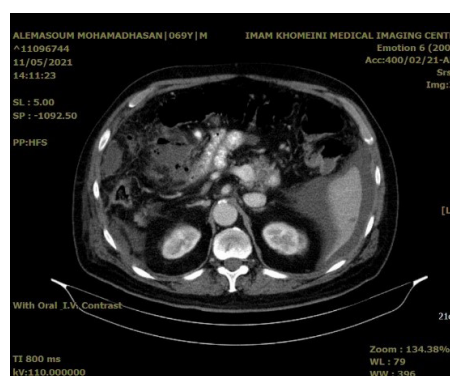


Fig. 2: Jejunal perforation and adjacent collection in abdominal computed tomogram.

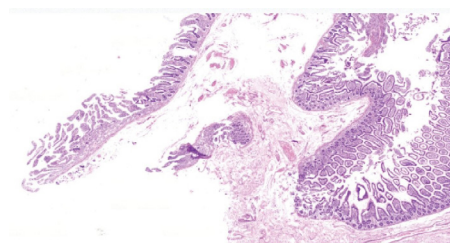


Fig. 3: Mucosal ulceration in pathological evaluation.

DISCUSSION

Our patient was admitted with a recent history of COVID 19 and was suspicious of having non-specific gastrointestinal symptoms. The clues for the approach to the acute abdomen, although the patient had no frank signs of peritonitis, were ascites and leukocytosis.

Some etiologies have been suggested that may affect the gastrointestinal tract in COVID-19 and cause perforation such as mesenteric vessels thrombosis, non-obstructing mesenteric ischemia, drug side effects, and/or vasculitis.^{9,10}

It is necessary to keep in mind that although many cases of abdominal pain have non-specific symptoms of a SARS CoV-2 infection and may be caused by the side effects of medications, rare cases of the acute abdomen should not be neglected.¹¹

Although our case improved completely and discharged with good condition, some of such cases may not have a good course, and the catastrophe may not stop after surgery and can be lethal.⁹

CONCLUSION

Especially in the presence of leukocytosis, metabolic acidosis, abnormal imaging findings, and vasoactive drugs requirement, a viscera perforation should be considered, although confirmation of the etiology is difficult.

Also, practitioners must keep in mind that widespread use of corticosteroids in COVID19 treatment may hide typical aspects of gut perforation.

ETHICAL APPROVAL

Informed consent was obtained from the parents of the patient for publication of this report .

CONFLICT OF INTEREST

The authors declare no conflict of interest related to this work.

REFERENCES

1. Bavishi C, Bonow RO, Trivedi V, Abbott JD, Messerli FH, Bhatt DL. Acute myocardial injury in patients hospitalized with COVID-19 infection: a review. *Prog Cardiovasc Dis* 2020;63(5):682-9. doi: [10.1016/j.pcad.2020.05.013](https://doi.org/10.1016/j.pcad.2020.05.013)
2. Tsai PH, Lai WY, Lin YY, Luo YH, Lin YT, Chen HK, et al. Clinical manifestation and disease progression in COVID-19 infection. *J Chin Med Assoc* 2021;84(1):3-8. doi: [10.1097/jcma.0000000000000463](https://doi.org/10.1097/jcma.0000000000000463)
3. Aletaha N, Taher M, Ebrahimi Daryani N, Miroliace A, Alborzi Avanaki F. Management of inflammatory bowel disease during COVID-19 pandemic. A practical review. *Govaresh* 2020;25(1):44-50.
4. Taher M, Miroliace A, Ebrahimi Daryani N, Alborzi Avanaki F, Aletaha N, Nasiri-Toosi M, et al. Management of patients with liver transplant and chronic liver diseases during COVID-19 pandemic: a brief review. *Arch Iran Med* 2020;23(10):713-7. doi: [10.34172/aim.2020.92](https://doi.org/10.34172/aim.2020.92)
5. Lee IC, Huo TI, Huang YH. Gastrointestinal and liver manifestations in patients with COVID-19. *J Chin Med Assoc* 2020;83(6):521-3. doi: [10.1097/jcma.0000000000000319](https://doi.org/10.1097/jcma.0000000000000319)
6. Cha MH, Regueiro M, Sandhu DS. Gastrointestinal and hepatic manifestations of COVID-19: a comprehensive review. *World J Gastroenterol* 2020;26(19):2323-32. doi: [10.3748/wjg.v26.i19.2323](https://doi.org/10.3748/wjg.v26.i19.2323)
7. Gu J, Han B, Wang J. COVID-19: gastrointestinal manifestations and potential fecal-oral transmission. *Gastroenterology* 2020;158(6):1518-9. doi: [10.1053/j.gastro.2020.02.054](https://doi.org/10.1053/j.gastro.2020.02.054)
8. Sierra-Arango F, Vergara-Cabra C, Vásquez-Roldan M, Pérez-Riveros ED. Acute surgical-like abdomen as a gastrointestinal manifestation of COVID-19 infection: a case report in Colombia. *BMC Gastroenterol* 2021;21(1):187. doi: [10.1186/s12876-021-01762-0](https://doi.org/10.1186/s12876-021-01762-0)
9. Cheung KS, Hung IFN, Chan PPY, Lung KC, Tso E, Liu R, et al. Gastrointestinal manifestations of SARS-CoV-2 infection and virus load in fecal samples from a Hong Kong cohort: systematic review and meta-analysis. *Gastroenterology* 2020;159(1):81-95. doi: [10.1053/j.gastro.2020.03.065](https://doi.org/10.1053/j.gastro.2020.03.065)
10. Zhong P, Xu J, Yang D, Shen Y, Wang L, Feng Y, et al. COVID-19-associated gastrointestinal and liver injury: clinical features and potential mechanisms. *Signal Transduct Target Ther* 2020;5(1):256. doi: [10.1038/s41392-020-00373-7](https://doi.org/10.1038/s41392-020-00373-7)
11. Corrêa Neto IJ, Viana KF, da Silva MB, da Silva LM, de Oliveira G, da Silva Cecchini AR, et al. Perforated acute abdomen in a patient with COVID-19: an atypical manifestation of the disease. *J Coloproctol (Rio J)* 2020;40(3):269-72. doi: [10.1016/j.jcol.2020.05.011](https://doi.org/10.1016/j.jcol.2020.05.011)