

# Sudden unilateral audiovestibular loss due to acute labyrinthine haemorrhage can be missed on early MRI brain sequences: case report

Patrick Harrison <sup>1,2</sup>, John Blazak,<sup>3</sup> Joshua Richmond,<sup>4</sup> Kristy Fraser-Kirk,<sup>5</sup> Aliese Hoffmann,<sup>6</sup> Grant Collins,<sup>7</sup> Benjamin K-T Tsang<sup>1,2</sup>

**To cite:** Harrison P, Blazak J, Richmond J, *et al*. Sudden unilateral audiovestibular loss due to acute labyrinthine haemorrhage can be missed on early MRI brain sequences: case report. *BMJ Neurology Open* 2024;**6**:e000563. doi:10.1136/bmjno-2023-000563

Accepted 19 November 2023

## ABSTRACT

**Background** Labyrinthine haemorrhage is a rare vascular disorder often presenting with the triad of acute vertigo, sudden sensorineural hearing loss and tinnitus. There are minimal reports on imaging progression over the acute period.

**Index case** A woman in her mid-40s presented with acute vertigo, sudden left-sided hearing loss and tinnitus, consistent with acute unilateral audiovestibular loss. Left peripheral vestibular hypofunction was confirmed acutely on video head impulse testing, and pure tone audiometry showed a profound left sensorineural hearing loss. An MRI brain including diffusion-weighted imaging within 24 hours was normal. Delayed MRI brain and internal acoustic canal after 7 days demonstrated increased 3D fluid-attenuated inversion recovery and T1 signal throughout the left cochlea and semicircular canals, without contrast enhancement. This was consistent with labyrinthine haemorrhage. She received early oral prednisone followed by three doses of intratympanic dexamethasone. At 12 months follow-up the patient remained profoundly deaf, however, balance and vestibular symptoms improved with early vestibular physical rehabilitation.

**Conclusion** We report a case of acute labyrinthine haemorrhage missed on an early MRI brain sequence. This diagnosis should be considered in presentations of acute audiovestibular loss, and delayed MRI including internal auditory canal sequences may be important for diagnosis.

## BACKGROUND

Labyrinthine haemorrhage is a rare but increasingly recognised vascular disorder. It often presents with the triad of acute vertigo, sudden sensorineural hearing loss (SSNHL) and tinnitus,<sup>1-3</sup> and can clinically mimic disorders such as vestibular labyrinthitis and ischaemic stroke. Less commonly it presents as isolated vertigo or hearing loss. It can occur both spontaneously and secondary to a number of causes, including coagulopathies, haematological malignancy and inflammatory disorders. While usually unilateral, bilateral cases have also been described, usually in the context of haematological disease.<sup>4</sup>

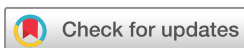The labyrinthine artery itself supplies blood to the inner ear. It traverses the internal auditory canal (IAC) before dividing into multiple branches supplying the cochlea, vestibule and semicircular canals.<sup>5</sup> It is an end artery with minimal collateral supply, and is consequently subject to both ischaemic and haemorrhagic insult.

Appropriate MRI timing and sequence is important for the diagnosis of labyrinthine haemorrhage. Herein, we report a case of spontaneous labyrinthine haemorrhage initially missed on an early MRI brain sequence.

## INDEX CASE

A woman in her mid-40s presented with sudden-onset vertigo and left-sided hearing loss with accompanying tinnitus. She had a history of migraine with aura as well as a distant background of head trauma and concussions. She denied aural fullness or neck pain, but later that day developed a severe holocephalic headache.

Beside neurological examination revealed a left-sided sensorineural hearing loss with an unsteady gait falling towards the left side. Otoscopy was unremarkable. There was a positive head impulse test towards the left side with a negative test of skew. Frenzel goggles later uncovered a downbeat nystagmus on rightward gaze. Video head impulse testing (vHIT) was consistent with left peripheral vestibular hypofunction (*figure 1*), and pure tone audiometry confirmed a profound left-sided sensorineural hearing loss. Otoacoustic emissions were absent in the left ear, while on tympanometry there was normal middle ear pressure and tympanic membrane mobility bilaterally. This was suggestive of left inner ear dysfunction.

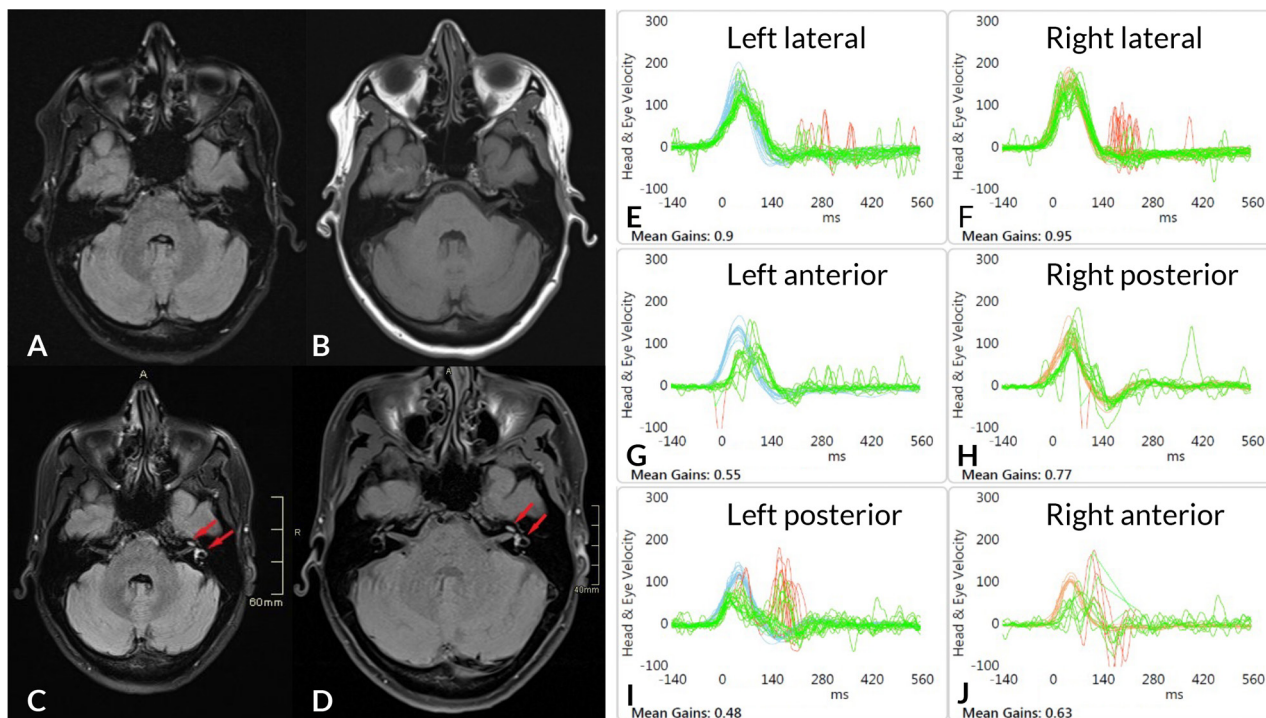


© Author(s) (or their employer(s)) 2024. Re-use permitted under CC BY-NC. No commercial re-use. See rights and permissions. Published by BMJ.

For numbered affiliations see end of article.

## Correspondence to

Dr Patrick Harrison; patrick.harrison@health.qld.gov.au



**Figure 1** MRI and video head impulse testing. (A, B) Early MRI brain <24 hours was normal, with no labyrinthine enhancement on either the fluid-attenuated inversion recovery (FLAIR) (A) or T1 non-contrast (B) sequences. (C, D) Delayed MRI brain and internal auditory canal (IAC) on day 7 demonstrates hyperintensity within the left cochlea and semicircular canals (red arrows) on brain FLAIR (C) and IAC T1 precontrast (D) sequences, consistent with labyrinthine haemorrhage. (E–J) Video head impulse testing demonstrating hypofunction of the left anterior (G) and posterior (I) semicircular canals with significantly reduced vestibular ocular reflex gains (ie, eye velocity (green) is slower than head velocity (blue) in the opposite direction). There are overt corrective saccades (red spikes) in the left posterior canal.

Both a CT head/neck angiogram and MRI brain including diffusion-weighted imaging within 24 hours were normal. She was initially loaded with aspirin and clopidogrel then treated presumptively for vestibular labyrinthitis with 10 days of oral prednisone (50 mg daily) and acyclovir (500 mg two times per day). Her vertigo and balance symptoms gradually improved over the next week, but hearing remained severely impaired.

An MRI brain and IAC after 7 days demonstrated increased signal of the left cochlea and semicircular canals on T1 and 3D fluid-attenuated inversion recovery (FLAIR) sequences, with no contrast enhancement (figure 1). A diagnosis of labyrinthine haemorrhage was now made. Despite self-reported easy bruising, epistaxis and menorrhagia, an extensive coagulopathy and vasculitic panel were unremarkable.

She was mobilising independently after 1 week, although headache burden and tinnitus habituation were slow to improve. Repeat vestibular testing at 3 weeks including vHIT indicated ongoing left vestibular dysfunction. Warm water caloric testing (corrected for spontaneous nystagmus) elicited no response in the left ear, and with ice stimulus there was only a residual response of 8 degrees/s, both consistent with left lateral canal hypofunction. Her subjective visual vertical was tilted 3.3 degrees to the left, a further indicator of unilateral vestibular dysfunction. Three doses of intratympanic

dexamethasone (4 mg in 1 mL) were administered within 4 weeks, however, at 12-month follow-up she remained profoundly deaf. She was considered a suitable candidate for a cochlear implant.

## DISCUSSION

MRI findings of labyrinthine haemorrhage are characterised by high signal in the ipsilateral labyrinthine structures in both precontrast T1-weighted images and FLAIR sequences, without subsequent contrast enhancement.<sup>16</sup> High T1 and FLAIR signal represents methaemoglobin and increased labyrinthine protein concentration, and accumulates between 3 and 14 days after haemorrhage.<sup>7,8</sup> Imaging outside this window should be interpreted with caution, particularly in the acute setting. In most series investigating SSNHL, MRI was performed at least 5 days after symptom onset.<sup>8</sup>

It should also be noted that early MRI can miss other vascular causes of acute vertigo. 15–20% of ischaemic strokes in the posterior fossa can be missed on MRI within 24 hours, and labyrinthine ischaemic stroke will be undetectable.<sup>9</sup> In cases of acute audiovestibular loss, delayed MRI should be considered.

It is critical to perform precontrast T1 imaging, as labyrinthine contrast enhancement can occur with a range of inflammatory and malignant pathology.<sup>10</sup> The most

common T1-enhancing pathologies are labyrinthitis and intralabyrinthine schwannoma.

There remains a lack of consensus guidelines for treatment of labyrinthine haemorrhage. Often guidelines for SSNHL are followed, typically involving oral corticosteroids followed by hyperbaric oxygen therapy and/or intratympanic corticosteroids.<sup>11</sup> Therapy for SSNHL should be promptly initiated, as the greatest benefit may be achieved within the first 1–2 weeks. The aetiology of labyrinthine haemorrhage should however be considered. In a case of isolated vertigo with labyrinthine haemorrhage secondary to cerebral venous thrombosis, warfarin was used to good clinical effect.<sup>12</sup>

Interestingly, there is a case report of a ruptured labyrinthine artery aneurysm managed with microsurgical clipping.<sup>13</sup> This presented as a subarachnoid haemorrhage, and there was no vertigo or hearing loss reported at any stage. Early surgical intervention may have prevented progression of haemorrhage into the labyrinth.

The prognosis of labyrinthine haemorrhage is often poor. While vestibular symptoms appear to improve with time and vestibular physiotherapy,<sup>1 12 14</sup> hearing loss is often profound and irreversible.<sup>1–3</sup> Nevertheless, there have been reports of complete hearing recovery.<sup>3</sup> Given relative preservation of inner hair cells and other cochlea structures, cochlear implants may provide an additional treatment option for these patients.<sup>15</sup>

In the index case, an early MRI brain failed to identify a labyrinthine haemorrhage. This was likely due to lack of methaemoglobin and protein accumulation in the hyperacute setting, as well as an imaging sequence non-specific for the inner ear. Fortunately, audiovestibular testing supported impaired inner ear function, and a delayed MRI IAC was ultimately obtained. While it has previously been recommended to obtain MRI as early as feasible in cases of suspected labyrinthine haemorrhage,<sup>3</sup> caution should be exercised when interpreting early brain-specific scans.

Although we did demonstrate new high labyrinthine signal on the delayed MRI brain, dedicated IAC sequences should be obtained to not miss subtle inner ear pathology. A limitation of our report is that we did not obtain these dedicated sequences during the initial MRI. While it is difficult to tease out the individual benefit of delayed imaging versus dedicated protocol for the inner ear, our lack of early findings is consistent with the expected MRI evolution of intracranial haemorrhage.

We also cannot exclude an early labyrinthine ischaemic stroke that underwent haemorrhagic transformation. This would be undetectable on MRI, and present similarly to labyrinthine haemorrhage. There were however no additional features of an anterior inferior cerebellar artery or other posterior circulation infarction on delayed MRI.

Labyrinthine haemorrhage can be diagnostically challenging, and clinicians should be aware that the timing and specific sequence of MRI is an important factor in diagnosis. In presentations of acute audiovestibular loss, a delayed MRI of the IAC should be carefully considered.

#### Author affiliations

<sup>1</sup>Department of Neurology, Sunshine Coast University Hospital, Sunshine Coast, Queensland, Australia

<sup>2</sup>School of Medicine and Dentistry, Griffith University, Sunshine Coast, Queensland, Australia

<sup>3</sup>Department of Radiology, Sunshine Coast University Hospital, Sunshine Coast, Queensland, Australia

<sup>4</sup>Department of Haematology, Sunshine Coast University Hospital, Sunshine Coast, Queensland, Australia

<sup>5</sup>Department of Ear, Nose and Throat Surgery, Sunshine Coast University Hospital, Sunshine Coast, Queensland, Australia

<sup>6</sup>Department of Physiotherapy, Sunshine Coast University Hospital, Sunshine Coast, Queensland, Australia

<sup>7</sup>Queensland Vestibular Cochlear Clinic, Sunshine Coast, Queensland, Australia

**Acknowledgements** We acknowledge Professor Michael Halmagyi for his review of an early manuscript of this paper.

**Contributors** PH drafted the manuscript, revised with BT and GC. PH, JB, GC, AH and BT contributed to figure production. JB, JR, KF-K, AH, GC and BT were involved in the management and diagnosis of the index case. All authors read and approved the final manuscript. PH is responsible for the overall content as guarantor.

**Funding** The authors have not declared a specific grant for this research from any funding agency in the public, commercial or not-for-profit sectors.

**Competing interests** None declared.

**Patient consent for publication** Obtained.

**Provenance and peer review** Not commissioned; externally peer reviewed.

**Data availability statement** Data are available upon reasonable request.

**Open access** This is an open access article distributed in accordance with the Creative Commons Attribution Non Commercial (CC BY-NC 4.0) license, which permits others to distribute, remix, adapt, build upon this work non-commercially, and license their derivative works on different terms, provided the original work is properly cited, appropriate credit is given, any changes made indicated, and the use is non-commercial. See: <http://creativecommons.org/licenses/by-nc/4.0/>.

#### ORCID iD

Patrick Harrison <http://orcid.org/0000-0001-7018-8940>

#### REFERENCES

- 1 Wu X, Chen K, Sun L, *et al*. Magnetic resonance imaging-detected inner ear hemorrhage as a potential cause of sudden Sensorineural hearing loss. *Am J Otolaryngol* 2014;35:318–23.
- 2 Vivas EX, Panella NJ, Bagnon KL. Spontaneous Labyrinthine hemorrhage: A case series. *Otolaryngol Head Neck Surg* 2018;159:908–13.
- 3 Chen X-H, Zeng C-J, Fang Z-M, *et al*. The natural history of Labyrinthine hemorrhage in patients with sudden Sensorineural hearing loss. *Ear Nose Throat J* 2019;98:E13–20.
- 4 Meunier A, Clavel P, Aubry K, *et al*. A sudden bilateral hearing loss caused by inner ear hemorrhage. *Eur Ann Otorhinolaryngol Head Neck Dis* 2020;137:65–7.
- 5 Mei X, Atturo F, Wadin K, *et al*. Human inner ear blood supply Revisited: the Uppsala collection of temporal bone—an international resource of education and collaboration. *Ups J Med Sci* 2018;123:131–42.
- 6 Kim DS, Park DW, Kim TY, *et al*. Characteristic MR findings suggesting presumed Labyrinthine hemorrhage. *Acta Otolaryngol* 2017;137:1226–32.
- 7 Bradley WG. MR appearance of hemorrhage in the brain. *Radiology* 1993;189:15–26.
- 8 Lammers MJW, Young E, Fenton D, *et al*. The Prognostic value and pathophysiological significance of Three-Dimensional Fluid-Attenuated inversion recovery (3D-FLAIR) magnetic resonance imaging in idiopathic sudden Sensorineural hearing loss: A systematic review and Meta-Analysis. *Clin Otolaryngol* 2019;44:1017–25.
- 9 Saber Tehrani AS, Kattah JC, Kerber KA, *et al*. Diagnosing stroke in acute dizziness and vertigo: pitfalls and pearls. *Stroke* 2018;49:788–95.
- 10 Dubrulle F, Kohler R, Vincent C, *et al*. Differential diagnosis and prognosis of T1-weighted post-Gadolinium Intralabyrinthine Hyperintensities. *Eur Radiol* 2010;20:2628–36.



- 11 Chandrasekhar SS, Tsai Do BS, Schwartz SR, *et al.* Clinical practice guideline: sudden hearing loss (update). *Otolaryngol Head Neck Surg* 2019;161(1\_suppl):S1–45.
- 12 Martins AI, Figueiredo C, Melancia D, *et al.* Labyrinthine haemorrhage secondary to cerebral venous thrombosis. *Eur J Neurol* 2021;28:4258–60.
- 13 Gross BA, Frerichs KU, Du R. Microsurgical treatment of a ruptured Dissecting Labyrinthine artery aneurysm. *Clin Neurol Neurosurg* 2013;115:2277–9.
- 14 Araújo-Martins J, Melo P, Ribeiro C, *et al.* Recovery of cochlear and vestibular function after Labyrinthine haemorrhage. *Acta Med Port* 2014;27:649–51.
- 15 Kaya S, Hizli Ö, Schachern PA, *et al.* Effects of Intralabyrinthine hemorrhage on the cochlear elements: A human temporal bone study. *Otol Neurotol* 2016;37:132–6.