

High-flow Nasal Cannula-induced Tension Pneumocephalus

Youjin Chang¹, Tae-Gyu Kim², Sun-Yoon Chung³

ABSTRACT

High-flow nasal cannula (HFNC) therapy has been established as a promising oxygen treatment with various advantages for respiratory mechanics. One of the main mechanisms is to provide positive airway pressure. This effect could reduce lung injury and improve oxygenation; conversely, it may cause a complication of positive pressure ventilation. However, data are scarce regarding the possible adverse effects, particularly in adults. We report a patient who developed HFNC-induced tension pneumocephalus from an unrecognized skull base fracture. Physicians should be cautious when applying HFNC to patients with suspected skull base or paranasal sinus fracture, especially when applying a higher flow rate.

Keywords: Complications, High-flow oxygen therapy, High-flow nasal cannula, Pneumocephalus, Positive-pressure respiration.

Indian Journal of Critical Care Medicine (2020): 10.5005/jp-journals-10071-23482

BACKGROUND

High-flow nasal cannula oxygen therapy (HFNC) has recently been widely used in adults. Previous studies¹⁻³ have demonstrated its beneficial effects, including avoiding mechanical ventilation (MV) for acute hypoxemic respiratory failure and preventing postextubation respiratory failure. One of the main mechanisms of HFNC is that it provides positive airway pressure,⁴ thus leading to enhanced dynamic compliance, reduced opening/closing injury and diaphragmatic loading, and/or improvement of ventilation/perfusion mismatch. This effect could facilitate reduced lung injury and improved oxygenation; conversely, it may cause a complication of positive pressure ventilation. However, data are scarce regarding the possible adverse effects of HFNC in relation to positive pressure ventilation, particularly in adults; these data have not been previously reported in the literature. Tension pneumocephalus is a neurosurgical emergency caused by accumulation of air, leading to increased intracranial pressure;⁵ it is an uncommon complication of positive pressure ventilation. Here, we report a patient who developed HFNC-induced tension pneumocephalus from an unrecognized skull base fracture.

CASE DESCRIPTION

A 69-year-old man was admitted to a medical intensive care unit in a teaching hospital with a 3 day history of cough and sputum, accompanied by the onset of fever and drowsy mental status. He had a history of traumatic intracranial, epidural, and subdural hemorrhage, due to an accidental fall 7 months prior. He had undergone right craniectomy and was placed a ventriculoperitoneal (VP) shunt, due to posttraumatic hydrocephalus. Four months prior to hospital admission, he underwent intensive rehabilitation treatment. He was able to communicate with others in a basic manner, walk with a walker, and feed himself. Recently, 1 week prior to admission, he became drowsy after ingesting an antipsychotic medication used to treat his aggressive behaviors. During this episode of drowsiness, he experienced an aspiration event while eating. Subsequently, he developed respiratory symptoms and exhibited deteriorating mental status.

Upon admission, chest radiography showed a focal infiltrate at the patient's left lower lung field and chest computed tomography (CT) demonstrated consolidation with air bronchogram at the left

¹Division of Pulmonary and Critical Care Medicine, Department of Internal Medicine, Inje University College of Medicine, Sanggye Paik Hospital, Seoul, Republic of Korea

²Department of Radiology, Inje University College of Medicine, Sanggye Paik Hospital, Seoul, Republic of Korea

³Department of Neurosurgery, Inje University College of Medicine, Sanggye Paik Hospital, Seoul, Republic of Korea

Corresponding Author: Sun-Yoon Chung, Department of Neurosurgery, Inje University College of Medicine, Sanggye Paik Hospital, Seoul, Republic of Korea, Phone: +82 2 950 1035, e-mail: s5530@paik.ac.kr

How to cite this article: Chang Y, Kim T-G, Chung S-Y. High-flow Nasal Cannula-induced Tension Pneumocephalus. *Indian J Crit Care Med* 2020;24(7):592-595.

Source of support: Nil

Conflict of interest: None

lower lobe (LLL) posterior basal segment, as well as suspected aspirated materials at the left upper lobe bronchus and LLL segmental bronchus (Fig. 1). These observations were accompanied by the appearance of food particles in his esophagus, suggesting that his pneumonia was aspiration-induced. For the evaluation of his drowsy mentality, the patient underwent a brain CT scan, which demonstrated no notable findings, except his previously inserted VP shunt and focal encephalomalacic changes in the right frontal lobe. We thus determined that his mental change was due to pneumonia-induced sepsis.

The patient's initial oxygen partial pressure (PaO₂) and oxygen saturation (SaO₂) were 43.9 mm Hg and 79.4% on 5 L/minute oxygen via nasal cannula, respectively; his initial respiratory rate (RR) was 24 breaths/minute, and his respiration did not appear uncomfortable. He underwent high-flow nasal oxygen therapy with a fraction of inspired oxygen (FiO₂) of 0.5, with a flow of 50 L/minute, followed by gradually increasing flow to 60 L/minute and decreasing FiO₂ to 0.4. His SpO₂ was maintained at 93-97%, and his RR was 22-26 breaths/minute, with a comfortable respiration. However, during the following 24 hours, the patient developed repeated sudden desaturation; he then underwent endotracheal intubation and MV. His desaturation was considered due to airway secretion. Two days later, the patient underwent attempted weaning from MV.

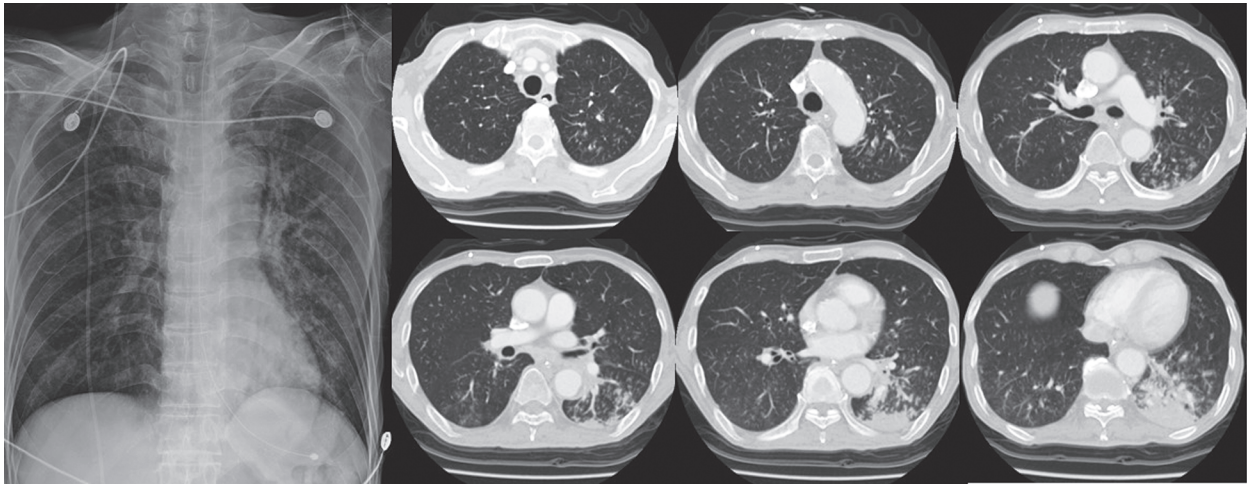


Fig. 1: Initial chest radiography (left) and chest CT (right). A consolidation with air bronchograms at left lower lobe with suspected aspirated materials at left upper and lower lobar bronchus

He was unable to effectively expectorate his airway secretions, but the volume of secretions greatly decreased and he achieved an alert mental status. Then, he was extubated and again underwent HFNC to prevent postextubation respiratory failure. His HFNC was maintained at an FiO_2 of 0.4 and flow of 50 L/minute, with an SpO_2 of 93–100%. Twenty-four hours later, he was transferred to the general ward. Then, the setting of HFNC was changed to a flow of 40 L/minute with an FiO_2 of 0.4.

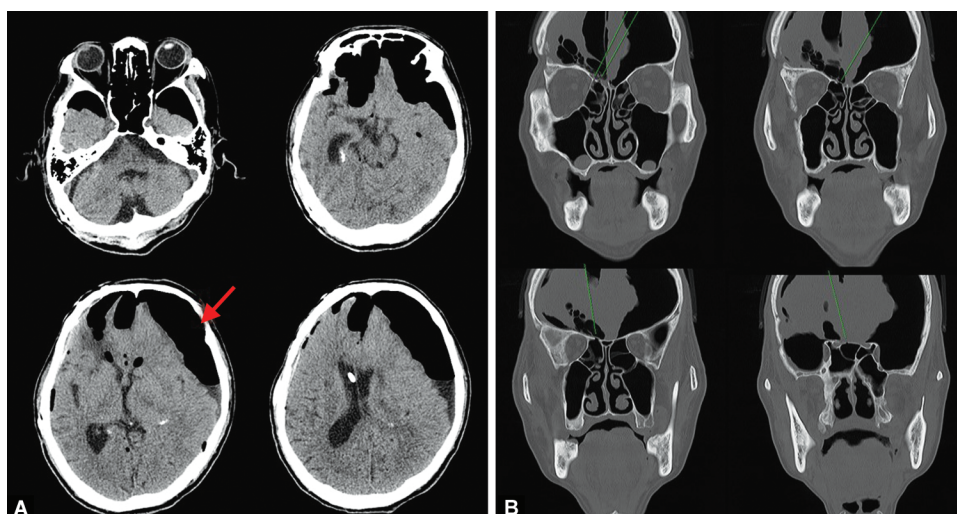
On the second day at the general ward, 28 hours after discharge from ICU, the patient's mentation became drowsy and he finally declined into a state of stupor. He underwent an additional brain CT scan, which demonstrated newly apparent pneumocephalus with midline shifting and near-collapse of the left ventricle, accompanied by a Mount Fuji sign; this was indicative of tension pneumocephalus (Fig. 2A). His HFNC was stopped and changed to a simple nasal cannula. A follow-up brain CT scan, 12 hours later, indicated that his pneumocephalus had slightly decreased. To determine the source of the pneumocephalus, the patient also underwent a facial bone CT scan, which suggested skull base fractures located at the right frontal and ethmoidal sinuses (Fig. 2B). These CT findings implied that positive pressure was applied into the intracranial space via these openings. Thus, we suspected that the patient's postextubation HFNC caused positive pressure ventilation, which led to pneumocephalus through the skull base fractures from his previous trauma. The openings of the fractures might have served as a pressure valve, facilitating the onset of tension pneumocephalus. His mental status gradually improved from stupor to drowsy, without specific treatment. After 1 week, a follow-up brain CT showed markedly decreased pneumocephalus and improved midline shifting and left ventricle structure (Fig. 3A). Notably, the patient's pneumocephalus nearly resolved after 20 days (Fig. 3B). However, he continued to experience difficulties in expectorating his airway secretions and finally underwent tracheostomy. His mental status improved and was maintained for the following 40 days. Then, he experienced a sudden decline in mental status, returning to a state of stupor. Unfortunately, he had developed an intracranial infection, which was likely caused by intracranial fluid collection where the pneumocephalus had permitted communication with paranasal sinuses. The patient

eventually underwent craniotomy for drainage; however, his mental status did not fully recover.

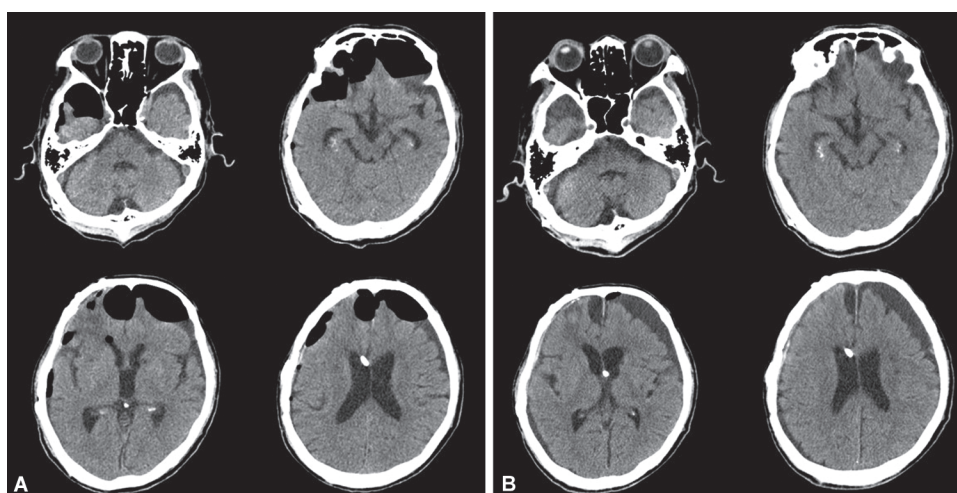
DISCUSSION AND CONCLUSION

This case demonstrated that HFNC-induced tension pneumocephalus in a patient with a previous traumatic skull base fracture. This is the first such case report in an adult patient, which highlights the need for consideration of the current common use of HFNC. High-flow oxygen therapy rapidly has become a new and effective oxygen delivery system, providing heated and humidified high-flow oxygen. Its ease of application has made it commonly used worldwide. However, thus far, its contraindications and complications are not known yet in adults. Our case may provide an important precedent for performing more careful application of HFNC and assessment of its safety in adults.

Pneumocephalus is defined as the presence of gas within any of the intracranial compartments of the cranial vault. It is typically associated with disruption of the skull after head and facial trauma⁶ and can result in a life-threatening condition, such as tension pneumocephalus. In some cases, positive pressure ventilation can lead to pneumocephalus. The first reported case was published in 1979;⁷ in that case, pneumocephalus was induced by the use of an oxygen-powered resuscitator with a face mask, in a patient suspected of skull fracture. Continuous positive airway pressure via nasal or facial mask also led to pneumocephalus in adult patients with facial trauma or unrecognized skull base fracture, respectively.^{8,9} Further, positive mask ventilation resulted in pneumocephalus during induction of anesthesia or rapid sequence intubation in adults with head trauma.^{10–12} Notably, brief usage of mouth to mouth ventilation during resuscitation caused pneumocephalus in a patient with a paranasal sinus fracture. Literature search results demonstrate that, in adult patients, all cases of pneumocephalus related to positive pressure ventilation have been associated with a history of head trauma. Tension pneumocephalus was reported in only one case, caused by bag-mask ventilation in a patient with a skull base fracture.¹³ However, thus far, there has been no report of pneumocephalus related to HFNC in adults. In contrast, in pediatric patients, even in cases with no evidence of head trauma or skull fracture, HFNC therapy has been



Figs 2A and B: Initial brain CT images: (A) His initial brain CT image shows the Mount Fuji sign indicative of tension pneumocephalus (left); (B) Previously unrecognized skull base fractures located at the right frontal and ethmoidal sinuses (right)



Figs 3A and B: His subsequent brain CT images: (A) Significantly improved tension pneumocephalus one week after stopping high-flow nasal cannula (left); (B) Completely resolved pneumocephalus after 20 days (right)

shown to induce pneumocephalus;^{14,15} this included the occurrence of tension pneumocephalus in a neonate.¹⁶ These reports suggested that although there was no definite bony defect, pneumocephalus may have developed through an open communication in more fragile areas of the skull base.¹⁶ As a result, in pediatric patients, even lower levels of positive pressure delivered by HFNC made an air leak to the intracranial space via their inherent fragile bone crack, whereas in adult patients, it is difficult to occur if their skull base would be intact. The present case demonstrated that if the skull base fracture existed, the lower level of positive pressure used in HFNC could lead to life-threatening tension pneumocephalus. It suggests caution regarding the current rapidly increasing use of HFNC worldwide as an effective respiratory support device.

The optimal flow rate of HFNC therapy is not yet definitely known; it is recommended to set the flow rate depending on the patient's flow and oxygen demand and severity of respiratory distress.¹⁷ An oxygen flow of HFNC ≥ 30 L/minute typically provides positive airway pressure;¹⁸ with greater flow, FiO_2 is increasingly augmented, up to 60 L/minute.¹⁷ Our patient underwent

relatively high flows of 40–60 L/minute during his admission and postextubation periods, although these were set according to his respiratory demand. He did not exhibit mouth-opening breath; thus, he was estimated to receive positive airway pressure from 2 cm H_2O to maximal 5 cm H_2O .¹⁹ These levels of pressure likely induced the "ball-valve mechanism" in his unrecognized skull base fracture. Interestingly, the possibility of HFNC therapy as a treatment for perioperative pneumocephalus was recently reported.²⁰ In that report, 3 patients who exhibited postoperative pneumocephalus underwent lower levels of flow rate, such as 20–30 L/minute and high FiO_2 of 1.0. Although these patients had definite postoperative skull defects, no complications of positive pressure ventilation occurred. Rather, the patients experienced beneficial effects, in that their postoperative pneumocephalus was absorbed sooner than expected. It is possible that the lower flow setting of HFNC was not sufficient to generate enough positive pressure to worsen their existing pneumocephalus. Thus, they were able to use higher FiO_2 and flow, which enabled their pneumocephalus to be removed faster than might have been achieved with the conventional oxygen

delivery system. Thus, proper control of flow rate may be the most critical aspect of proper use of HFNC, when applying the technique to patients with suspected or confirmed skull base fracture.

In conclusion, HFNC therapy has been established as a beneficial and promising oxygen treatment with various advantages for respiratory mechanics. Its extent of use and indications will continue to expand. However, in adults, physicians should be cautious when applying HFNC to patients with suspected skull base or paranasal sinus fracture, especially when applying a higher flow rate. Although tension pneumocephalus is a rare complication of positive pressure ventilation, it could be a life-threatening condition; thus, close observation should be required for newly developed neurologic symptoms or signs in patients with a history of head trauma. Data regarding possible adverse effects related to the use of HFNC should be consistently gathered, which may ultimately facilitate the establishment of practice guidelines for the proper application of HFNC therapy.

CLINICAL SIGNIFICANCE

This is the first report of high-flow nasal cannula therapy-related tension pneumocephalus which highlights the risk of using the new high-flow oxygen therapy in adult patients who have a history of head trauma.

CONSENT TO PUBLICATION

We obtained consent to publish from the legal surrogate of the patient to report the patient data. This report was written after the patient died.

ETHICS APPROVAL AND CONSENT TO PARTICIPATE

The Inje University Sanggye Paik Hospital Institutional Review Board approved this study (study number 2020-01-011) and waived the need for informed consent. This report had no impact on patient treatment.

REFERENCES

1. Frat JP, Thille AW, Mercat A, Girault C, Ragot S, Perbet S, et al. High-flow oxygen through nasal cannula in acute hypoxemic respiratory failure. *N Engl J Med* 2015;372(23):2185–2196. DOI: 10.1056/NEJMoa1503326.
2. Hernandez G, Vaquero C, Colinas L, Cuenca R, Gonzalez P, Canabal A, et al. Effect of postextubation high-flow nasal cannula vs noninvasive ventilation on reintubation and postextubation respiratory failure in high-risk patients: a Randomized clinical trial. *JAMA* 2016;316(15):1565–1574. DOI: 10.1001/jama.2016.14194.
3. Hernandez G, Vaquero C, Gonzalez P, Subira C, Frutos-Vivar F, Rialp G, et al. Effect of postextubation high-flow nasal cannula vs conventional oxygen therapy on reintubation in low-risk patients: a randomized clinical trial. *JAMA* 2016;315(13):1354–1361. DOI: 10.1001/jama.2016.2711.
4. Goligher EC, Slutsky AS. Not just oxygen? Mechanisms of benefit from high-flow nasal cannula in hypoxemic respiratory failure. *Am J Respir Crit Care Med* 2017;195(9):1128–1131. DOI: 10.1164/rccm.201701-0006ED.
5. Pulickal GG, Sitoh YY, Ng WH. Tension pneumocephalus. *Singapore Med J* 2014;55(3):e46–e48. DOI: 10.11622/smedj.2014041.
6. Schirmer CM, Heilman CB, Bhardwaj A. Pneumocephalus: case illustrations and review. *Neurocrit Care* 2010;13(1):152–158. DOI: 10.1007/s12028-010-9363-0.
7. Paradis IL, Caldwell EJ. Traumatic pneumocephalus: a hazard of resuscitators. *J Trauma* 1979;19(1):61–63. DOI: 10.1097/00005373-197901000-00012.
8. Klopfenstein CE, Forster A, Suter PM. Pneumocephalus. A complication of continuous positive airway pressure after trauma. *Chest* 1980;78(4):656–657. DOI: 10.1378/chest.78.4.656.
9. Jarjour NN, Wilson P. Pneumocephalus associated with nasal continuous positive airway pressure in a patient with sleep apnea syndrome. *Chest* 1989;96(6):1425–1426. DOI: 10.1378/chest.96.6.1425.
10. Moon HS, Lee SK, Chung SH, Chung JH, Chang IB. Recurred pneumocephalus in a head trauma patient following positive pressure mask ventilation during induction of anesthesia: a case report. *Korean J Anesthesiol* 2010;59(Suppl):S183–S186. DOI: 10.4097/kjae.2010.59.S.S183.
11. Nicholson B, Dhindsa H. Traumatic tension pneumocephalus after blunt head trauma and positive pressure ventilation. *Prehosp Emerg Care* 2010;14(4):499–504. DOI: 10.3109/10903120903564522.
12. Gurajala I, Azharuddin M, Gopinath R. General anesthesia with laryngeal mask airway may cause recurrence of pneumocephalus in a patient with head injury. *Br J Anaesth* 2013;111(4):675–676. DOI: 10.1093/bja/aet316.
13. Youngblood SC, Baig HR. Images in anesthesiology: pneumocephalus resulting from basilar skull fracture. *Anesthesiology* 2015;122(5):1152. DOI: 10.1097/ALN.0000000000000339.
14. Jasin LR, Kern S, Thompson S, Walter C, Rone JM, Yohannan MD. Subcutaneous scalp emphysema, pneumo-orbitis and pneumocephalus in a neonate on high humidity high flow nasal cannula. *J Perinatol* 2008;28(11):779–781. DOI: 10.1038/jp.2008.99.
15. O'Brien BJ, Rosenfeld JV, Elder JE. Tension pneumo-orbitis and pneumocephalus induced by a nasal oxygen cannula: report on two paediatric cases. *J Paediatr Child Health* 2000;36(5):511–514. DOI: 10.1046/j.1440-1754.2000.00550.x.
16. Iglesias-Deus A, Perez-Munuzuri A, Lopez-Suarez O, Crespo P, Couce ML. Tension pneumocephalus induced by high-flow nasal cannula ventilation in a neonate. *Arch Dis Child Fetal Neonatal Ed* 2017;102(2):F173–F175. DOI: 10.1136/archdischild-2015-309777.
17. Papazian L, Corley A, Hess D, Fraser JF, Frat JP, Guitton C, et al. Use of high-flow nasal cannula oxygenation in ICU adults: a narrative review. *Intensive Care Med* 2016;42(9):1336–1349. DOI: 10.1007/s00134-016-4277-8.
18. Chanques G, Riboulet F, Molinari N, Carr J, Jung B, Prades A, et al. Comparison of three high flow oxygen therapy delivery devices: a clinical physiological cross-over study. *Minerva Anesthesiol* 2013;79(12):1344–1355.
19. Spoletini G, Alotaibi M, Blasi F, Hill NS. Heated humidified high-flow nasal oxygen in adults: mechanisms of action and clinical implications. *Chest* 2015;148(1):253–261. DOI: 10.1378/chest.14-2871.
20. Siegel JL, Hampton K, Rabinstein AA, McLaughlin D, Diaz-Gomez JL. Oxygen therapy with high-flow nasal cannula as an effective treatment for perioperative pneumocephalus: case illustrations and pathophysiological review. *Neurocrit Care* 2017.