



Received: 2014.08.27  
Accepted: 2014.10.23  
Published: 2015.02.04

**Authors' Contribution:**

- A** Study Design
- B** Data Collection
- C** Statistical Analysis
- D** Data Interpretation
- E** Manuscript Preparation
- F** Literature Search
- G** Funds Collection

## Toxic Lung Injury in a Patient Addicted to “Legal Highs” – Case Study

Dorota Kulhawik<sup>1</sup>, Jerzy Walecki<sup>2</sup>

<sup>1</sup> Department of Radiology, Mazovian Center for Treatment of Lung Diseases and Tuberculosis in Otwock, Otwock, Poland  
<sup>2</sup> Department of Radiology and Diagnostic Imaging, Independent Public Clinical Hospital, Otwock, Poland

**Author's address:** Dorota Kulhawik, Mazovian Center for Treatment of Lung Diseases and Tuberculosis in Otwock, Narutowicza 80 Str., 05-400 Otwock, Poland, e-mail: dot\_am@o2.pl

### Summary

<b>Background:</b>	Toxic lung injury may manifest itself in many different ways, ranging from respiratory tract irritation and pulmonary edema in severe cases to constrictive bronchiolitis, being a more distant consequence.  It is most often the result of accidental exposure to harmful substances at work, at home, or a consequence of industrial disaster.
<b>Case Report:</b>	This article presents a case of toxic lung injury which occurred after inhalation of legal highs, the so-called “artificial hashish” and at first presented itself radiologically as interstitial pneumonia with pleural effusion and clinically as hypoxemic respiratory insufficiency. After treatment with high doses of steroids, it was histopathologically diagnosed as organizing pneumonia with lipid bodies.
<b>Conclusions:</b>	Due to the lack of pathognomonic radiological images for toxic lung injury, information on possible etiology of irritants is very important. As novel psychoactive substances appeared in Europe, they should be considered as the cause of toxic lung injury.
<b>MeSH Keywords:</b>	<b>Drugs • Lung Diseases, Interstitial • Lung Injury • Radiography • Respiratory Insufficiency</b>
<b>PDF file:</b>	<a href="http://www.polradiol.com/abstract/index/idArt/892334">http://www.polradiol.com/abstract/index/idArt/892334</a>

### Background

Legal highs – various products containing new psychoactive substances and hallucinogenic substances of plant origin reached Poland about 7 years ago. Chains of “smart shops”, i.e. shops selling psychoactive substances, have been operating in the European Union countries since 2005. They constitute a new and serious medical, social and legal problem.

One of the objectives of a program called the EU Drugs Strategy 2013–2020 is to combat threats connected with new psychoactive substances, for example, by strengthening the current EU legislation. New psychoactive substances, which imitate the effects of drugs, appear and rapidly spread throughout the EU.

At present, there is little information on the harmful impact of novel psychoactive substances on the human

body. The data are mostly based on the analysis of these substances whose consumption caused severe damage to human health or even death [1].

The article features the case of a patient addicted to psychoactive substances (including legal highs) with toxic lung injury, which occurred after inhalation of these substances.

The goal of this article was to raise the awareness among doctors with regard to a new potential source of toxic lung injury in Europe and to show that the “legal highs” present threat for health.

### Case Report

Following a 4-day stay at the detox ward, a 20-year-old patient with a 5-year-long addiction to marijuana, a history of nicotine and alcohol dependence, inhaling the so-called artificial hashish for 6 months was admitted to

the lung disease department in serious condition with a suspected miliary tuberculosis. On admission, the physical examination demonstrated single bilateral rhonchi and rales over the lung fields, tachypnea, general cyanosis, and saturation of 65–72%. The patient reported catarrh lasting for 6 months; cough lasting 4 months, which was stronger for a week and a half preceding admission to hospital, 4 days of fever, diarrhea and dyspnea at rest. The patient denied hemoptysis or contact with tuberculosis.

Laboratory tests showed hypoxemic respiratory insufficiency, high titres of CRP, LDH, d-dimers, and NT-pro-BNP. Infection with HIV and HBV was excluded.

Oxygen therapy with 6 L/min of Encorton at a dose of 1 mg/kg body weight p.o., Clexane s.c. and antimycobacterial drugs were used.

Imaging examinations were ordered.

Chest X-ray showed diffuse, confluent interstitial changes of the highest intensity in the middle and inferior fields, and trace of pleural effusion. Besides, the image was unremarkable.

First HRCT showed massive generalized shading with air bronchogram in the middle and inferior fields, heterogeneous patchy changes in the superior fields. Complicated interstitial pneumonia with little pleural effusion was suggested.

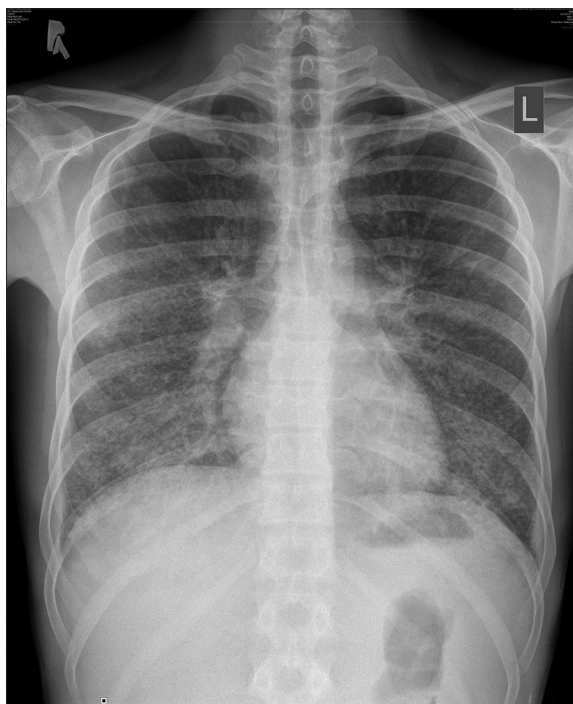
Bronchofiberoscopy showed features of active inflammation of the bronchial tree.

Only *Candida albicans* was grown from cultures from bronchial washings; specific, non-specific flora and atypical pathogens (*Bordetella pertussis*, *Legionella pneumophila*, *Mycoplasma pneumoniae*, *Pneumocystis jiroveci*) cultures – negative.

Fluconazole p.o. was added to the above-mentioned therapy, which caused gradual clinical improvement.

A control chest HRCT performed after 3 weeks revealed normal cavities, mediastinum and pleura, disseminated confluent small nodules of varying degrees of saturation, local frosted glass-like changes, which in the inferior fields coalesced with nodules of the central part of the pulmonary lobule and thickened interlobular septa. The whole image suggested toxic lung injury to differentiate with *P. jiroveci* infection.

After five weeks spent in the department, initial clinical improvement and reduced oxygen therapy to 3 L/min, spirometry with diastolic test was performed. The first examination result showed a decrease in VC to 84%, FEV1 89%, FEV 1%, VC 105% of due value. In the second test after administering Berotec: VC 82%, FEV1 94%, FEV 1%, VC 113% of due value. Basing on the results there was a suspicion of restriction. Due to insufficient co-operation with the patient, plethysmography confirming the diagnosis was not performed.



**Figure 1.** First X-ray - diffuse confluent interstitial changes of the highest intensity in the middle and inferior fields, trace of pleural effusion; besides, the image unremarkable.

In the histopathological examination (material obtained from open biopsy), the image corresponded to organizing pneumonia with lipid bodies in the organizing lesions; lesions most likely caused by inhaling irritants. A biopsied mediastinal lymph node – reactive (Figures 1–4).

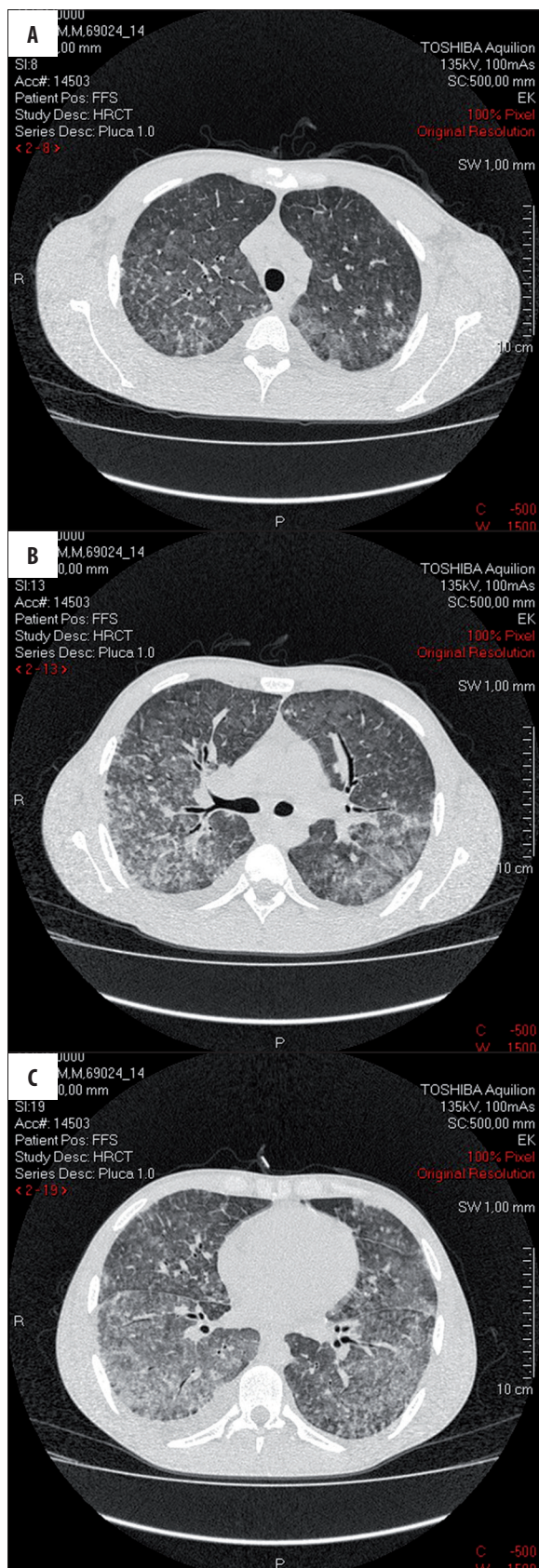
## Discussion

Acute or subacute chemically-induced lung injury is most often caused by accidental inhalation of chemical agent at work, at home or as a consequence of industrial or environmental disaster [2]. There is a wide spectrum of lung disease complications after administering drugs such as cocaine and its derivatives, especially crack; methamphetamine derivatives, including methylphenidate hydrochloride (Ritalin; Novartis, East Hanover, NJ); opiates such as heroin and methadone, among others; and mixtures of these agents. Furthermore, substances that are commonly mixed with an illicit drug, known as “fillers”, may be primarily responsible for the disease. Fillers include talc, cornstarch, and cellulose [3,4].

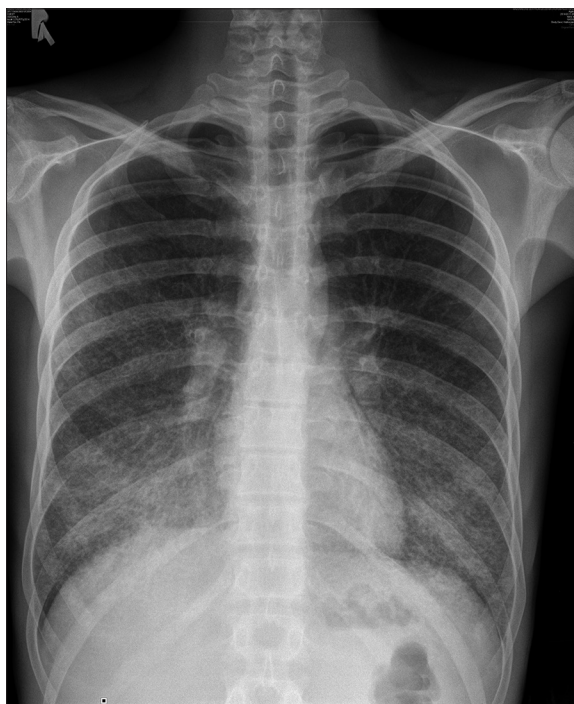
Early in the assessment process it is essential to determine the most probable factor, the length and frequency of exposure, which can be achieved by careful examination of a patient’s medical history or witnesses’ observations.

Toxic lung injury may manifest itself in many different ways and the extent of changes caused by inhaling toxic substances depends on their physicochemical properties and the degree of exposure [5,6].

Chemically-induced lung injury includes bronchitis, bronchiolitis, pulmonary edema, ARDS, organizing pneumonia,



**Figure 2. (A–C) First HRCT – interstitial pneumonia, air bronchogram, pleural effusion.**



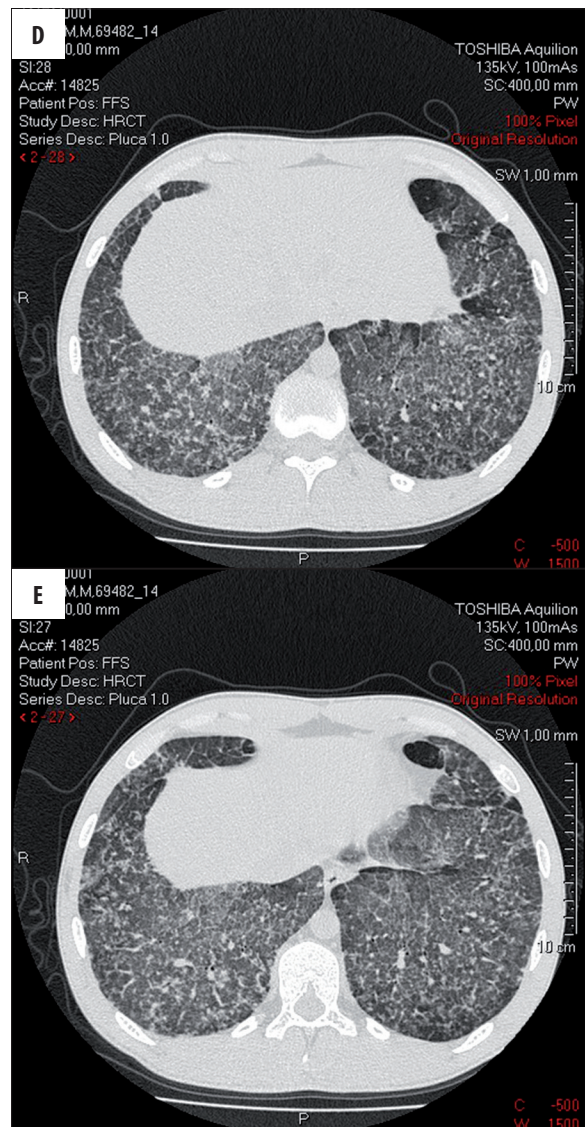
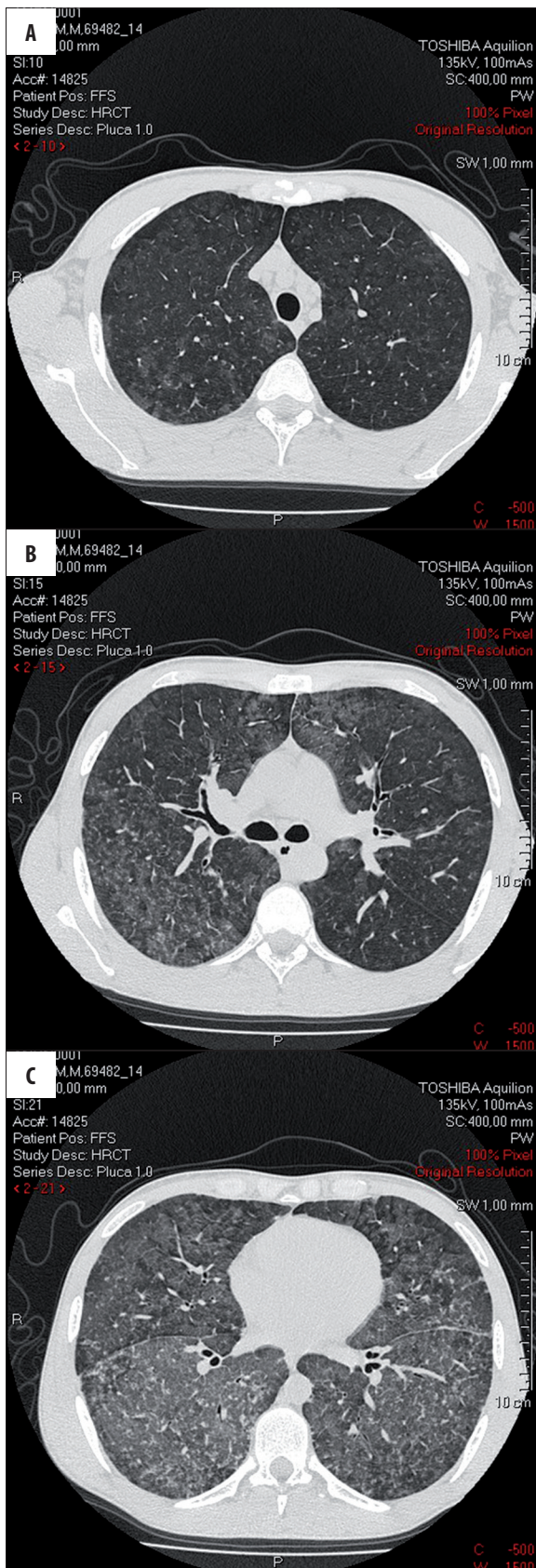
**Figure 3. Control X-ray – regression of pleural effusion, interstitial changes in the superior fields less severe than in the first examination.**

acute eosinophilic pneumonia, hypersensitivity pneumonitis and sarcoid-like granulomatous lung disease [7].

Respiratory complications of drug abuse may involve the upper airways, lungs, and pleura and include pneumonia, pulmonary edema, pulmonary hemorrhage, drug-induced granulomatosis, emphysema, and pneumothorax [3,4,8]. Repeated intravenous injections of various drugs designed for oral intake can lead to severe complications such as pulmonary hypertension or toxic interstitial lung disease [9].

The first symptoms in acute exposure are irritation of the upper respiratory tract and bronchitis. Laryngeal edema and bronchospasm may lead to death. Pulmonary edema [5] in the mechanism of alveolar-capillary barrier damage may occur within the first 48 hours [10]. Superinfection is a common complication in the following days. Potential long-term consequences are bronchial hyperreactivity and constrictive bronchiolitis [5]. Organization, characterized by fibroblast proliferation, is a common and nearly universal response to lung injury whether it is focal or diffuse. Despite the vast range of injurious agents, the lung's response to injury is quite limited, with a similar pattern of reaction seen radiologically and histologically regardless of the underlying cause [11].

In the case of smoke inhalation, early radiological signs in chest X-ray include perihilar bronchial wall thickening and subglottic swelling, frequently – pulmonary edema. Chest radiogram, which is a first-line study, is often enough to evaluate the extent of damage and to monitor the disease [12].



**Figure 4. (A–E)** Control HRCT – normal cavities, mediastinum and pleura, disseminated confluent small nodules of varying degrees of saturation, local frosted glass-like changes, which in the inferior fields coalesced with nodules of the central part of the pulmonary lobule and thickened interlobular septa.

lesions were found in the microscopic examination, which pointed to the concomitance of lipid pneumonia.

Lipid pneumonia is a rare pulmonary disease. It results from damage to the lung parenchyma by lipid molecules originating from the serum (endogenous form) or entering the lung by aspiration or inhalation (exogenous form) [13–16].

Endogenous lipid pneumonia most often occurs below a closed bronchus due to a lung tumor [17]. It results from the influx of macrophages accumulating fat coming from alveolar type II epithelial cells. It is also called cholesterol pneumonia due to a significant amount of cholesterol in phagocytes [18,19]. Type II cells produce a surfactant – phospholipid substance regulating the surface tension

In our case, interstitial changes prevailed in the radiological examination. However, lipid bodies in the organizing

of the alveoli and thus co-responsible for stabilizing gas in the terminal part of the respiratory system. Pulmonary surfactant is the most sensitive and dynamically changing substance under the influence of various factors damaging pulmonary alveoli [17].

Pathomorphological changes in the exogenous lipid pneumonia are chronic and proliferative. In the microscopic examination, lipid bodies are encapsulated by connective tissue containing macrophages [18].

Factors responsible for exogenous lipid pneumonia are varied – mineral oil, petroleum jelly, fish liver oil, oily nose drops, full milk, egg yolk, kerosene, gasoline blend, industrial lubricants, oil, buffalo butter [20].

In adult population, they are most commonly diagnosed in fire-eaters [21] but they may result from occupational exposure to mixtures of oil in manufacturing of steel and

furniture, in aviation and – non-occupational exposure – in people using lipstick or lip gloss, people using aerosol substances to apply on joints or spraying hair and people who smoke tobacco with oily additives [13]. Aspiration of volatile organic compounds such as amyl and butyl nitrites (commonly known as “poppers”) during attempted inhalation of vapors may lead to the development of lipid pneumonia [8]. Due to insufficient information on composition and manner of ingestion of novel psychoactive substances, lipid pneumonia should be taken into consideration in people addicted to legal highs.

## Conclusions

Due to the lack of pathognomonic radiological images for toxic lung injury, information on possible etiology of irritants is very important. As novel psychoactive substances appeared in Europe, they should be considered as the cause of toxic lung injury.

## References:

1. Raport Głównego Inspektora Sanitarnego w sprawie środków zastępczych – trzy lata zwalczania dopalaczy w Polsce <http://www.gis.gov.pl/ckfinder/userfiles/files/Srodki%20zastepcze/raport2013.pdf> [in Polish]
2. Andujar P, Nemery B: [Acute and subacute chemical pneumonitis.] *Rev Mal Respir*, 2009; 26(8): 867–85 [in French]
3. Gotway MB, Marder SR, Hanks DK et al: Thoracic complications of illicit drug use: an organ system approach. *Radiographics*, 2002; 22 Spec No: S119–35
4. Mégarbane B, Chevillard L: The large spectrum of pulmonary complications following illicit drug use: features and mechanisms. *Chem Biol Interact*, 2013; 206(3): 444–51
5. Garnier R: [Acute toxic pneumopathies.] *Rev Prat*, 1998; 48(12): 1319–23 [in French]
6. Weiss SM, Lakshminarayan S: Acute inhalation injury. *Clin Chest Med*, 1994; 15(1): 103–16
7. Akira M, Suganuma N: Acute and subacute chemical-induced lung injuries: HRCT findings. *Eur J Radiol*, 2014; 83(8): 1461–69
8. Ian GH, Kashif B: Radiology of Recreational Drug Abuse, RSNA Education Exhibits, presented as an education exhibit at the 2005 RSNA Annual Meeting
9. Mayaud C, Boussaud V, Saidi F et al: Bronchopulmonary disease in drug abusers. *Rev Pneumol Clin*, 2001; 57(4): 259–69
10. Wąsowicz M, Biczysko W, Drwiła R: [Effect of exogenous surfactant on alveolar barrier. An experimental study.] *Anestezjologia Intensywna Terapija*, 2002; 2: 76–80 [in Polish]
11. Kligerman SJ, Franks TJ, Galvin JG: From the Radiologic Pathology Archives: Organization and fibrosis as a response to lung injury in diffuse alveolar damage, organizing pneumonia, and acute fibrinous and organizing pneumonia. *Radiographics*, 2013; 33(7): 1951–75
12. Lee MJ, O'Connell DJ: The plain chest radiograph after acute smoke inhalation. *Clin Radiol*, 1988; 39(1): 33–37
13. Adkins D, Bensadoun ES: An 85-year-old man with a lung mass. *Chest*, 2004; 125: 1121–23
14. Barta Z, Szabo GG, Bruckner G, Szegedi G: Endogenous lipid pneumonia associated with undifferentiated connective tissue disease (UCTD). *Med Sci Monit*, 2001, 7(1): 134–36
15. Wright BA, Jeffrey PH: Lipoid pneumonia. *Semin Respir Infect*, 1990; 5: 314–21
16. Zaleska J, Ptaszek B, Malong P et al: Lipoid pneumonia in patients after laryngectomy. *Otolaryngol Pol*, 2007; 61(6): 1004–10
17. Tamura A, Hebisawa A, Fukushima K et al: Lipoid pneumonia in lung cancer: radiographic and pathological features. *Jpn J Clin Oncol*, 1998; 28: 492–96
18. Betancourt SL, Martinez – Jimenez S et al.: Lipoid Pneumonia: Spectrum of Clinical and Radiologic Manifestations *AJR* 2010; 194: 103-9
19. Robbins LL, Sniffen C: Correlation Between the roentgenologic and pathologic findings in chronic pneumonitis of the cholesterol type. *Radiology*, 1949; 53(2): 187–202
20. Krychniak-Soszka A, Lewandowska K, Skorupa W et al: [Exogenous lipid pneumonia – a report of four cases.] *Pneumonol Alergol Pol*, 2005; 73(2): 182–88 [in Polish]
21. Pielaszkiwicz-Wydra M, Homola-Piekarska B, Szcześniak E et al: Exogenous lipid pneumonia – a case report of a fire-eater. *Pol J Radiol*, 2012; 77(4): 60–64