

Reduced specific force in patients with mild and severe facioscapulohumeral muscular dystrophy

Saskia Lassche MD¹ | Nicol C Voermans MD PhD¹ | Tim Schreuder PhD¹ |
Arend Heerschap PhD² | Benno Küsters MD PhD³ | Coen AC Ottenheijm PhD⁴ |
Maria TE Hopman MD PhD⁵ | Baziel GM van Engelen MD PhD¹

¹Department of Neurology, Donders Institute for Brain, Cognition and Behaviour, Radboud University Medical Center, Nijmegen, The Netherlands

²Department of Radiology, Radboud University Medical Center, Nijmegen, The Netherlands

³Department of Pathology, Radboud University Medical Center, Nijmegen, The Netherlands

⁴Department of Physiology, Institute for Cardiovascular Research, Amsterdam University Medical Center, Amsterdam, The Netherlands

⁵Department of Physiology, Radboud University Medical Center, Nijmegen, The Netherlands

Correspondence

Saskia Lassche, Department of Neurology, Donders Institute for Brain, Cognition and Behaviour, Radboud university medical center, PO Box 9101, 6500 HB Nijmegen, The Netherlands.

Email: saskia.lassche@radboudumc.nl

Funding information

Prinses Beatrix Spierfonds; Stichting Spieren voor Spieren

Abstract

Background: Specific force, that is the amount of force generated per unit of muscle tissue, is reduced in patients with facioscapulohumeral muscular dystrophy (FSHD). The causes of reduced specific force and its relation with FSHD disease severity are unknown.

Methods: Quantitative muscle magnetic resonance imaging (MRI), measurement of voluntary maximum force generation and quadriceps force-frequency relationship, and vastus lateralis muscle biopsies were performed in 12 genetically confirmed patients with FSHD and 12 controls.

Results: Specific force was reduced by ~33% in all FSHD patients independent of disease severity. Quadriceps force-frequency relationship shifted to the right in severe FSHD compared to controls. Fiber type distribution in vastus lateralis muscle biopsies did not differ between groups.

Conclusions: Reduced quadriceps specific force is present in all FSHD patients regardless of disease severity or fatty infiltration. Early myopathic changes, including fibrosis, and non-muscle factors, such as physical fatigue and musculoskeletal pain, may contribute to reduced specific force.

KEYWORDS

facioscapulohumeral muscular dystrophy, fibrosis, histopathology, MRI, muscle weakness, specific force

1 | INTRODUCTION

Facioscapulohumeral muscular dystrophy (FSHD) is one of the most common hereditary muscle disorders.¹ In FSHD, the amount of

muscle available for force generation is reduced due to fatty infiltration, fibrosis and fiber atrophy, resulting in reduced muscle strength.²⁻⁹ Another contributing factor to muscle weakness is impairment of specific force, that is the amount of force generated per unit

Abbreviations: 6MWT, 6-Minute Walk Test; ANOVA, analysis of variance; ASIS, anterior superior iliac spine; BMI, body mass index; CSS, Clinical Severity Scale; CCSA, contractile cross-sectional area; FCSA, fat infiltrated cross-sectional area; FOV, field of view; FSHD, facioscapulohumeral muscular dystrophy; HPhlox, hematoxylin-phloxine; MFm, Motor Function Measure; MRC, Medical Research Council; MRI, magnetic resonance imaging; MVC, maximum voluntary contraction; TCSA, total cross-sectional area; TE, echo time; TR, repetition time; TIRM, turbo inversion recovery magnitude.

This is an open access article under the terms of the Creative Commons Attribution-NonCommercial-NoDerivs License, which permits use and distribution in any medium, provided the original work is properly cited, the use is non-commercial and no modifications or adaptations are made.

© 2020 The Authors. Muscle & Nerve published by Wiley Periodicals LLC.

of residual muscle tissue. Specific force has been shown to be reduced in FSHD as well as in other muscle disorders, such as Duchenne and Becker muscular dystrophy.^{6,10-12} The exact mechanisms that result in reduced specific force in FSHD are unknown.

Previous studies have shown that specific force is reduced in patients with FSHD. However, one study did not include radiological assessment of muscle volume to correct for fatty infiltration.¹² Another study was limited by the use of different force measurement devices and magnetic resonance imaging (MRI) protocols in the patient and control groups.⁶ Furthermore, previous studies did not assess specific force in patients with mild disease. Hence, it is unclear whether reduced specific force is an early feature of FSHD pathology or a late consequence of atrophy and fatty infiltration. If specific force is affected early in the FSHD disease course, this may influence the use of outcome measures in clinical trials. Therefore, we investigated specific force and its relation to disease severity in the quadriceps of FSHD patients and controls.

2 | METHODS

2.1 | Participants

Genetically confirmed FSHD patients were recruited from the Radboud University Medical Center. Healthy individuals without a history of neuromuscular disease, mostly spouses and peers of FSHD participants, were included as controls. Genetic testing was performed to exclude FSHD in controls who were related to FSHD patients. Exclusion criteria were: age < 18 or ≥ 65 y, diabetes mellitus, chronic obstructive pulmonary disease, chronic heart failure, current malignancy, previous treatment with chemotherapy and/or radiation therapy, use of corticosteroids during more than 2 wk in the past 5 y, current use of statins, wheelchair bound, contra-indications for MRI or muscle biopsy. Age matching was applied at the group level, resulting in an adjustment of the lower age limit to 40 y during patient recruitment. FSHD disease severity was assessed using the Ricci Clinical Severity Scale (CSS).¹³ CSS scores <5 reflect mild-to-moderate disease that is limited to the face and shoulder girdle, without pelvic or lower limb weakness. Scores ≥5 reflect more severe disease with pelvic girdle and/or lower limb weakness. To demonstrate differences associated with mild and severe disease, we grouped patients with CSS scores <5 (mild to moderate FSHD; described in the subsequent text and figures as “mild FSHD”) and patients with CSS scores ≥5 (severe FSHD). The Medical Ethics Review Committee region Arnhem-Nijmegen approved this study (no. 2011/181). Informed consent was obtained from all participants.

2.2 | Functional evaluation

Muscle strength was graded with the Medical Research Council (MRC) scale. Functional performance was assessed using the 6-Minute Walk Test (6MWT) and Motor Function Measure (MFM), a validated

quantitative scale which measures the functional abilities of a person affected with neuromuscular disease.^{14,15} Physical activity was measured using an actometer, a motion sensing device worn around the ankle for 14 d.¹⁶ The first and last day of recording were discarded, leaving 12 complete days for analysis of physical activity. Pain was assessed with the Dutch version of the McGill Pain Questionnaire.¹⁷

2.3 | Quantitative imaging

Transverse T1 weighted and multi-echo T2 images of the upper and lower leg were acquired on a 3T MRI system (Tim TRIO, Siemens, Erlangen, Germany).¹⁸ A fish-oil marker was placed at about one-third of the distance between anterior superior iliac spine (ASIS) and patella to mark the prospective muscle biopsy site and to be able to measure quadriceps cross-sectional area at a consistent level across all participants (Supporting Information Figure S1, which is available online). Scout images were acquired in three orthogonal directions for accurate positioning of the MRI slices, centered on the fish-oil marker. Eight transverse slices (field of view [FOV] 175x175 mm², thickness 4 mm, gap 6 mm, base resolution 256) were acquired with a T2 multi spin echo sequence (repetition time [TR], 3000 ms; 16 equally spaced echo times [TEs], 7.7–123.2 ms). Next 23 transverse slices (thickness 4 mm, gap 0.4 mm) were obtained with a T1 turbo spin echo sequence (FOV, 250x244.5 mm²; TR/TE, 600 ms/13 ms; base resolution, 448).

T1 images were used to determine the anatomical border of severely fat infiltrated muscles. Total cross-sectional area (TCSA; cm²), muscle fraction and fat fraction were quantified from the multi-echo T2 images at the level of the fish-oil marker.¹⁹ TCSA was determined by manually tracing the outline of individual muscles or muscle groups using ImageJ. Muscle and fat fraction were quantified using the method described by Kan.¹⁹ We used TCSA, muscle fraction and fat fraction to calculate the relative contribution of lean muscle (contractile cross-sectional area: CCSA; cm²) and fatty infiltration (fat infiltrated cross-sectional area: FCSA; cm²) to the quadriceps TCSA. All muscle biopsies and MRI scans were performed in the right leg, except in the presence of asymmetrical weakness, in which case the weakest leg was biopsied.

2.4 | Quantitative force studies

2.4.1 | Maximum voluntary contractile strength

Maximum voluntary contraction (MVC) of the quadriceps was measured in the right leg, except in the presence of asymmetrical weakness in which case the weakest leg was chosen (Supporting Information Figure S2). MVC was measured on a fixed quadriceps dynamometer, with the hip angle in 90° and the knee angle set at 120°. Participants were strapped at the hips and upper body to prevent compensatory movements. Participants were asked to perform an isometric MVC during 3 s, mean force from three contractions was used to represent MVC.²⁰

2.4.2 | Contractile properties

After a 5-min resting period, electrical pulses were administered through two self-adhesive surface electrodes placed proximally over the rectus femoris and distally over the vastus medialis portion of the

quadriceps muscle.²¹ A 100 Hz electrical current was applied to contract the quadriceps at 30% of the MVC. After another 5-min resting period, six 1-s bursts ranging from 1 Hz to 100 Hz were applied to determine the force-frequency relationship. The force-frequency relationship shows the amount of force generated in response to

	Control	Mild FSHD	Severe FSHD	<i>p</i>
Age (y)	53.8 ± 1.7	52.6 ± 2.9	54.1 ± 1.4	.888
Sex (male %)	50.0	60.0	28.6	.515
BMI (kg/m ²)	27.3 ± 1.5	24.2 ± 1.0	26.1 ± 1.9	.470
CSS (median [range])	N/A	3 (2–4)	6 (6–8)	<.001
Disease duration (y)	N/A	20.2 ± 5.2	35.0 ± 4.0	.045
D4Z4 repeat (units) ^a	N/A	7.8 ± 0.9	7.7 ± 0.3	.9132

^aMean for five participants with mild FSHD1 and three participants with severe FSHD1.

TABLE 1 Participants

TABLE 2 FSHD participants and muscle biopsies

Clinical features			Quadriceps				Vastus lateralis	
Sex	Age (y)	CSS	MRC	MRI fat (%)	MVC (N)	Specific force (N/cm ²)	MRI fat (%)	Histology sum score
Controls								
M	44	N/A	5	5	590	19.3	2	3
M	50	N/A	5	9	630	21.7	8	1
M	50	N/A	5	4	440	13.9	1	1
F	51	N/A	5	9	630	27.8	3	0
F	51	N/A	5	7	545	31.1	3	1
F	52	N/A	5	– ^a	325	– ^a	– ^a	0
F	53	N/A	5	2	410	21.3	9	1
M	53	N/A	5	4	880	27.0	4	1
M	57	N/A	5	8	800	23.0	8	2
M	58	N/A	5	4	800	25.1	3	1
F	62	N/A	5	25	350	20.3	26	2
F	65	N/A	5	8	465	23.6	5	1
Mild FSHD								
M	52	2	5	8	510	16.1	9	4
M	59	2	5	4	425	16.5	5	1
F	44	3	5	9	385	18.6	8	3
F	59	3	5	8	245	12.3	2	3
M	49	4	5	3	300	13.2	2	1
Severe FSHD								
F	48	6	4.5	8	155	9.6	10	4
F	57	6	5	17	75	4.3	21	2
M	61	6	4.5	83	84	21.1	61	– ^b
M	56	6	5	24	435	20.1	12	3
F	52	7	5	41	300	20.6	39	6
F	49	8	2.5	87	43	17.5	92	11
F	56	8	4	15	200	16.4	3	4

^aMRI scanning not performed due to claustrophobia.

^bInsufficient material for histopathological analysis.

electrical stimulation at different frequencies, and is affected by fiber type distribution.^{21,22}

2.5 | Muscle biopsies

Bergstrom needle biopsies of the vastus lateralis were performed at the level of the fish oil capsule. In controls, an incision was made ~5 cm from the site of the fish-oil marker. Needle depth and angle were monitored to reach the approximate level of the fish-oil marker without imaging guidance. In FSHD patients, MRI guidance was used to confirm the position of the needle prior to muscle biopsy.²³ Frozen sections underwent hematoxylin-phloxine (HPhlox) staining to evaluate variability in fiber size, extent of central nucleation, necrosis and/or regeneration, and interstitial fibrosis, which were graded as normal (0), mild (1), moderate (2) or severe (3). Severity scores of these four parameters were then added to provide a cumulative histopathological sum score between 0 and 12.²⁴ All scores were assigned by an experienced neuropathologist (B.K.) who was unaware whether the biopsy belonged to the FSHD or control group.

2.6 | Statistics

Statistical analysis was performed with IBM SPSS Statistics 22 (Armonk, NY, USA). Continuous data were analyzed using one-way analysis of variance (ANOVA) with post-hoc comparisons using

Bonferroni's correction for multiple comparisons. Ordinal data were analyzed using chi-squared test. Correlations were analyzed using Pearson's correlation coefficient. Data are reported as mean ± SEM or median ± IQR unless otherwise specified.

3 | RESULTS

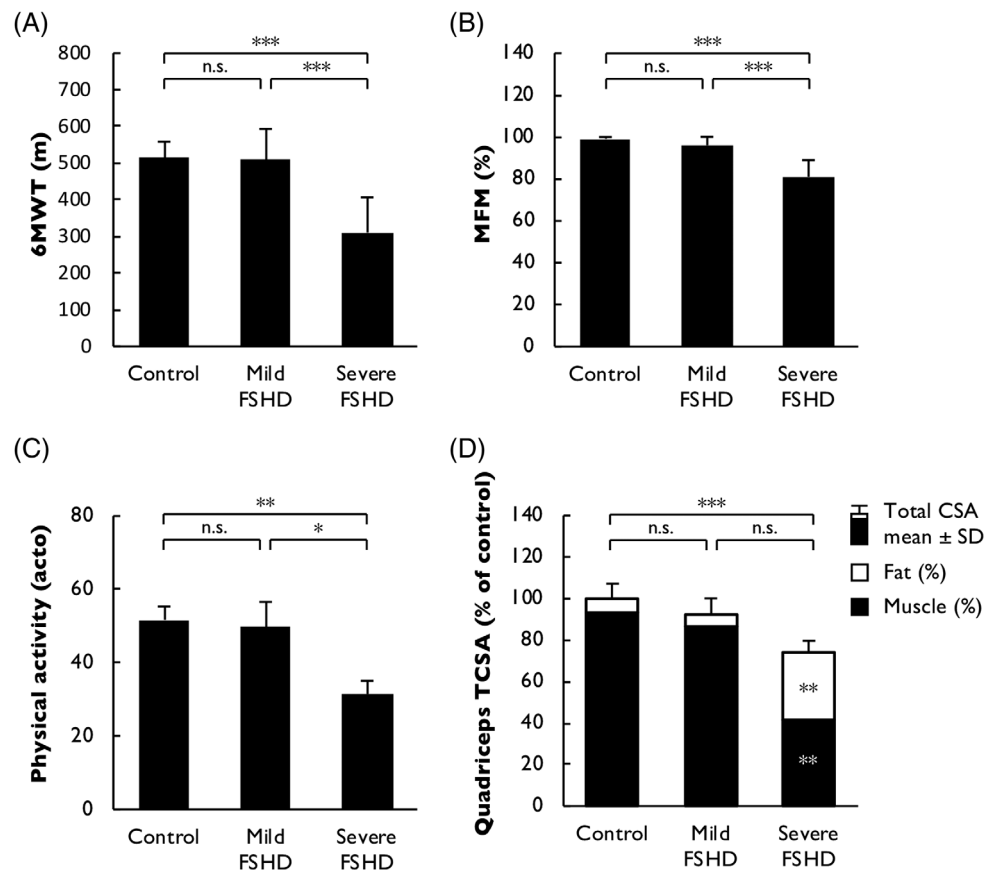
3.1 | Participants

We included 12 FSHD patients with varying degrees of disease severity and 12 controls. Five patients had a CSS of 2–4 and were classified as mild FSHD, and seven patients had a CSS of 6–8 and were classified as severe FSHD. FSHD subgroups and control participants did not differ in age, sex distribution, or body mass index (BMI) (Table 1). All participants with mild FSHD and three participants with severe FSHD had FSHD1. Of the other four severe FSHD patients, one was mosaic with a two-unit D4Z4 repeat in 65% of leukocytes, and three had FSHD2 due to a SMCHD1 mutation. An overview of all FSHD participants is provided in Table 2.

3.2 | Functional performance

6MWT, MFM, and daily physical activity level were normal in patients with mild FSHD, whereas patients with severe FSHD had reduced walking distance, reduced performance on the MFM, and reduced

FIGURE 1 Functional performance and quantitative imaging. A, Walking distance on the 6MWT was preserved in patients with mild FSHD and reduced in patients with severe FSHD. B, Functional performance measured by the MFM was preserved in patients with mild FSHD and reduced in patients with severe FSHD. C, Daily physical activity was preserved in patients with mild FSHD and reduced in patients with severe FSHD. D, Normal muscle size and no fatty infiltration in patients with mild FSHD, whereas patients with severe FSHD display quadriceps atrophy (significantly reduced TCSA compared to controls) and increased fatty infiltration (significantly increased FCSA compared to controls and mild FSHD), resulting in reduced CCSA (significantly reduced compared controls and mild FSHD). $P < .05$ is considered significant, * $P < .05$, ** $P < .01$, *** $P < .001$



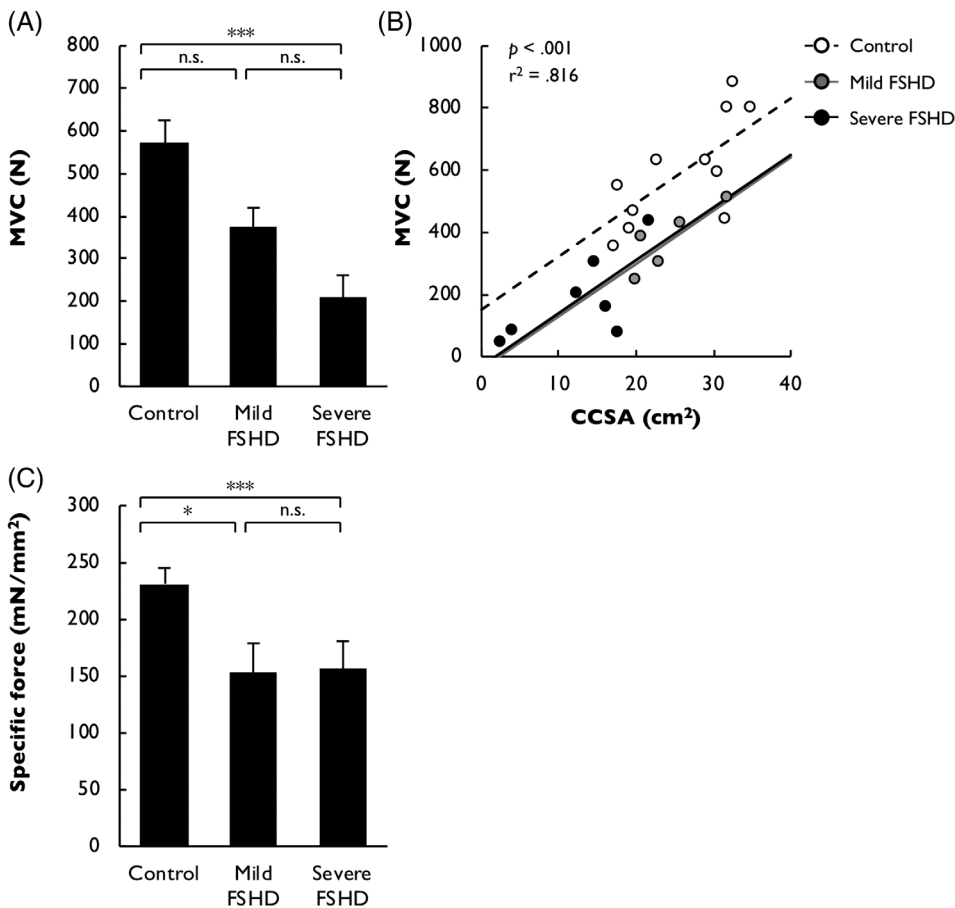


FIGURE 2 Reduced specific force in patients with mild and severe FSHD. A, MVC is significantly reduced in severe FSHD. B, Quadriceps CCSA correlates significantly with MVC. Specific force (MVC/CCSA) is reduced in all FSHD patients, independent of disease severity. This results in a ~ 33% reduction in specific force in FSHD patients compared to healthy controls (mild FSHD: 34%, severe FSHD: 32%, C). $P < .05$ is considered significant, * $P < .05$, ** $P < .01$, *** $P < .001$

daily physical activity level compared to controls and patients with mild FSHD (Figure 1A-C). Mild lower back and pelvic pain were

reported more frequently in patients with severe FSHD (8.3% of controls with a mean pain score of 1/10; 40% of mild FSHD with a mean

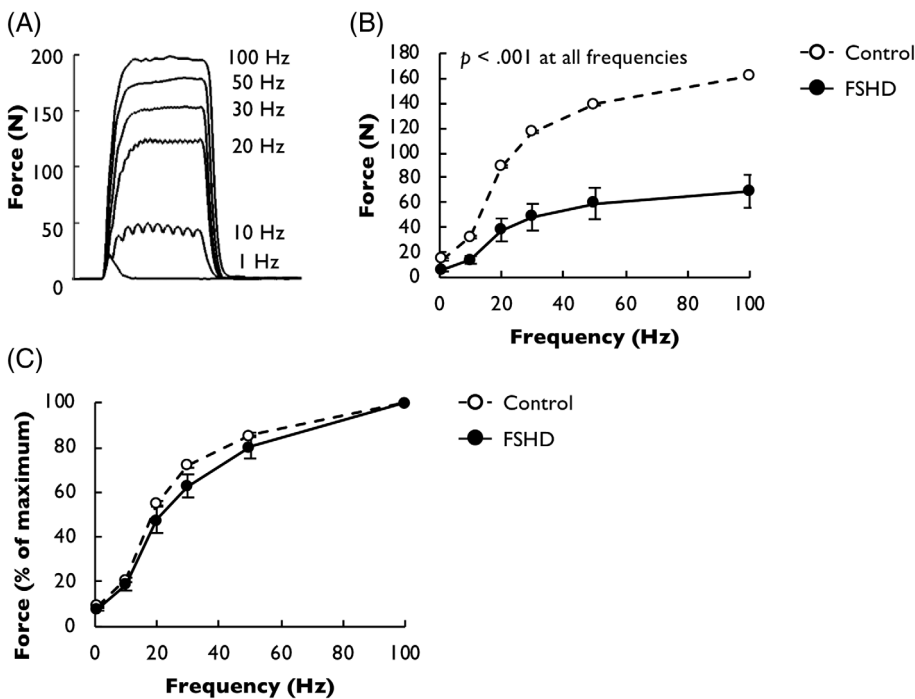


FIGURE 3 Force-frequency relationship. A, Incremental currents were applied at 1–10–20–30–50–100 Hz; force generated was measured to determine force-frequency relationships. B, Absolute stimulated force was less in severe FSHD participants, reflecting lower MVC. C, Force-frequency relationship corrected for maximum force was shifted to the right in participants with severe FSHD, but did not differ between mild FSHD and control participants. $P < .05$ is considered significant, * $P < .05$, ** $P < .01$, *** $P < .001$

pain score of 3/10; 67% of severe FSHD with a mean pain score of 2/10, $p = .035$).

3.3 | Quantitative muscle imaging

Quantitative imaging of the quadriceps was performed in 11/12 controls and 12/12 FSHD participants. MRI scanning could not be performed successfully in one control due to claustrophobia. TCSA, CCSA, and FCSA did not differ in patients with mild FSHD compared to controls (Figure 1D). In contrast, patients with severe FSHD had an increased FCSA, resulting in reduced CCSA compared to controls (Figure 1D).

3.4 | Quadriceps strength and specific force

MVC measurement was performed in 12/12 controls and 12/12 FSHD patients. MVC was significantly decreased in patients with severe FSHD (Figure 2A). MVC showed a linear relationship with CSSA in both controls and FSHD patients (Figure 2B). Quadriceps specific force was decreased in all FSHD participants independent of disease severity (Figure 2C). Assessed by severity, specific force was reduced by 34% in patients with mild FSHD and by 32% patients with severe FSHD (Figure 2C).

3.5 | Quadriceps force-frequency relationship

Stimulated measurements were not tolerated by all participants. As a consequence, data were acquired in 11/12 controls and 10/12 FSHD participants: 4 with mild FSHD and 6 with severe FSHD. Absolute force responses to stimulation at different frequencies were lower in severe FSHD patients compared to controls, reflecting reduced MVC (Figure 3A,B). When normalized for peak force, the force-frequency

relationship was shifted to the right in severe FSHD patients compared to controls (Figure 3C). The force-frequency relationship was not different in mild FSHD compared to controls.

3.6 | Vastus lateralis fiber type distribution

Morphometric analysis of muscle biopsies showed that fiber type distribution was not changed in FSHD compared to control biopsies, independent of disease severity (mean percentage of type 1 fibers: 57.6 ± 4.0 in control vs. 50.0 ± 7.6 in mild FSHD vs. 64.4 ± 2.4 in severe FSHD, $p = .208$).

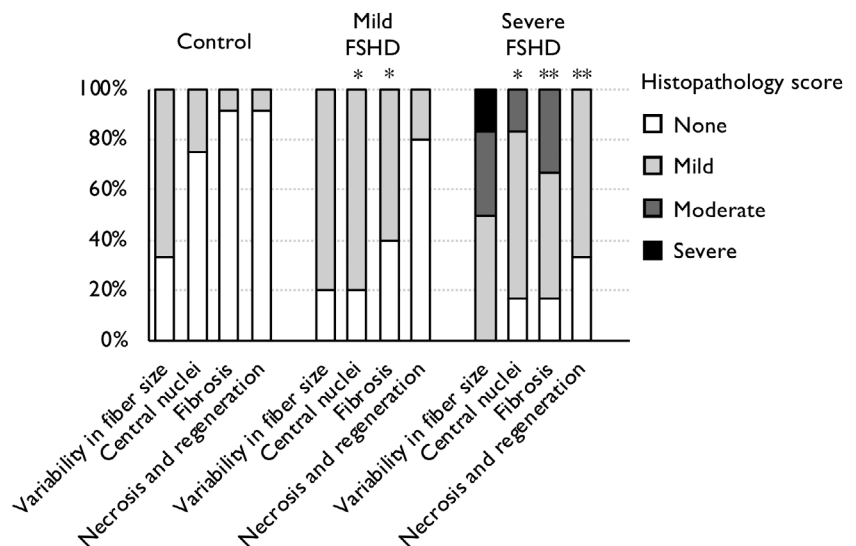
3.7 | Vastus lateralis histopathological studies

Histopathological analysis showed mild myopathic abnormalities in biopsies obtained from patients with mild FSHD, with a significant increase in internal nuclei (Figure 4) and interstitial fibrosis (Figure 4). Histopathological analysis showed more severe myopathic and dystrophic abnormalities in biopsies obtained from patients with severe FSHD, with a significant increase in internal nuclei, interstitial fibrosis, and necrosis and/or regeneration. There was no significant correlation between the severity of interstitial fibrosis and specific force ($p = .327$) or other parameters that were scored on muscle biopsy.

4 | DISCUSSION

This study demonstrates that reduced quadriceps specific force is an early feature of FSHD that occurs prior to the onset of fatty infiltration or clinical lower extremity weakness. Reduced specific force was also present in more severely affected patients with fatty infiltration of the quadriceps and lower extremity muscle weakness.

FIGURE 4 Histopathological studies. Evaluation of (1) variability in fiber size, (2) extent of central nucleation, (3) increase in interstitial fibrosis, (4) necrosis and/or regeneration in vastus lateralis muscle biopsies. None or mild abnormalities were encountered in healthy controls, which were all between age 40 and 65. Muscle biopsies obtained from participants with mild FSHD showed significantly increased amounts of internal nuclei and interstitial fibrosis. All parameters were increased in biopsies obtained from participants with severe FSHD. $P < .05$ is considered significant, * $P < .05$, ** $P < .01$, *** $P < .001$



Our results show that quadriceps specific force is reduced in patients with mild and severe FSHD. Our results in severe FSHD confirmed previous published data.^{6,12} Specific force values were relatively similar in patients mild FSHD, but values varied widely in patients with severe FSHD. The overall amount of reduction in specific force was similar in mild compared to severe FSHD participants. Several factors may have contributed to the increased variability in patients with severe FSHD. The amount of fatty infiltration of the quadriceps in patients with severe FSHD varied between 8 and 83%. Counter-intuitively, specific force was higher in FSHD patients with more severe fatty infiltration. In FSHD, quadriceps involvement starts with distal atrophy and fatty infiltration.^{4,25} Given that the absolute amount of force generated by a muscle is determined by its largest cross-sectional area, reflecting the number of sarcomeres in parallel, distal atrophy and fatty infiltration in patients with severe FSHD may result in overestimation of specific force.

Non-neuromuscular factors also influence force generation and may be more pronounced in patients with severe FSHD. In this study, muscle strength was measured using quadriceps MVC, which can be influenced by fatigue and pain. Both are highly prevalent in FSHD, considering that 61% of FSHD patients report severe fatigue and 89% report pain.^{26,27} Pain was indeed reported more frequently by patients with severe FSHD, of which 67% reported back and pelvic pain with a mean pain score of 2/10. Sub-maximal effort may also have contributed to reduced quadriceps endurance in a previous study.¹² Future studies should consider using electrically evoked quadriceps force measurements to exclude motivational factors.

One potential cause of reduced specific force is predominance of type 1 muscle fibers. We investigated the force-frequency relationship to investigate potential fiber type shifts in FSHD participants. The force-frequency relationship reflects the amount of force generated in response to electrical stimulation at different frequencies between 1 and 100 Hz. A leftward shift of the force-frequency relationship usually indicates an increased amount of type 1 fibers, as slower contraction and relaxation speeds facilitate force summation in these fibers.^{21,22} Our results show that force-frequency curves in patients with mild FSHD are not different from controls, which indicates that reduced quadriceps specific force is not caused by fiber type shift. Vastus lateralis muscle biopsy studies in the same participants confirmed these findings, which are in line with previous studies on fiber type distribution in FSHD.²⁸ The rightward shift of the quadriceps force-frequency relationship that we observed in patients with severe FSHD is most likely caused by impaired propagation of the electrical stimulus in fat infiltrated tissue.

Previous studies have suggested that reduced specific force may be caused by changes in muscle architecture, including increased amounts of interstitial fibrosis. Histopathological analysis showed mild myopathic abnormalities in vastus lateralis muscle biopsies obtained from participants with mild FSHD: increased amounts of internal nuclei and increased interstitial fibrosis. This is compatible with previous studies which showed that in FSHD patients without lower extremity weakness, muscle biopsies are either normal or show mild myopathic changes.²⁴ Furthermore, muscle ultrasound can demonstrate structural abnormalities in muscles that appear normal on muscle MRI, most likely due to increased interstitial fibrosis which is not

detected on MRI.²⁹ Increased amounts of interstitial fibrosis reduce the amount of contractile material per cross-sectional area and disturb force transmission, resulting in reduced specific force.³⁰ However, the role of interstitial fibrosis in the reduction of specific force is probably small, as only mild or no fibrosis was observed histologically in the mild FSHD group.

Specific force may also be reduced by impaired sarcomeric function of the muscle fiber. We have previously investigated sarcomeric function in muscle fibers isolated from the same biopsies that were used in this study, and showed maximum and specific force generation are preserved in FSHD single muscle fibers.³¹

A limitation from this study is its small sample size and the use of axial muscle MRI images at a single level, to determine quadriceps cross-sectional area. In healthy subjects without muscle disease, quadriceps cross-sectional area at this level correlates well with quadriceps muscle volume.³² As discussed previously in this discussion, distal atrophy and fatty infiltration would result in overestimation of specific force relative to controls.³² This strengthens our findings in participants with mild FSHD. Another limitation is that we included participants with both FSHD1 (N = 8), FSHD2 (N = 3), and one patient who was mosaic for FSHD1. All FSHD2 patients and the mosaic patient had severe FSHD. Although previous studies have shown no clinical differences between FSHD1 and FSHD2, we cannot exclude that the differences in genotype in the severe FSHD group influenced the results.

Specific force is a potential outcome measure for therapeutic trials, in particular for patients with mild FSHD. Quantitative MRI has become an established biomarker for FSHD disease progression. Specific force can be determined if quantitative force measurements are added. Longitudinal studies are needed to assess the applicability of specific force as an outcome measure for FSHD.

In conclusion, reduced specific force is present in patients with mild and severe FSHD and can be detected prior to the onset of fatty infiltration or weakness of the lower limbs. Early myopathic changes, including increased interstitial fibrosis, and non-muscle factors such as experienced fatigue or musculoskeletal pain may contribute to reduced specific force. Our findings are relevant when using quantitative muscle testing as an outcome measure in therapeutic trials, as reduced specific force influences potential muscle performance.

ACKNOWLEDGEMENTS

This work was supported by the Prinses Beatrix Spierfonds and Stichting Spieren voor Spieren (grant no. W.OR10-30).

CONFLICTS OF INTERESTS

None of the authors have any conflict of interest to disclose.

AUTHOR CONTRIBUTIONS

S.L. included all participants, performed clinical evaluation, functional measurements and MRI analysis, analyzed the data, and drafted the manuscript supervised by N.V., T.S., A.H., C.O., M.H., and B.v.E. within their specific areas of expertise. C.O. and B.v.E. were responsible for

conception and design of the study and obtained funding. All authors provided critical input for interpretation of the data and approved the final version of the manuscript.

ETHICAL PUBLICATION STATEMENT

We confirm that we have read the Journal's position on issues involved in ethical publication and affirm that this report is consistent with those guidelines.

REFERENCES

- Deenen JC, Arnts H, van der Maarel SM, et al. Population-based incidence and prevalence of facioscapulohumeral dystrophy. *Neurology*. 2014;83(12):1056-1059.
- Geng LN, Yao Z, Snider L, et al. DUX4 activates germline genes, retroelements, and immune mediators: implications for facioscapulohumeral dystrophy. *Dev Cell*. 2012;22(1):38-51.
- Gerevini S, Scarlato M, Maggi L, et al. Muscle MRI findings in facioscapulohumeral muscular dystrophy. *Eur Radiol*. 2016;26(3):693-705.
- Janssen BH, Voet NB, Nabuurs CI, et al. Distinct disease phases in muscles of facioscapulohumeral dystrophy patients identified by MR detected fat infiltration. *PLoS One*. 2014;9(1):e85416.
- Leung DG, Carrino JA, Wagner KR, Jacobs MA. Whole-body magnetic resonance imaging evaluation of facioscapulohumeral muscular dystrophy. *Muscle Nerve*. 2015;52(4):512-520.
- Marra MA, Heskamp L, Mul K, et al. Specific muscle strength is reduced in facioscapulohumeral dystrophy: an MRI based musculoskeletal analysis. *Neuromuscul Disord*. 2018;28(3):238-245.
- Tasca G, Monforte M, Ottaviani P, et al. Magnetic resonance imaging in a large cohort of facioscapulohumeral muscular dystrophy patients: pattern refinement and implications for clinical trials. *Ann Neurol*. 2016;79:854-864.
- Vanderplanck C, Ansseau E, Charron S, et al. The FSHD atrophic myotube phenotype is caused by DUX4 expression. *PLoS One*. 2011;6(10):e26820.
- Wallace LM, Garwick SE, Mei W, et al. DUX4, a candidate gene for facioscapulohumeral muscular dystrophy, causes p53-dependent myopathy in vivo. *Ann Neurol*. 2011;69(3):540-552.
- Wokke BH, van den Bergen JC, Versluis MJ, et al. Quantitative MRI and strength measurements in the assessment of muscle quality in Duchenne muscular dystrophy. *Neuromuscul Disord*. 2014;24(5):409-416.
- Lokken N, Hedermann G, Thomsen C, Vissing J. Contractile properties are disrupted in Becker muscular dystrophy, but not in limb girdle type 2I. *Ann Neurol*. 2016;80(3):466-471.
- Bachasson D, Temesi J, Bankole C, et al. Assessment of quadriceps strength, endurance and fatigue in FSHD and CMT: benefits and limits of femoral nerve magnetic stimulation. *Clin Neurophysiol*. 2014;125(2):396-405.
- Ricci E, Galluzzi G, Deidda G, et al. Progress in the molecular diagnosis of facioscapulohumeral muscular dystrophy and correlation between the number of Kpn1 repeats at the 4q35 locus and clinical phenotype. *Ann Neurol*. 1999;45(6):751-757.
- Enright PL. The six-minute walk test. *Respir Care*. 2003;48(8):783-785.
- Berard C, Payan C, Hodgkinson I, Fermanian J. Group MFMCS. A motor function measure for neuromuscular diseases. Construction and validation study. *Neuromuscul Disord*. 2005;15(7):463-470.
- Vercoulen JH, Bazelmans E, Swanink CM, et al. Physical activity in chronic fatigue syndrome: assessment and its role in fatigue. *J Psychiatr Res*. 1997;31(6):661-673.
- van der Kloot WA, Oostendorp RA, van der Meij J, van den Heuvel J. The Dutch version of the McGill pain questionnaire: a reliable pain questionnaire. *Ned Tijdschr Geneesk*. 1995;139(13):669-673.
- Lassche S, Ottenheim CA, Voermans NC, et al. Determining the role of sarcomeric proteins in facioscapulohumeral muscular dystrophy: a study protocol. *BMC Neurol*. 2013;13:144.
- Kan HE, Scheenen TW, Wohlgemuth M, et al. Quantitative MR imaging of individual muscle involvement in facioscapulohumeral muscular dystrophy. *Neuromuscul Disord*. 2009;19(5):357-362.
- Degens H, Sanchez Horneros JM, Heijdra YF, Dekhuijzen PN, Hopman MT. Skeletal muscle contractility is preserved in COPD patients with normal fat-free mass. *Acta Physiol Scand*. 2005;184(3):235-242.
- Gerrits HL, De Haan A, Hopman MT, van Der Woude LH, Jones DA, Sargeant AJ. Contractile properties of the quadriceps muscle in individuals with spinal cord injury. *Muscle Nerve*. 1999;22(9):1249-1256.
- Rochester L, Chandler CS, Johnson MA, Sutton RA, Miller S. Influence of electrical stimulation of the tibialis anterior muscle in paraplegic subjects. 1. Contractile properties. *Paraplegia*. 1995;33(8):437-449.
- Lassche S, Janssen BH, T IJ, et al. MRI-guided biopsy as a tool for diagnosis and research of muscle disorders. *J Neuromuscul Dis*. 2018;5(3):315-319.
- Statland JM, Shah B, Henderson D, Van Der Maarel S, Tapscott SJ, Tawil R. Muscle pathology grade for facioscapulohumeral muscular dystrophy biopsies. *Muscle Nerve*. 2015;52(4):521-526.
- Dahlqvist JR, Andersen G, Khawajazada T, Vissing C, Thomsen C, Vissing J. Relationship between muscle inflammation and fat replacement assessed by MRI in facioscapulohumeral muscular dystrophy. *J Neurol*. 2019;266(5):1127-1135.
- Kalkman JS, Schillings ML, van der Werf SP, et al. Experienced fatigue in facioscapulohumeral dystrophy, myotonic dystrophy, and HMSN-I. *J Neurol Neurosurg Psychiatry*. 2005;76(10):1406-1409.
- Moris G, Wood L, Fernandez-Torron R, et al. Chronic pain has a strong impact on quality of life in facioscapulohumeral muscular dystrophy. *Muscle Nerve*. 2018;57(3):380-387.
- Lin MY, Nonaka I. Facioscapulohumeral muscular dystrophy: muscle fiber type analysis with particular reference to small angular fibers. *Brain Dev*. 1991;13(5):331-338.
- Mul K, Horlings CGC, Vincenten SCC, Voermans NC, van Engelen BGM, van Alfen N. Quantitative muscle MRI and ultrasound for facioscapulohumeral muscular dystrophy: complementary imaging biomarkers. *J Neurol*. 2018;265(11):2646-2655.
- Lieber RL, Ward SR. Cellular mechanisms of tissue fibrosis. 4. Structural and functional consequences of skeletal muscle fibrosis. *Am J Physiol Cell Physiol*. 2013;305(3):C241-C252.
- Lassche S, Voermans NC, van der Pijl R, et al. Preserved single muscle fiber specific force in facioscapulohumeral muscular dystrophy. *Neurology*. 2020;94:e1157-e1170.
- Marcon M, Ciritis B, Laux C, et al. Cross-sectional area measurements versus volumetric assessment of the quadriceps femoris muscle in patients with anterior cruciate ligament reconstructions. *Eur Radiol*. 2015;25(2):290-298.

SUPPORTING INFORMATION

Additional supporting information may be found online in the Supporting Information section at the end of this article.

How to cite this article: Lassche S, Voermans NC, Schreuder T, et al. Reduced specific force in patients with mild and severe facioscapulohumeral muscular dystrophy. *Muscle & Nerve*. 2021;63:60-67. <https://doi.org/10.1002/mus.27074>