

Timing of laser following intravitreal anti-vascular endothelial growth factor injections for aggressive posterior zone 1 retinopathy of prematurity

Published in this issue of Indian Journal of Ophthalmology is a retrospective cohort of 24 infants with posterior zone 1 or 'zone half' aggressive posterior retinopathy of prematurity (APROP) who underwent intravitreal ranibizumab followed by laser photoablation between days 24 and 34 after the injection.^[1] They report a 93% favourable outcome after 6 months of follow-up. The rationale of combining treatments is to possibly synergise the effect of the blocking action of anti-vascular endothelial growth factor (VEGF) agents with the suppression of production of VEGF as well as to aid elimination of these proangiogenic factors by laser ablation.

The optimal timing of 'adding' laser is however still unresolved. Kim *et al.* performed laser with 810 nm Diode laser within 0–8 days of the injection, with a median of 3 days, and reported a good response.^[2] Some eyes in their series were concurrently injected along with laser ablation. Tandon *et al.* performed laser early for those with recurrences and between 4 and 14 weeks postinjection for other cases.^[3] Padhi *et al.* have described shunts after anti-VEGF therapy, which have responded to subsequent laser.^[4]

In posterior zone 1 APROP, the challenge is even greater as the surgeon is dealing with poorly demarcated vascular arcades, immature foveal landmarks, hazy media and even haemorrhages situated posteriorly, which make it imperative to 'mark the posterior border with laser' at the start of the procedure and then strive not to breach this limit. Flat neovascularization (NVE) of APROP is best addressed in two sessions,^[5] but this NVE is not present in all cases of posterior zone 1 ROP.

Getting the 'right interval' between injection and laser is not as straight forward. Several factors influence the 'ideal' timing of laser intervention; 1) response of the disease to the drug, 2) recurrences, 3) vascular growth into the retina beyond zone 1, 4) weight of the baby, 5) post menstrual age, 6) systemic

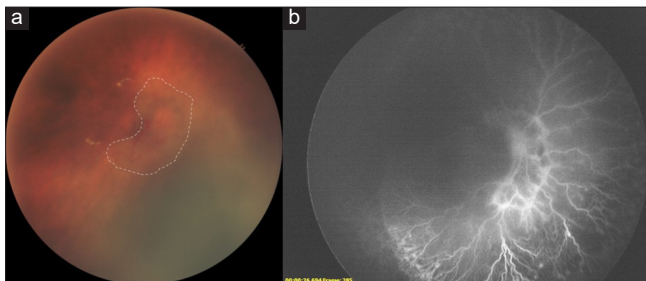


Figure 1: (a) Right eye with posterior zone 1 aggressive posterior retinopathy of prematurity showing grossly attenuated vasculature in the 'zone half' location (dotted white area), imaged on the Neo (Forus Health, India) 1 day after intravitreal anti-VEGF injected in a district hospital. (b) Angiogram (RetCam 3, Natus, USA) of the same eye in (a) imaged in a tertiary care centre, 14 + 3 weeks after the injection showing vascular growth into zone 2 with an active 'leading' edge, neovascular complexes and recurrence of tortuosity, prior to laser therapy

conditions and 7) follow-up compliance- a factor particularly important in rural India. It may be argued that the rationale of 'waiting' after the anti-VEGF agent for laser ablation is to allow vascularization to proceed beyond the critical zone 1 region. In some cases, vascularization can progress into more peripheral zones before they either stop or show signs of recurrence or worsen. In this regard, the time interval of 4 weeks that the authors have chosen for laser treatment in *all* their cases is debatable. Ideally, if compliant follow-up is ensured and enforced, a schedule of weekly imaging until a postmenstrual age of 44 weeks, fortnightly until 52 weeks and monthly thereafter may help to detect the growth of vascularization as well as any recurrence that may warrant early intervention [Fig. 1]. In the KIDROP programme, this screening schedule is followed even in rural hospitals for infants who are injected to help prevent attrition of follow-up due to long distances from the treating centre.^[6] Any early sign of recurrence is treated with 532 nm green laser ablation. Those with no recurrence, showing anterior vascular growth, continue follow-up and are subjected to fluorescein angiography once the retinal vessels enter zone 2 anterior [Fig. 2]. Laser is performed thereafter only if there is active flat neovascularization (*confirmed on angiography*), arrest of vascularization or unwillingness to follow-up further. With this approach we are able to spare a larger part of retinal area from laser ablation.

In India, as in many other middle-income countries, besides the non-availability of angiography in most ROP units, the other logistic challenge is one of the follow-ups, especially in rural regions. Furthermore, imaging these older infants who are heavier becomes increasingly difficult. Treating them with laser under topical anaesthesia is an even bigger challenge. Safe and effective general anaesthesia for these older infants is not easily available in all centres. Hence, it is imperative to find the optimal time to intervene with laser.

While it may be scientifically sound to individualize the interval of laser for each case based on the initial response, it may not be pragmatic in many situations. The clinician must define the rules based on his or her own setting. The comfort of performing laser on a heavier and larger baby under topical anaesthesia, the framework of follow-up, the opportunity for imaging and angiography among others must be considered while performing combined therapy for retinopathy of prematurity.

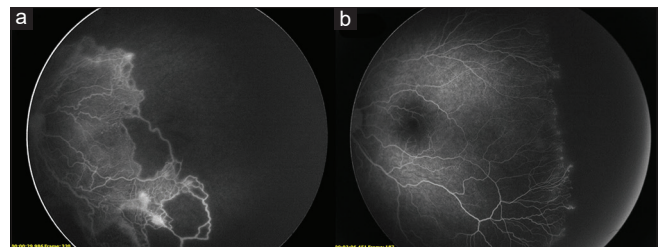


Figure 2: (a) Fluorescein Angiography (RetCam 3, Natus, USA) of the left eye of a preterm infant with zone 1 aggressive posterior retinopathy of prematurity before intravitreal treatment with anti VEGF. (b) Ten months after the injection, angiogram still reveals retinal vasculature growing into zone 2 anterior with flat neovascularization and pin-point dye leakage from the active edge

Financial support and sponsorship

Nil.

Conflicts of interest

There are no conflicts of interest.

Anand Vinekar

Department of Pediatric Retina,
Narayana Nethralaya Eye Institute, Bangalore, Karnataka, India.
E-mail: anandvinekar@yahoo.com

References

1. Parchand SM, Agrawal D, Gangwe A, Saraogi T, Agrawal D. Combined intravitreal ranibizumab and zone I sparing laser ablation in infants with posterior zone I retinopathy of prematurity. *Indian J Ophthalmol* 2021;69:2164-70.
2. Kim J, Kim S, Chang Y, Park W. Combined intravitreal Bevacizumab injection and Zone I sparing laser photocoagulation in patients with Zone I retinopathy of prematurity. *Retina* 2014;34:77-82.
3. Tandon M, Vishal MY, Kohli P, Rajan RP, Ramasamy K. Supplemental laser for eyes treated with bevacizumab monotherapy in severe retinopathy of prematurity. *Ophthalmol Retina* 2018;2:623-8.
4. Padhi TR, Das T, Rath S, Pradhan L, Sutar S, Panda KG, *et al.* Serial evaluation of retinal vascular changes in infants treated with intravitreal bevacizumab for aggressive posterior retinopathy of prematurity in zone I. *Eye (Lond)* 2016;30:392-9.
5. Vinekar A, Jayadev C, Mangalesh S, Kumar AK, Bauer N, Capone A Jr, *et al.* Comparing the outcome of single versus multiple session laser photocoagulation of flat neovascularization in zone I aggressive posterior retinopathy of prematurity: A prospective, randomised study. *Retina* 2015;35:2130-6.
6. Vinekar A, Gilbert C, Dogra M, Kurian M, Shainesh G, Shetty B, *et al.* The KIDROP model of combining strategies for providing retinopathy of prematurity screening in underserved areas in India using wide-field imaging, tele-medicine, non-physician graders and smart phone reporting. *Indian J Ophthalmol* 2014;62:41-9.

This is an open access journal, and articles are distributed under the terms of the Creative Commons Attribution-NonCommercial-ShareAlike 4.0 License, which allows others to remix, tweak, and build upon the work non-commercially, as long as appropriate credit is given and the new creations are licensed under the identical terms.

Access this article online	
Quick Response Code:	Website: www.ijo.in
	DOI: 10.4103/ijo.IJO_373_21

Cite this article as: Vinekar A. Timing of laser following intravitreal anti-vascular endothelial growth factor injections for aggressive posterior zone 1 retinopathy of prematurity. *Indian J Ophthalmol* 2021;69:1988-9.

About the author



Dr Anand Vinekar

Dr. Anand Vinekar currently serves as the Head of Department, Pediatric Retina at Narayana Nethralaya Eye Institute, Bangalore. He is the founder and Program Director of KIDROP, a tele-ROP model he pioneered in 2007 which was India's first wide-field imaging-based retinopathy of prematurity screening program for rural and outreach areas. This model has since been replicated in other states and countries. KIDROP has completed over 190,000 imaging sessions and has treated over 3000 babies with ROP. Dr Vinekar has served on the National Task Force for ROP, which formulated the Indian ROP guidelines. He has also served as a member of the ROP committee of the National Neonatology Forum, Queen Elizabeth Diamond Jubilee Trust, National Operational Guidelines & Indian Medical Association Committee on infant blindness prevention. He is a member of the ICROP-3 group which classified ROP in 2021 and is the founder Secretary of the Indian ROP society