

Congenital Lateral Facial Teratoma: A Case Report and Review of Literature

Enono Yhoshu, Gyanendra Chaudhary, Intezar Ahmed, Manish Kumar Gupta

Department of Pediatric Surgery, All India Institute of Medical Sciences, Rishikesh, Uttarakhand, India

Abstract

Facial teratomas are uncommon tumours in children that distort the face and may be associated with functional problems. They are less common than cervical teratomas though they are often grouped together and considered an emergency due to their tendency to cause respiratory compromise. They tend to be large and cause cosmetic issues; hence usually noticed early and medical help sought promptly by parents. The close proximity of facial teratomas to structures like eyes, parotid gland, facial nerve, vessels and brain makes them challenging and requires a patient and meticulous exploration during surgery. We present a case of an 11 month old girl with left sided temporal teratoma. Well planning of the incision and complete excision of the tumour with careful sparing of the facial nerves and parotid gland yielded good result.

Keywords: Abnormalities, congenital, face, mature teratoma

INTRODUCTION

Teratomas are among the common tumours of infants and children with an incidence of 1: 4000 live births and a female predominance.^[1] Head and neck or craniocervical teratomas are uncommon tumours comprising 0.47%–6% of all teratomas, with an incidence of 2.5–5/100,000 live births.^[2] Craniocervical teratomas are different in that they are large and cause facial distortions, produce respiratory distress, cause obstetric complications like polyhydramnios, preterm labour and are associated with other abnormalities such as congenital cardiac disease, cleft lip and palate, bifid tongue and nose, mandibular hypoplasia.^[3]

Lateral facial tumours are extremely rare and are usually associated with bony and neurological deformities. Total surgical excision continues to be the best mode of treatment and early intervention can prevent the risk of malignant transformation. Here, we want to describe our management and follow-up of a lateral facial teratoma case with review of the literature.

CASE REPORT

An 11-month-old girl was brought with swelling on the left side of the face present since birth. Parents had shown her to a doctor,

but due to financial constraints, they could not get her operated. According to the parents, the child had no pain, difficulty in chewing food, opening mouth, difficulty in hearing or other neurological deficit. On examination, the swelling was occupying the lateral part of the face and measuring about 10 cm × 7 cm, extending superiorly to left temporo-parietal region, medially to mid-cheek and lateral part of upper eye lid, and posteriorly pushing the ear backwards and downwards laterally [Figure 1]. The overlying skin was normal with no neurological deficit.

Routine blood tests were normal, and serum alpha foetoprotein (AFP) was 7.3 ng/ml ($n = 0–10$ ng/ml). Ultrasound showed a solid-cystic mass with septations in the left temporoparietal region. Contrast-enhanced magnetic resonance imaging (MRI) of the brain and face showed a large extracranial well-defined rounded mixed intensity mass lesion measuring approximately 8 cm × cm 6 × 9 cm along the left side of skull vault [Figure 2a and b]. Internally lesion was multicystic with areas of fat intensity. There was scalp defect with curvilinear communication of the mass lesion with extradural space. On

Address for correspondence: Dr. Enono Yhoshu,
Department of Pediatric Surgery, 6th Floor 'A' Block, All India Institute of
Medical Sciences, Rishikesh - 249 203, Uttarakhand, India.
E-mail: enoyo83@gmail.com

Received: 25-05-2020 Revised: 05-07-2020 Accepted: 17-07-2020 Available Online: 18-02-2021

Access this article online

Quick Response Code:



Website:
www.afjrpaedsurg.org

DOI:
10.4103/ajps.AJPS_77_20

This is an open access journal, and articles are distributed under the terms of the Creative Commons Attribution-NonCommercial-ShareAlike 4.0 License, which allows others to remix, tweak, and build upon the work non-commercially, as long as appropriate credit is given and the new creations are licensed under the identical terms.

For reprints contact: WKHLRPMedknow_reprints@wolterskluwer.com

How to cite this article: Yhoshu E, Chaudhary G, Ahmed I, Gupta MK. Congenital lateral facial teratoma: A case report and review of literature. Afr J Paediatr Surg 2021;18:99-103.

computed tomography (CT) correlation, there were no areas of calcification seen within the lesion.

Intraoperatively, a left lateral facial incision was made over the mass extending to the forehead [Figure 2c]. There was a large solid cystic mass about 9 cm × 12 cm × 5 cm in the left temporal region and extending to the cheek, causing displacement of the left ear posteriorly with no visible deficit in the skull. Posteriorly the mass was densely adherent to the anterior wall of the parotid which was gradually teased off. The mass was excised in-toto and excess skin was excised, and closure was done after placing a suction drain in the residual cavity [Figure 2d-f]. Post-operatively, the patient received intravenous analgesic and antibiotics. She recovered well with no neurological deficit or wound infection and was discharged after the drain was removed on the postoperative day 5.

Histopathology report showed mature cystic teratoma-solid cystic lesion, filled with milky fluid with an intact capsule. Tumour had squamous, ciliated columnar, intestinal epithelium, neuronal tissue, gastric tissue, salivary gland, lymphoid follicles, adipose tissue, muscle bundles, pancreatic tissue and foamy macrophages [Figure 3a and b]. Repeat AFP level done at 3 months was normal (2.3 ng/ml). The patient is on follow-up for 21 months now and is doing well with no recurrent growth or neurological deficit [Figure 3c and d].

DISCUSSION

Extragenital teratomas are more common in newborns and gonadal predominant in older children.^[4] Craniocervical teratomas comprise about 6% of teratomas and occur usually in the neonatal period. Differential diagnosis for craniocervical teratomas are: encephalocele, lymphangioma, cystic hygroma, vascular malformations, large branchial and thyroglossal cysts.^[2] The sites in the craniofacial area for teratomas to occur includes 'Extracranial' such as nasopharyngeal area (epignathus), base of the tongue, lateral face, scalp, cheeks and lips; and 'intracranial' such as massive tumours replacing intracranial contents and extending into orbit or neck, small

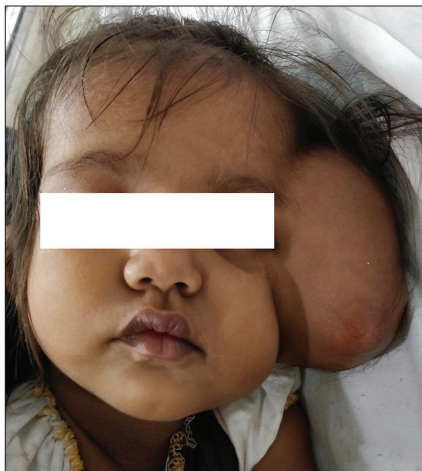

Figure 1: Facial profile of the patient with left temporal mass

tumours causing hydrocephalus and a combination of both occurring together.^[1-6]

Lateral facial teratomas are extremely rare and do not pose as an emergency for airway compromise or feeding, unlike cervical teratomas. They can range from small lesions to large grotesque lesions which are apparent from birth or increase gradually and convince parents to seek early medical opinion. Their close proximity to structures such as nerves, eyes, ears and parotid gland requires clear understanding of the anatomy, relation to surrounding structures and planning with a multidisciplinary team for a satisfactory outcome. The following are similar cases described in the literature [Table 1].^[2,3,7-11] As seen in our case, facial mass in the reported cases were also noticed in the neonatal age. The size of the mass ranged from 3 cm × 2 cm to 24 cm × 18 cm × 16 cm in literature, our case mass measured 12 cm × 9 cm × 5 cm.

About 16% of patients have calcifications on plain X-rays due to bone or tooth formation.^[7] Ultrasound and contrast-enhanced

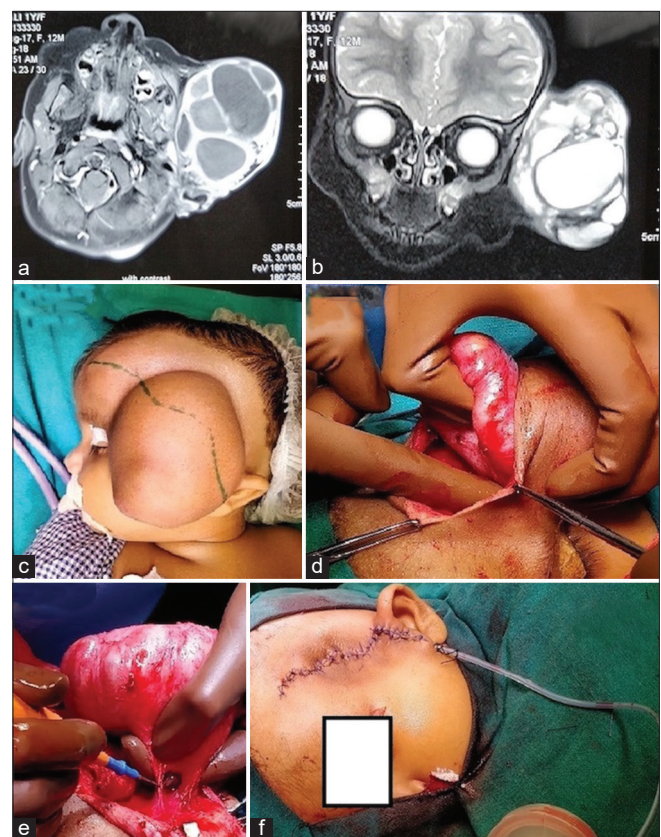


Figure 2: Picture details of the patient: (a) Magnetic resonance imaging of patient-Transverse sections showing mixed density mass lesion left side temporal area. (b) Magnetic resonance imaging – Coronal sections showing multicystic mass with areas of fat density in left temporal. (c) Pre-o-perative marking of the incision line (left lateral facial) over the mass. (d) Intra-operative well encapsulated mass being dissected. (e) Whole-mass being mobilised off the floor with parotid in its floor. (f) Post-closure of wound showing the stitch line with sunken temporal area and drain *in situ*

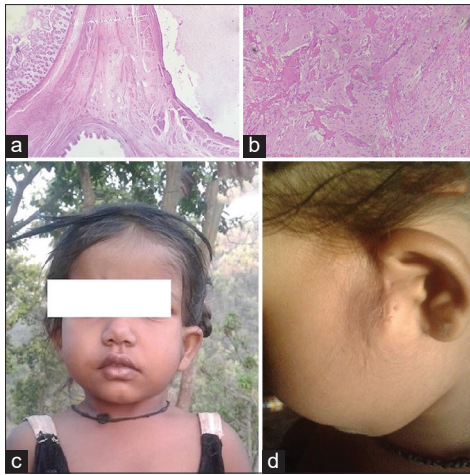

Figure 3: (a) Photomicrograph showing a cystic tumour with squamous epithelium, intestinal and respiratory epithelium. H and E stain, $\times 2$ view. (b) Photomicrograph showing muscle tissue. H and E stain, $\times 2$ view. (c) Follow-up at 21 months showing the child's face with no skin laxity. (d) Closer lateral view of the face showing healed scar

CT scan and MRI help in identifying the consistency-cystic or solid; extent of the lesion-extracranial or intracranial; and identifying the distortion/involvement of the surrounding tissues. Of the cases reported, 3 of them underwent CT scan alone, 3 including ours underwent both CT scan and MRI and one had done only MRI.

Complete surgical excision is the treatment of choice and can be challenging due to the large size, adherence to surrounding structures like facial muscles, parotid gland and facial nerves, and extent to intracranial region. Recurrence of follow-up is related to incomplete resection and immature teratoma has been seen to have a higher tendency for recurrence.^[5] In the three cases described by Kadlub *et al.*, two of them underwent subtotal excision, and recurrence was inevitably seen [Table 1].^[2] Our case underwent total excision of the left temporal mass. Whenever the excision is a challenge due to surrounding structures being involved, removal of the tumour as much as possible along with additional surgeries like cranial facial reconstruction, fat grafting, osteogenesis distraction

Table 1: Tabulated details of lateral facial teratoma case reports in literature

Author, year	Age	Location/size	Investigations-AFP (IU/ml)/radiological imaging	Treatment and salient intraoperative findings	Histopathology	Outcome
Kadlub <i>et al.</i> , 2014 ^[2]	3 cases, ages not mentioned	Temporo-maxillary/8.3 cm Temporozygomatic and intraoral/5 cm Temporofrontal/6.6 cm	Not mentioned/ MRI	Subtotal excision Subtotal excision Total excision	Mature teratoma Mature teratoma Mature teratoma	Recurred. Complete resection of submasseteric remnant and subtotal parotidectomy after 2 years. Need Coleman fat graft Recurred. Complete resection after 3 months. Mandibular nerve hypoesthesia, asymmetrical mandibular growth Good outcome
Anderson and David 2003 ^[3]	1 day	Left temporal/not mentioned, pushed zygomatic arch laterally	Not mentioned/ CT scan	Total excision with zygomatic osteotomy and defect closure with temporalis muscle flap	Teratoma	Needed grommet insertion twice (ear infections) Mandibular asymmetrical due to abnormal development of the TMJ (mandibular osteotomy planned) At present doing fine with no recurrence at 11 years
Alexander <i>et al.</i> , 2015 ^[7]	2 cases Newborn 20 weeks	Temporal mass/6 cm \times 4.5 cm \times 3 cm Right facial mass/18 cm \times 12 cm \times 10 cm	Not specified in which patients/ not mentioned which imaging done	Near total excision Total excision	Mature teratoma Immature teratoma	Right temporal bone defect/hallowing-patient refused craniofacial reconstruction. Doing well at 2 years follow-up Partial right facial paralysis, underwent facial reconstruction. No recurrence at 4 years follow-up
Paulus <i>et al.</i> , 2009 ^[8]	1 day	Right laterofacial mass/large, size not mentioned, distorting the zygomatico-orbital complex	Not mentioned/ CT scan and MRI	Complete excision with superficial parotidectomy by extended right lateral facial approach	Mature teratoma	At 4 years of age, a cervicofacial lift done to reduce the soft tissue sagging of the right cheek At 7 years of age, doing well with malar distortion still moderately noticeable and slight tissue excess of cheek

Contd...

Table 1: Contd...

Author, year	Age	Location/size	Investigations-AFP (IU/ml)/radiological imaging	Treatment and salient intraoperative findings	Histopathology	Outcome
Isik <i>et al.</i> , 2011 ^[9]	1 day	Right side face and cranium/24 cm × 18 cm × 16 cm with severe distortion of temporoparietal bone and right lateral orbit	60,500/CT scan and MRI	Total excision by right lateral facial incision	Mixed immature teratoma, G3	Doing well in follow up of 6 months. No neurological deficit. Cranial defect reconstruction planned
Rai <i>et al.</i> , 2012 ^[10]	1 day	Right lateral orbital wall/3 cm × 2 cm firm to hard mass with 2 adjacent skin tags	Not mentioned/CT scan	Deep complete excision	Mature teratoma; skin tags showed fibroepithelial polyp	Doing well in follow up of 2 years
Kekre <i>et al.</i> , 2016 ^[11]	1 day	Left face/size not mentioned, extending from temporal fossa to submandibular region	40,000/CT scan	Complete excision by left lateral facial approach. Thinned out facial muscles and nerve over mass. Parotid displaced posteriorly	Mature tridermal teratoma	Doing well with no signs of recurrence at 11 months follow-up. No neurological deficit
Index case	11 months	Left temporal mass/12 cm × 9 cm × 5 cm	7.3/CT scan and MRI	Complete excision by left lateral facial approach. Densely adherent to anterior wall of parotid gland	Mature cystic teratoma	Doing well with no neurological deficit and recurrence at 21 months follow-up

AFP: Alpha fetoprotein, MRI: Magnetic resonance imaging, CT: Computed tomography, TMJ: Temporomandibular joint

of impaired mandibular growth were done.^[5,6] If tumour is dumbbell, advanced surgical techniques like neuronavigation, endoscopic sinus surgery or transbasal approaches are needed for complete clearance of teratoma.^[12] There can be neurological deficits after surgery such as Mandibular nerve hypoesthesia or partial right facial nerve palsy.^[2,7] These highlights the importance of appropriate counselling of the parents regarding the post-operative complications, recurrence and need for additional surgeries in follow-up.

The histopathology in craniocervical teratomas is commonly mature, though rarely it can be immature teratoma as seen in the case of Alexander *et al.*^[7] Our case was also reported as mature teratoma. Serum AFP can be used for follow-up in post-operative period though serial AFP values are more important than a single value.

In conclusion, though teratomas are common tumours in infancy and childhood, lateral facial teratomas are extremely rare. The key elements in the optimum management of such tumours include appropriate imaging for the extent of tumour, in-depth discussion with parents regarding the diagnosis and probable prognosis and all attempts for complete surgical excision with preservation of surrounding vital structures. A good follow-up of patient to exclude

recurrence, neurological deficit and need for additional surgeries are crucial.

Informed consent

Written informed consent has been obtained from the parents for publication.

Declaration of patient consent

The authors certify that they have obtained all appropriate patient consent forms. In the form, the parents have given their consent for images and other clinical information to be reported in the journal. The parents understand that names and initials will not be published, and due efforts will be made to conceal identity, but anonymity cannot be guaranteed.

Acknowledgement

We are grateful to Dr Sakshi Garg Tayal (pathologist) for her efforts to contribute the biopsy pictures for the paper.

Financial support and sponsorship

Nil.

Conflicts of interest

There are no conflicts of interest.

REFERENCES

1. Coppit GL 3rd, Perkins JA, Manning SC. Nasopharyngeal teratomas and dermoids: A review of the literature and case series. *Int J Pediatr Otorhinolaryngol* 2000;52:219-27.
2. Kadlub N, Touma J, Leboulanger N, Garel C, Soupre V, L'Herminé AC, *et al.* Head and neck teratoma: From diagnosis to treatment. *J Craniomaxillofac Surg* 2014;42:1598-603.
3. Anderson PJ, David DJ. Teratomas of the head and neck region. *J Craniomaxillofac Surg* 2003;31:369-77.
4. Seyhan T, Sener L, Refik Ozerdem O, Bal N. Mature teratoma presenting as a scalp mass in a newborn. *J Craniofac Surg* 2006;17:1009-11.
5. Mann JR, Gray ES, Thornton C, Raafat F, Robinson K, Collins GS, *et al.* Mature and immature extracranial teratomas in children: the UK Children's Cancer Study Group Experience. *J Clin Oncol* 2008;26:3590-7.
6. Shah A, Latoos S, Ahmed I, Malik AH. Head and neck teratomas. *J Maxillofac Oral Surg* 2009;8:60-3.
7. Alexander VR, Manjaly JG, Pepper CM, Ifeacho SN, Hewitt RJ, Hartley BE. Head and neck teratomas in children-A series of 23 cases at Great Ormond Street Hospital. *Int J Pediatr Otorhinolaryngol* 2015;79:2008-14.
8. Paulus P, Crêvecoeur H, Piette E, Lejuste P, Hustin J. Huge teratoma of the face. *J Craniomaxillofac Surg* 2009;37:352-5.
9. Isik N, Yildirim S, Onoz M, Aras A. Surgical treatment of huge congenital extracranial immature teratoma: A case report. *Childs Nerv Syst* 2011;27:833-9.
10. Rai M, Hegde P, Devaraju UM. Congenital facial teratoma. *J Maxillofac Oral Surg* 2012;11:243-6.
11. Kekre G, Gupta A, Kothari P, Dikshit V, Patil P, Deshmukh S, *et al.* Congenital facial teratoma in a neonate: Surgical management and outcome. *Ann Maxillofac Surg* 2016;6:141-3.
12. Fei Z, Zhang X, Jiang XF, Liu WP, Wang XL, Xie L. Removal of large benign cephalonasal tumours by transbasal surgery combined with endonasal endoscopic sinus surgery and neuronavigation. *J Craniomaxillofac Surg* 2007;35:30-4.