

Ultrasound guided pulsed radiofrequency ablation of the femoral branch of genito-femoral nerve for entrapment following abdominal-inguinal surgery

Sir,

Chronic post-herniorrhaphy inguinal pain (CPIP) is a pain arising or persisting 3–6 months after herniorrhaphy due to entrapment of ilioinguinal, iliohypogastric and genital branch of genitofemoral nerve (GFN) in the inguinal-canal or femoral branch of GFN, lateral-femoral cutaneous nerve and femoral nerve in the pre-peritoneal space.^[1] Conventional treatment includes pharmacotherapy and local-anaesthetic/steroid injections. Pulsed radiofrequency (PRF)-ablation of the femoral branch is not described to date.

A 29-year-old female patient, underwent left salpingo-oophorectomy for adnexal mass along with right inguinal mesh-hernia repair via a midline incision. Four months later, she complained of pain in the mid-anterior thigh just below inguinal-ligament on the right-side. The pain was continuous, sharp-shooting, current-like, and not relieved with anticonvulsants and antidepressants. Her numerical-pain-rating-scale (NRS) score was 8/10. Since her pain was limited to the distribution of the femoral branch of GFN, ultrasound (US)-guided diagnostic nerve block was planned for her. A written consent was obtained and the procedure was performed in the pain-clinic procedure-room under aseptic precautions. US-scanning was performed with the patient supine, using linear US-probe 13–6 MHz (Fujifilm Sono-Site Edge Inc; USA), placed horizontally below the inguinal-ligament. Femoral vessels were identified, femoral artery (FA) was traced cephalad to supra-inguinal level to identify the external-iliac artery (EIA) and femoral branch of GFN was identified just lateral to EIA. After infiltration with 2ml-1%lignocaine, a 22G-Quinke-needle was inserted using in-plane approach, from lateral to medial to reach the target nerve. When the patient complained of sharp, shooting pain concordant with index pain, 2ml-2%lignocaine was injected and the

patient had significant pain relief (90%) 5 minutes after the procedure, which persisted for 6 hours.

Since neuralgia of the femoral branch of GFN was diagnosed, the patient was planned for PRF-ablation on the nerve the next day. The procedure was performed under aseptic precautions after obtaining written consent, attaching standard monitors and procuring intravenous access. Using the same linear US-probe, the femoral branch of GFN was identified as described previously [Figure 1]. After skin infiltration with 2 ml-1% lignocaine, Cosman-radiofrequency (RF) cannula (22G, 10 cm, 10 mm-active tip) was inserted by in-plane approach in lateral to the medial direction [Figure 2]. Once the cannula tip was positioned close to the nerve, the stylet was replaced with RF-electrode, connecting it to RF-generator (COSMAN-RFG-1B; COSMAN®, CosmanMedical Inc., Massachusetts, USA). The final tip-position was confirmed when sensory stimulation at 50 Hz, 0.5 V produced pain concordant to index pain. Motor response at 2 Hz, 2 V was negative. After injecting 2ml-1%lignocaine, two cycles of PRF were performed-120 seconds each (40-60 V; 2 Hz-active pulse width 20 milliseconds; 42°C). She reported complete pain relief (NRS-0/10) after 20 hours, oral medications were tapered and stopped after 14 days. She has been completely pain-free for the last 8 months.

The genitofemoral nerve arises from lumbar-plexus-L1L2 and descends in the psoas muscle, emerges on its medial border at-L3L4 and divides into two branches. Genital branch enters the deep-inguinal-ring and runs with spermatic-cord/

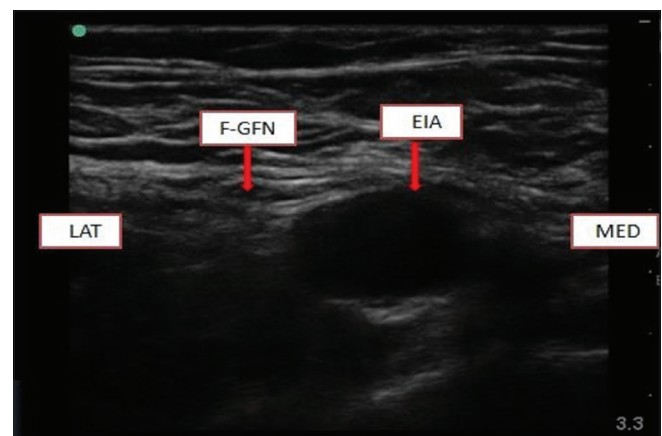


Figure 1: Ultrasonographic image showing Femoral branch of Genitofemoral nerve lateral to external iliac artery at supra-inguinal level. F-GFN: Femoral branch of genitofemoral nerve, EIA: External iliac artery, MED: Medial side, LAT: Lateral side

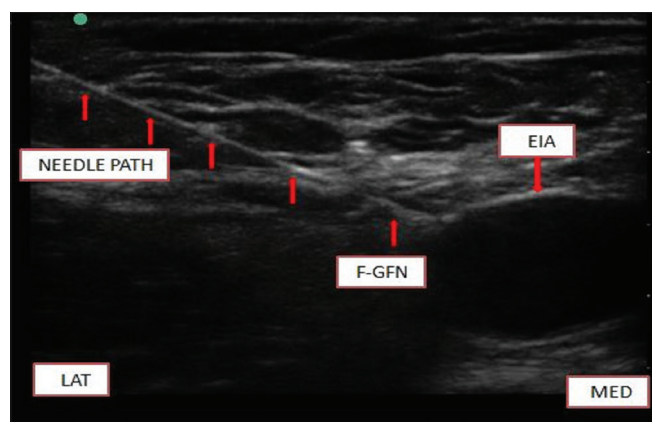


Figure 2: Ultrasonographic image showing needle path from lateral to medial side with needle tip adjacent to the femoral branch of genitofemoral nerve. F-GFN: Femoral branch of genitofemoral nerve, EIA: External Iliac Artery, MED: medial side, LAT: Lateral side

round-ligament to provide motor-innervation to the cremaster and sensation to the skin of upper-scrotum in males and mons-pubis/labia-majora in females. The femoral branch descends lateral to EIA passing below the inguinal-ligament, entering the femoral sheath lateral to FA and supplying the skin of the upper-anterior thigh.^[2]

Entrapment of the femoral branch of GFN after herniorrhaphy is quite rare. Steroids with local-anaesthetic agents have been successfully injected for chronic groin-pain, but have a temporary effect. RF ablation is a promising option in interventional pain practice. Conventional-RF (CRF) causes thermal nerve destruction at high temperatures, providing definitive pain relief, but cannot be used in peripheral nerves carrying motor fibres. In PRF-ablation, heat is turned to pulsed-mode and neuroablation effect is increased. PRF selectively targets C-fibres, avoids myelinated-fibers and can be safely applied to peripheral nerves carrying sensory-motor fibres.^[3,4]

The mechanism of action of PRF is temperature independent neuromodulation effect caused by a rapidly changing electric-field.^[5,6] PRF does not cause any long-term permanent damage to the nerve, hence we used it. It has been used by a few authors for neuralgia of the genital branch of GFN in cases of chronic post-surgical groin pain.^[6,7] However, PRF of the femoral branch has not been reported previously.

Thus to conclude, neuralgia of the femoral branch of GFN rarely occurs after herniorrhaphy. PRF ablation can be used as a safe modality for long-term pain relief for such neuralgias, however large interventional trials would be needed to validate its use.

Declaration of patient consent

The authors certify that they have obtained all appropriate patient consent forms. In the form the patient has given her consent for her images and other clinical information to be reported in the journal. The patient understands that her name and initials will not be published and due efforts will be made to conceal her identity, but anonymity cannot be guaranteed.

Financial support and sponsorship

Nil.

Conflicts of interest

There are no conflicts of interest.

Neha Pangasa, Virender K. Mohan

Department of Anaesthesiology, Pain Medicine and Critical Care, All India Institute of Medical Sciences, New Delhi, India

Address for correspondence:

Dr. Neha Pangasa,
Department of Anaesthesiology, Pain Medicine and Critical Care,
Room No-5011, 5th Floor, Teaching Block, All India Institute of
Medical Sciences, New Delhi - 110 029, India.
E-mail: nehapangasa@gmail.com

Submitted: 15-Aug-2021

Revised: 07-Nov-2021

Accepted: 02-Mar-2022

Published: 24-Mar-2022

REFERENCES

1. Graham DS, MacQueen IT, Chen DC. Inguinal neuroanatomy: Implications for prevention of chronic post inguinal hernia pain. *Int J Abdom Wall Hernia Surg* 2018;1:1-8.
2. Gindha GS, Arora D, Kaushal, Chhabra U. Variations in origin of the genitofemoral nerve from the lumbar plexuses in north Indian population (a cadaveric study). *MOJ Anat Physiol* 2015;1:72-6.
3. Vatansever D, Tekin I, Tuglu I, Erbuyun K, Ok G. A Comparison of the neuroablative effects of conventional and pulsed radiofrequency techniques. *Clin J Pain* 2008;24:717-24.
4. Gowler VS, Goswami S. Pulsed radiofrequency ablation of stellate ganglion for chronic facial pain. *Indian J Anaesth* 2020;64:1091-2.
5. Punj J, Srivastava M. Prolonged relief of chronic pelvic pain by pulsed radiofrequency ablation of superior hypogastric plexus performed under ultrasound guidance: A case report. *Indian J*

Anaesth 2020;64:816-7.

6. Hetta DF, Mahran AM, Kamal EE. Pulsed radiofrequency treatment for chronic post-surgical orchialgia: A double-blind sham-controlled randomized trial: Three-month results. Pain Physician 2018;21:199-205.
7. Cohen SP, Foster A. Pulsed radiofrequency as a treatment for groin pain and orchialgia. Urology 2003;61:645xxi-xxiii.

This is an open access journal, and articles are distributed under the terms of the Creative Commons Attribution-NonCommercial-ShareAlike 4.0 License, which allows others to remix, tweak, and build upon the work non-commercially, as long as appropriate credit is given and the new creations are licensed under the identical terms.

Access this article online	
Quick response code	Website: www.ijaweb.org
	DOI: 10.4103/ija.ija_762_21

How to cite this article: Pangasa N, Mohan VK. Ultrasound guided pulsed radiofrequency ablation of femoral branch of genito-femoral nerve for entrapment following abdominal-inguinal surgery. Indian J Anaesth 2022;66:233-5.

© 2022 Indian Journal of Anaesthesia | Published by Wolters Kluwer - Medknow