

# Three stitch hernioplasty: A novel technique for beginners

Manikandan Patchayappan, Sangara Narayanan Narayanasamy<sup>1</sup>, Nagarajan Duraisamy

Department of General Surgery, Thanjavur Medical College and Hospital, Thanjavur, <sup>1</sup>Department of General Surgery, Stanley Medical College and Hospital, Chennai, Tamil Nadu, India

## Access this article online

Website: [www.avicennajmed.com](http://www.avicennajmed.com)

DOI: 10.4103/2231-0770.166891

## Quick Response Code:



## ABSTRACT

**Objective:** To analyze mesh fixation with minimum sutures and postoperative complications. **Study Design:** Prospective study. **Place and Duration of Study:** Department of General Surgery, Thanjavur Medical College and Hospital, Tamil Nadu, from July 2010 to June 2012. **Materials and Methods:** All inguinal hernia patients, who fulfilled the sample selection criteria, were admitted and planned for surgery. The prolene mesh is fashioned as in Lichtenstein's repair, placed and fixed only by three prolene stitches. The first stitch is made in the periosteum of pubic tubercle. The second stitch is taken in the inguinal ligament (1.5 cm lateral to the pubic tubercle) and the third stitch is from the medial most part of the conjoint tendon, that is, the mesh is fixed in the medial aspect alone. **Results:** Majority of the patients fall between the age group of 40 and 60 (72%) years and all are male patients. Of the total cases, 50% were right sided, 25% were left sided, and 25% were bilateral. Of the postoperative complications, 12% had seroma, 4% had hematoma, 2% developed surgical site infection, 2% developed chronic groin pain, 1% presented with recurrence, and none developed foreign body sinus. **Conclusion:** The incidence of long-term complications of three stitch hernioplasty are comparable to that of the other standard, tension-free open hernia repair as well as other laparoscopic procedures. Moreover, the three stitch hernioplasty method is a simple method, easy for the beginners to adopt, has less foreign body reaction, less time consuming, causes less tissue trauma, and lesser chance for vascular injury.

**Key words:** Postoperative complications, prolene sutures, three stitch hernioplasty

## INTRODUCTION

Prosthetic meshes are routinely used to repair abdominal wall hernias.<sup>[1-3]</sup> Several techniques are used for mesh implantation, but most involve sutures to anchor a mesh in position thereby preventing migration, wrinkling, and curling. Suture placement is time consuming and often challenging.<sup>[4]</sup> In addition, these sutures cause extensive tissue tension, predisposition to infection, and nerve entrapment, causing prolonged postoperative pain.<sup>[5-7]</sup> Even the application of absorbable sutures instead of the nonabsorbable ones does not solve the problem.<sup>[5]</sup> In order to avoid the above disadvantages, it was proposed that polypropylene mesh be applied with less or without suture fixation to the surrounding

tissue.<sup>[8]</sup> The aim of the study is to analyze mesh fixation with minimum sutures and on its recurrence.

## MATERIALS AND METHODS

Patients between 20 and 60 years, who were referred to our institute for elective inguinal hernia repair from July 2010 to June 2012, were enrolled in the study after signing an informed consent. Exclusion criteria included the following: Patients more than 60 years, recurrent hernia, sliding hernia, obstructed

This is an open access article distributed under the terms of the Creative Commons Attribution-NonCommercial-ShareAlike 3.0 License, which allows others to remix, tweak, and build upon the work non-commercially, as long as the author is credited and the new creations are licensed under the identical terms.

**For reprints contact:** [reprints@medknow.com](mailto:reprints@medknow.com)

**Cite this article as:** Patchayappan M, Narayanasamy SN, Duraisamy N. Three stitch hernioplasty: A novel technique for beginners. *Avicenna J Med* 2015;5:106-9.

**Address for correspondence:** Dr. Sangara Narayanan Narayanasamy, No: 86, Maariamman Koil Street, Muthupillaipalayam, Puducherry, India.  
E-mail: [shankarmgmc67@yahoo.co.in](mailto:shankarmgmc67@yahoo.co.in)

and strangulated hernia, bladder outlet obstruction, lower respiratory infection/chronic obstructive pulmonary disease, and ischemic heart disease. Hundred inguinal hernia patients who fulfilled the sample selection criteria were admitted at Thanjavur Medical College and Hospital and was planned for surgery. For all these patients, the usual Lichtenstein's repair was not done, but a slightly modified procedure, three stitch hernioplasty, was done after getting their consent.

### Surgical technique

Three stitch hernioplasty was done with general or spinal anesthesia under antibiotic (cephalosporin 1 dose intravenous) and thromboembolic prophylaxis (low fractionated heparin subcutaneous). In this procedure, the following steps were carried out. By parainguinal incision, skin was incised and deepened to reach the external oblique aponeurosis after ligating the three named superficial subcutaneous veins. External oblique aponeurosis cut was opened along the direction of its fibers. A plane of cleavage is created between the external oblique aponeurosis and the conjoint tendon superiorly. The inguinal ligament is well defined by dissecting the floor of inguinal canal. The cremasteric muscle with cord structures is hooked out. Ilioinguinal nerve is preserved to avoid entrapment and chronic pain in the postoperative period.

Small, direct hernial sac, if present (medial to the inferior epigastric artery) must be invaginated by opposing the fibers of transversalis fascia. For large, direct hernias, the sac is opened and the transversalis fascia is repaired. In the case of indirect inguinal hernia, the sac is cut open at the fundus and the contents, if any must be reduced. Sac is transfixed at its neck and the excess sac was excised. Wide, deep ring is narrowed by suture ligation (Lytle's repair).

Now, the prolene mesh is fashioned as in Lichtenstein's repair, placed and fixed only by three prolene stitches. The first stitch is made in the periosteum of pubic tubercle. The second stitch is taken in the inguinal ligament (1.5 cm lateral to pubic tubercle) and the third stitch is from the medial most part of the conjoint tendon, that is, the mesh is fixed in the medial aspect alone [Figure 1]. Hemostasis is achieved and wound was closed in layers. Postoperatively, the patients were treated with antibiotics and analgesics and were discharged home as soon as they feel comfortable. Follow-up was scheduled at 1-week, 1-month, 3 months, 6 months, 12 months, and 24 months after surgery. In the follow-up, the patients were assessed for the development of any seroma, hematoma, wound infection, chronic groin pain, recurrence, foreign body sinus, and early return to work. Chronic groin pain (can be mild or severe) is defined as the presence of pain, discomfort, or

hypersensitivity (not present before surgery) existing for more than 3 months after the surgery. Pain assessment was carried out by Visual Analog Scale (VAS) score with a score of <1 as mild, between 1 and 5 as moderate, and >5 as severe pain.

## RESULTS

Analysis of the patient's findings showed that majority of the patients fall between the age group of 40 and 60 (72%) years and all are male patients. Of the total cases, 50% were right sided, 25% were left sided, and 25% were bilateral. Of the postoperative complications, 12% had seroma, 4% had hematoma, 2% developed surgical site infection, 2% developed chronic groin pain, 1% presented with recurrence, and none developed foreign body sinus. Low levels of postoperative pain and low complication rates were allowed for prompt physical recovery. The patients resumed their daily home activities within 2 (1-4) weeks of the operation. The operative time was found to be  $95 \pm 32$  min [Tables 1-7].

## DISCUSSION

As inguinal hernia is a very common problem, innovations in the surgical intervention are developing day by day in

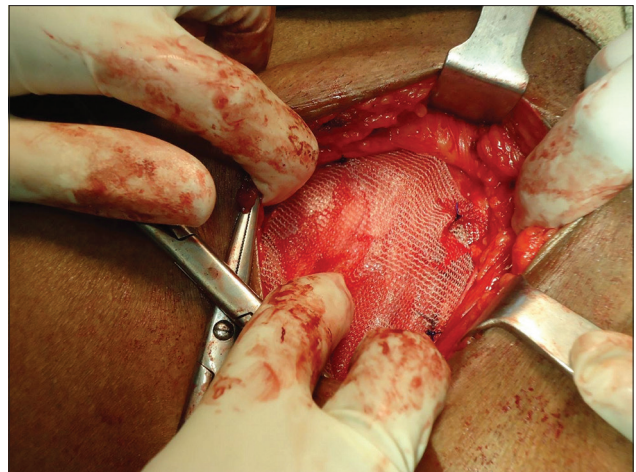


Figure 1: Intraoperative picture showing the position of three stitch hernioplasty

Table 1: Distribution of age among the study participants

Age (years)	Percentage
21-30	18
31-40	10
41-50	24
51-60	48

Table 2: Gender distribution among the study participants

Sex	Number (n)	Percentage
Males	100	100
Females	0	0

**Table 3: Distribution of study participants according to the side of hernia**

Side of hernia	Percentage
Right	50
Left	25
Bilateral	25

**Table 4: Postoperative complications among the study participants**

Postoperative complications	Percentage
Seroma	12
Hematoma	04
Wound infection	02
Chronic groin pain	02
Recurrence	01
Foreign body fistula formation	00

**Table 5: Postoperative complications**

	Percentage
Seroma	12
Hematoma	04
Wound infection	02
Chronic groin pain	02
Recurrence	01
Foreign body fistula formation	00

**Table 6: Visual Analog Scale score**

0	No pain
1-3	Mild pain
4-6	Moderate pain
7-9	Strong pain
10	Very strong pain

**Table 7: Distribution of study participants according to the type of hernia**

Type of hernia	Percentage
Direct	04
Indirect	67
Bilateral	25

order to benefit the patients by reducing the operative time and postoperative complications. Although the laparoscopic approach for hernia repair is gaining popularity, the open technique remains the operation of choice for beginners. Our goal is to assess the safety and efficacy of three stitch hernioplasty technique before a large randomized prospective study is designed to compare the results of this technique with other current approaches.

The three stitch hernioplasty technique takes advantage of the rigidity, flat-shape memory, and good adhesive features of the mesh placed in the closed anatomical space, which prevents wrinkling, curling, folding, and mesh migration. Compared to Lichtenstein's tensionless repair, the three stitch hernioplasty procedure has several practical and clinical advantages. First,

minimal anchoring of the mesh to the surrounding tissue allows the surgeon to save work, thus, decreasing the time of the operation and the level of technical difficulty. The surgical dissection is limited, making the procedure less traumatic for the tissue and the patient and minimizing the predisposition for infection. The average time of the entire operation (1 h) was similar to those obtained when using Stoppa Repair or the laparoscopic approach.<sup>[4,9]</sup>

When the soft polypropylene mesh is sutured in the Rives-Stoppa technique, malformation of the mesh tension can lead to dead space formation and subsequent chronic fluid collection, hematomas, or infections. Therefore, the theoretical risk of such complications should be lowered in the three stitch technique since flat-shape-memory mesh lies flat without tension caused by fixation to the surrounding tissue.

The high level of postoperative pain at the wound and also at the edges of the prosthesis due to tissue damage and tension prolongs patient recovery.<sup>[5]</sup> As per Lichtenstein *et al.*,<sup>[10]</sup> in a study performed in 1988, the incidence of chronic groin pain is 1–2%. In another study conducted in 104 patients treated by laparoscopic hernia repair by Pantou and Pantou in 1994, the incidence of the chronic groin pain is only 1%. In this study, the incidence of chronic groin pain is 2%. In a study conducted in Armed Force Medical College in 2010 by S.S. Jaiswal, R. Chaudhry, A. Agarwal<sup>[11]</sup> concluded that meticulous identification and preservation of the nerves, using absorbable suture for fixation and minimum number of sutures to fix a mesh contributed a low incidence of chronic groin pain. In our study, VAS score was checked at 1-week, 1-month, 3 months, 6 months, 12 months, and 24 months.

The two patients who had chronic groin pain at the end of 3 months had VAS score 1–3 (mild pain).

Recurrence rate in any meticulously done tension-free mesh repair or Shouldice method of hernia repair is < 2%. The recurrence rate in our study is 1%, but the study was conducted only for 2 years. Only 50% of recurrence will occur in the first 2 years, and hence a minimum of 5 years of follow-up is necessary to know the efficacy of the type of hernioplasty done in our study. The patient who developed recurrence in our study was a diabetic with a large defect, thinned out musculo-aponeurotic fibres, and postoperative wound infection. The patient developed recurrence after 1-year and 5 months of hernia surgery.

Methods are designed to modify inguinal hernia repair and to decrease operating time as well as the postoperative complications such as pain, surgical site infection and

hematoma, and seroma formation. This study was designed to compare the conventional mesh fixation over three stitch in terms of mean operating time and frequency of postoperative pain. Mean operating time leads to a rapid turnover of the patients. Moreover, reduced operating time has a direct implication on the working capacity of the surgeon, that is, the efficiency of the surgeon is increased. Postoperative pain is reduced if less sutures are used to anchor the mesh in inguinal hernioplasty. Decreased pain reduces stress on the patients and hastens their recovery. Quick recovery leads to early return to work and reduced work-loss days. This is an important implication not only on the natural well-being but also on the monetary aspect of the patients.

## CONCLUSION AND SUMMARY

The incidence of long-term complications of three stitch hernioplasty are comparable to that of other standard tension-free open hernia repair as well as other laparoscopic procedures. However, the only limitation that we have in our study is the duration of follow-up. Moreover, the three stitch hernioplasty method is a simple method, easy for the beginners to adopt, has less foreign body reaction, less time consuming, causes less tissue trauma, and lesser chance for vascular injury.

### Financial support and sponsorship

Nil.

### Conflicts of interest

There are no conflicts of interest.

## REFERENCES

1. Millikan KW. Incisional hernia repair. *Surg Clin North Am* 2003;83:1223-34.
2. Burger JW, Luijendijk RW, Hop WC, Halm JA, Verdaasdonk EG, Jeekel J. Long-term follow-up of a randomized controlled trial of suture versus mesh repair of incisional hernia. *Ann Surg* 2004;240:578-83.
3. Arroyo A, García P, Pérez F, Andreu J, Candela F, Calpena R. Randomized clinical trial comparing suture and mesh repair of umbilical hernia in adults. *Br J Surg* 2001;88:1321-3.
4. Conze J, Kingsnorth AN, Flament JB, Simmermacher R, Arlt G, Langer C, *et al.* Randomized clinical trial comparing lightweight composite mesh with polyester or polypropylene mesh for incisional hernia repair. *Br J Surg* 2005;92:1488-93.
5. Martín-Duce A, Noguerales F, Villeta R, Hernández P, Lozano O, Keller J, *et al.* Modifications to Rives technique for midline incisional hernia repair. *Hernia* 2001;5:70-2.
6. LeBlanc KA. Laparoscopic incisional and ventral hernia repair: Complications-how to avoid and handle. *Hernia* 2004;8:323-31.
7. Morales-Conde S, Cadet H, Cano A, Bustos M, Martín J, Morales-Mendez S. Laparoscopic ventral hernia repair without sutures – Double crown technique: Our experience after 140 cases with a mean follow-up of 40 months. *Int Surg* 2005;90 3 Suppl: S56-62.
8. Abbonante F, Witkowski P. Early results of tension free sutureless ventral hernia repair. Orlando, FL: American Hernia Society Congress; 2004.
9. Lomanto D, Iyer SG, Shabbir A, Cheah WK. Laparoscopic versus open ventral hernia mesh repair: A prospective study. *Surg Endosc* 2006;20:1030-5.
10. Eklund AS, Montgomery AK, Rasmussen IC, Sandbue RP, Bergkvist LA, Rudberg CR. Low recurrence rate after laparoscopic (TEP) and open (Lichtenstein) inguinal hernia repair: A randomized, multicenter trial with 5-year follow-up. *Ann Surg* 2009;249:33-8.
11. Jaiswal SS, Chaudhry R, Agarwal A. Chronic groin pain following Lichtenstein mesh hernioplasty for inguinal hernia. Is it a myth? *Indian J Surg* 2009;71:84-8.