



Case Report

Atypical presentation of bladder pheochromocytoma

Chen-Yueh Wen^{a,b}, Chung-Tai Yu^{b,c}, Cheng-Hsing Hsieh^{a,b*}

^aDepartment of Urology, Taipei Tzu Chi Hospital, Buddhist Tzu Chi Medical Foundation, New Taipei, Taiwan, ^bSchool of Medicine, Tzu Chi University, Hualien, Taiwan, ^cDepartment of Pathology, Taipei Tzu Chi Hospital, Buddhist Tzu Chi Medical Foundation New Taipei, Taiwan

Received : 28-06-2016

Revised : 02-08-2016

Accepted : 13-10-2016

ABSTRACT

Bladder pheochromocytoma is a rare tumor. The typical manifestations are hematuria, hypertension, headache, sweating, and tachycardia provoked by micturition or overdistention of the bladder. We herein report a case of bladder pheochromocytoma in a 52-year-old woman who presented without micturition attacks. Her clinical course had a latent period of 10 years. A urinary bladder tumor was found incidentally on *magnetic resonance imaging*. *Cystoscopy* revealed a large submucosal tumor covered by congested urothelium with a broad base over the left lateral wall of the bladder. Transurethral resection was performed, and the final diagnosis was confirmed by pathological analysis. The patient remained recurrence free after 7-year follow-up.

KEYWORDS: *Cystoscopy, Pheochromocytoma, Transurethral resection, Tumor, Urinary bladder*

INTRODUCTION

Pheochromocytoma is a catecholamine-secreting tumor that originates from the chromaffin tissue of the adrenal medulla and the sympathetic ganglia. The average annual incidence rate is 0.8/100,000 person-years [1,2]. Pheochromocytoma originates from the adrenal gland in 85%–90% of patients, with only approximately 10%–15% from extra-adrenal glands [3]. Extra-adrenal pheochromocytomas (EAPs) are malignant in 30%–40% of adults compared with <2% in children [4]. Bladder pheochromocytoma is rare, and the typical manifestations are hematuria, hypertension, headache, and palpitations during micturition [5]. We herein report a case of bladder pheochromocytoma with an atypical presentation which was incidentally identified.

CASE REPORT

A 52-year-old woman presented with episodes of a sudden onset of palpitations, chest tightness, headache, and numbness in the four limbs, which first manifested more than 10 years ago. At that time, the episodes lasted from a few seconds to more than 20 min and occurred up to five times a day. However, the symptoms subsided and fluctuated in severity over a period of 10 years. She had no history of arrhythmia

or hypertension. She had visited a neurologist, cardiologist, psychiatrist, and a general practitioner without improvement. In 2009, she suffered from right hip pain, and a urinary bladder mass was incidentally identified on magnetic resonance imaging (MRI) in an outside institution. The mass had heterogeneous high mid-signal intensity on T1-weighted images [Figure 1a] and mid-signal intensity on T2-weighted images [Figure 1b]. She was transferred to our hospital for further evaluation. She denied hematuria, lower urinary tract symptoms, anxiety, or micturition attacks accompanied by headache or palpitations. Her blood pressure and heart rate were normal. Urinalysis showed no abnormalities. Cystoscopy revealed a bulging mass with a broad base over the left lateral wall of the bladder [Figure 2]. Computed tomography (CT) of the abdomen demonstrated a mass up to 2.4 cm in the greatest dimension over the left wall of the bladder [Figure 3]. Transurethral resection of the bladder tumor (TURBT) was performed. Intraoperatively, her blood


*Address for correspondence:

Dr. Cheng-Hsing Hsieh,
Department of Urology, Taipei Tzu Chi Hospital, Buddhist Tzu Chi Medical Foundation, 289, Jianguo Road, Xindian District, New Taipei, Taiwan.
E-mail: kevinchhsieh@yahoo.com

This is an open access article distributed under the terms of the Creative Commons Attribution-NonCommercial-ShareAlike 3.0 License, which allows others to remix, tweak, and build upon the work non-commercially, as long as the author is credited and the new creations are licensed under the identical terms.

For reprints contact: reprints@medknow.com

How to cite this article: Wen CY, Yu CT, Hsieh CH. Atypical presentation of bladder pheochromocytoma. *Tzu Chi Med J* 2017;29:46-9.

Access this article online	
Quick Response Code: 	Website: www.tcmjmed.com
	DOI: 10.4103/tcmj.tcmj_10_17

pressure elevated to 190/110 mmHg during excision of the base of the tumor and decreased to the normal range when the tumor was totally removed. Pathology confirmed the diagnosis of bladder pheochromocytoma. Immunohistochemical stain showed that the tumor cells were positive for chromogranin [Figure 4] and negative for CK7 and CK20. Her symptoms dramatically resolved immediately after surgery. Postoperatively, an endocrine study showed the 24-h urine vanillylmandelic acid was 3.51 mg/24 h (normal range: 1.0–7.5 mg/24 h). The results of surveys of serum calcium, calcitonin, parathyroid hormone, and RET mutation analysis were normal, excluding the diagnosis of multiple

endocrine neoplasia type 2 (MEN2) [6] and confirming she had sporadic pheochromocytoma. Iodine-131 metaiodobenzylguanidine (MIBG) scintigraphy depicted no focal area of increased tracer uptake in the whole body survey. There was no evidence of residual tumor, local recurrence, or distant metastasis during 7-year follow-up.

DISCUSSION

EAP occurs sporadically. More than 85% of these tumors occur below the diaphragm with the para-

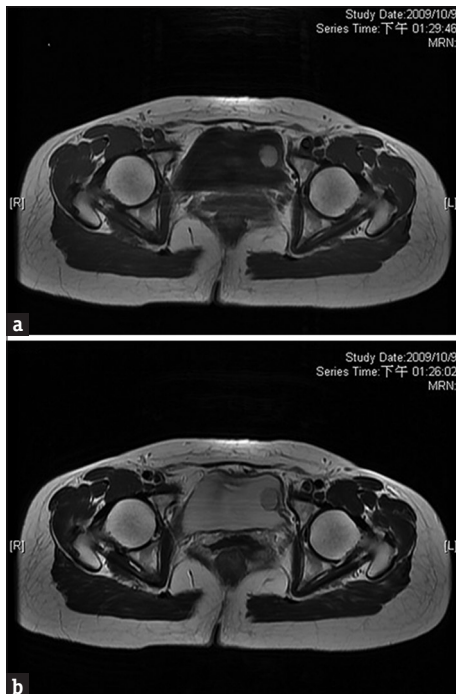


Figure 1: A bladder mass with (a) heterogeneous high-mid signal intensity on T1-weighted imaging as well as (b) mid signal intensity on T2-weighted imaging

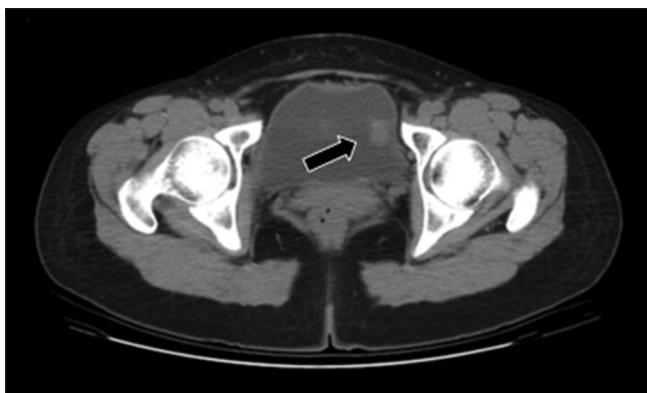


Figure 3: Axial computerized tomography sections reveal a 1.7 cm × 2.4 cm mass (arrow) over the left lateral wall of the bladder with no extravesical invasion

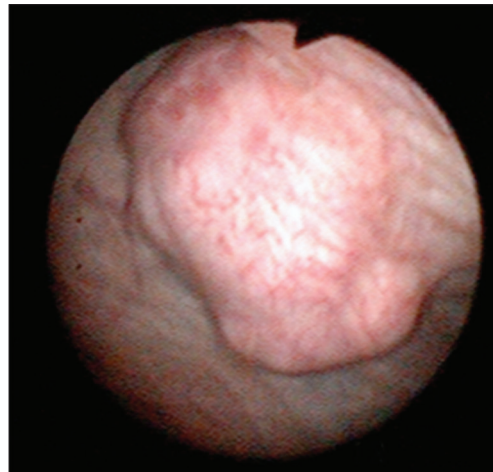


Figure 2: Cystoscopic findings show a bulging mass with marked vascularity over the left lateral wall of the bladder

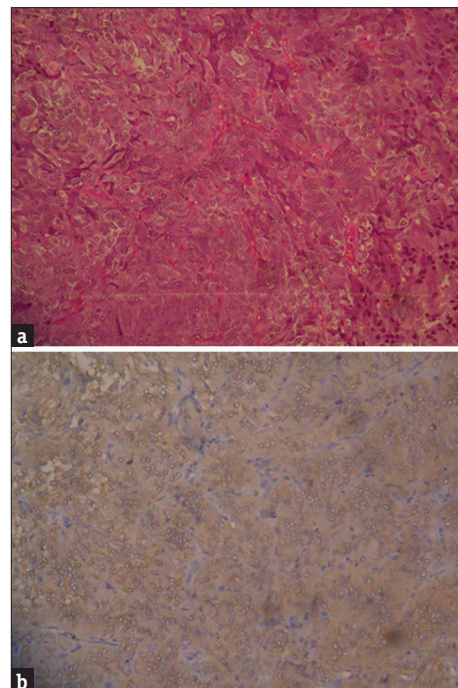


Figure 4: (a) The tumor is composed of cell balls of neoplastic cells with small oval granular nuclei and abundant granular cytoplasm (H and E, ×200). (b) The tumor cells are positive for chromogranin (immunohistochemical, ×200)

aortic region the most common site. Other locations for pheochromocytoma include the gallbladder, urinary bladder, prostate, spermatic cord, uterus, and duodenum. Bladder pheochromocytoma is a rare tumor accounting for <1% of all pheochromocytomas and <0.06% of all bladder tumors [7,8].

Among patients with suspected pheochromocytoma with the triad of headache, sweating, and tachycardia, the diagnosis is typically confirmed by urinary and plasma fractionated metanephrines and catecholamines. However, the typical symptoms of bladder pheochromocytoma are hypertension, headache, hematuria, syncope, and palpitations, usually provoked by micturition or overdistention of the bladder [5]. An image study should be done to locate the tumor. If CT or MRI of the abdomen demonstrates no findings in the presence of clinical and biochemical evidence of pheochromocytoma, I-131 MIBG scintigraphy is an effective modality with high specificity and cost-effectiveness for localizing this catecholamine-producing tumor [2]. MEN2 should also be considered in any patient with pheochromocytoma. The diagnosis of MEN2 is based on family history, clinical symptoms, laboratory data and genetic screening. In our case, the patient had palpitations, chest tightness, headache and numbness in the four limbs initially. Nevertheless, she had a relapse of these symptoms subsequently, without the micturition attacks accompanied by headache and palpitations which are typical in pheochromocytoma. Furthermore, her clinical course had a latent period and she had tolerated the symptoms for 10 years. This atypical presentation could have been erroneously diagnosed as a psychosomatic disorder and clues for identification of bladder pheochromocytoma could have been missed prior to surgery. If she had not had right hip pain and visited an outside institution, the bladder tumor would not have been found incidentally on MRI. The classic imaging feature for pheochromocytomas is a “light-bulb” bright lesion on T2-weighted MRI images, which varies in prevalence ranging from 11% to 65%. On T1-weighted imaging, pheochromocytomas are typically isointense to muscle and hypointense to liver, but are quite variable in appearance if necrosis or hemorrhage is present [9]. However, MRI did not demonstrate these unique feature in our case. Accurate diagnosis can be challenging.

Macroscopically on cystoscopy, typical bladder pheochromocytoma should show granulation and protrusions into the bladder as globular yellowish, submucosal tumors [4]. In our case, cystoscopy revealed a large submucosal tumor covered by congested

urothelium with a broad base. The biopsy was difficult to perform because of the smooth tumor surface. At present, there are no specific pathological criteria for predicting malignancy. According to the World Health Organization criteria, the best indicator of malignant behavior is invasion of adjacent tissue or metastatic spreading. In our case, CT of the abdomen revealed no invasion or metastatic spreading. Hence, it seemed to be a benign tumor.

Treatment of pheochromocytoma includes a variety of methods, such as catecholamine blockade, surgery, chemotherapy, and radiation therapy, while surgical removal remains the mainstream standard treatment for localized or locally advanced [5]. Many experts advocate surgical removal of localized bladder pheochromocytoma originating from the intramural portion of the bladder wall with an open, laparoscopic or robotic partial cystectomy. Several case reports have shown a low rate of recurrence or metastasis after partial cystectomy, illustrating that good symptomatic control and low morbidity can be achieved [10,11]. In comparison with open surgery, laparoscopic surgery offers the advantage of a smaller incision, minimally invasive procedure, less postoperative pain, a faster recovery, and a shorter hospitalization [11].

TURBT is an alternative management, but complete removal of the tumor is considered difficult and it may precipitate a hypertensive crisis or arrhythmia. Chang *et al.* reported benign bladder pheochromocytoma still recurred after TURBT regardless of size or location [12]. However, some urologists still perform TURBT and follow patients periodically for small tumors located at the periureteral orifice. The procedure has the advantage of a shorter period of convalescence compared with other surgical methods. TURBT may result in fluctuation of blood pressure during irrigation with distilled water or normal saline intraoperatively, or with electrical stimulation during resection and cauterization [4,12]. In our case, dramatic intraoperative hypertension was encountered during resection of the remaining half of the tumor. We did not change the procedure, but rather slowed down in conjunction with medication for management of hypertension and the patient showed improvement. The patient remained recurrence-free after a 7-year follow-up. TURBT remains an alternative for the management of bladder pheochromocytoma and may augur well in some cases. However, long-term follow-up is still mandatory to investigate for a recurrence. Pheochromocytomas are often considered great mimickers of other adrenal tumors. It is challenging to identify these tumors because of their varied clinical presentation, imaging, and pathologic appearance. This

report reminds us of the importance of considering different pathologies of bladder tumors before TURBT.

Financial support and sponsorship

Nil.

Conflicts of interest

There are no conflicts of interest.

Declaration of patient consent

The authors certify that the patient have obtained appropriate patient consent form. In the form the patient has given her consent for her images and other clinical information to be reported in the journal. The patient understands that her name and initial will not be published and due efforts will be made to conceal their identity, but anonymity cannot be guaranteed.

REFERENCES

1. Beard CM, Sheps SG, Kurland LT, Carney JA, Lie JT. Occurrence of pheochromocytoma in Rochester, Minnesota, 1950 through 1979. *Mayo Clin Proc* 1983;58:802-4.
2. Bravo EL. Pheochromocytoma: New concepts and future trends. *Kidney Int* 1991;40:544-56.
3. Whalen RK, Althausen AF, Daniels GH. Extra-adrenal pheochromocytoma. *J Urol* 1992;147:1-10.
4. Vyas S, Kalra N, Singh SK, Agarwal MM, Mandal AK, Khandelwal N. Pheochromocytoma of urinary bladder. *Indian J Nephrol* 2011;21:198-200.
5. Beilan JA, Lawton A, Hajdenberg J, Rosser CJ. Pheochromocytoma of the urinary bladder: A systematic review of the contemporary literature. *BMC Urol* 2013;13:22.
6. Siqueira DR, Ceolin L, Ferreira CV, Romitti M, Maia SC, Maciel LM, et al. Role of RET genetic variants in MEN2-associated pheochromocytoma. *Eur J Endocrinol* 2014;170:821-8.
7. Melicow MM. One hundred cases of pheochromocytoma (107 tumors) at the Columbia-Presbyterian Medical Center, 1926-1976: A clinicopathological analysis. *Cancer* 1977;40:1987-2004.
8. Leestma JE, Price EB Jr. Paraganglioma of the urinary bladder. *Cancer* 1971;28:1063-73.
9. Leung K, Stamm M, Raja A, Low G. Pheochromocytoma: The range of appearances on ultrasound, CT, MRI, and functional imaging. *AJR Am J Roentgenol* 2013;200:370-8.
10. Nayyar R, Singh P, Gupta NP. Robotic management of pheochromocytoma of the vesicoureteric junction. *JSLs* 2010;14:309-12.
11. Huang Y, Tian XJ, Ma LL. Pre-peritoneal laparoscopic partial cystectomy of the bladder pheochromocytoma. *Chin Med J (Engl)* 2009;122:1234-7.
12. Chang YK, Chiang IN, Chen CH, Wang SM, Lee YJ, Pu YS, et al. Paragangliomas of the urinary bladder: A report of 6 cases and review of the literature. *Urol Sci* 2015;26:111-4.