



# Utilization of a three-dimensional printed kidney model for favorable TRIFECTA achievement in early experience of robot-assisted partial nephrectomy

Akira Fujisaki<sup>1^</sup>, Tatsuya Takayama<sup>1</sup>, Masahiro Yamazaki<sup>1</sup>, Tomoki Kamimura<sup>2</sup>, Saki Katano<sup>1</sup>, Maiko Komatsubara<sup>1</sup>, Jun Kamei<sup>1</sup>, Toru Sugihara<sup>1</sup>, Satoshi Ando<sup>1</sup>, Tetsuya Fujimura<sup>1</sup>

<sup>1</sup>Department of Urology, Jichi Medical University, Shimotsuke, Tochigi, Japan; <sup>2</sup>Department of Radiology, Jichi Medical University Hospital, Shimotsuke, Tochigi, Japan

**Contributions:** (I) Conception and design: A Fujisaki, T Takayama; (II) Administrative support: T Takayama, T Fujimura; (III) Provision of study materials or patients: A Fujisaki, M Yamazaki, T Takayama, T Kamimura; (IV) Collection and assembly of data: A Fujisaki, M Yamazaki, T Takayama, T Kamimura; (V) Data analysis and interpretation: All authors; (VI) Manuscript writing: All authors; (VII) Final approval of manuscript: All authors.

**Correspondence to:** Tatsuya Takayama, MD, PhD. Department of Urology, Jichi Medical University 3311-1 Yakushiji, Shimotsuke city, Tochigi 329-0498, Japan. Email: ttakayam@jichi.ac.jp.

**Background:** This retrospective study aimed to investigate whether a three-dimensional (3D) model would improve the achievement of TRIFECTA, which was defined as the absence of perioperative complications and positive surgical margins and a warm ischemia time of <25 minutes, during robot-assisted partial nephrectomy (RAPN).

**Methods:** Prior to RAPN, a 3D-square type kidney model was prepared and used for all RAPN procedures in patients with T1a renal cell carcinoma (RCC) treated at a single center between March 2016 and April 2019. All RAPN procedures were performed by a single surgeon.

**Results:** The study included 50 patients, of whom 22, 24, and 4 had low-, intermediate-, and high-risk R.E.N.A.L Nephrometry scores, respectively. The TRIFECTA achievement rate was 86.0%, and transfusion or conversion to radical nephrectomy was not required in any of the patients. Only one Clavien-Dindo grade 3 complication was reported—a pseudoaneurysm that required embolism. The TRIFECTA achievement rate was independent of the R.E.N.A.L Nephrometry scores and the surgeon's experience level (25 cases each of early and advanced experience).

**Conclusions:** The 3D model contributed to the achievement of TRIFECTA during RAPN performed by a less-experienced surgeon. These findings should be further evaluated in studies involving a larger number of cases and surgeons.

**Keywords:** Robot-assisted partial nephrectomy (RAPN); three-dimensional; kidney model; TRIFECTA

Submitted Jun 11, 2020. Accepted for publication Sep 25, 2020.

doi: 10.21037/tau-20-927

**View this article at:** <http://dx.doi.org/10.21037/tau-20-927>

## Introduction

Partial nephrectomy is the current gold-standard procedure for the treatment of small renal masses. Since its introduction, robot-assisted partial nephrectomy

(RAPN) has rapidly become well-established and widely used. During RAPN, it is important to recognize the relationships between positions of the renal artery and vein, tumor and urinary tract, and the depth of the tumor. Even during initial experiences with this procedure, an

<sup>^</sup> ORCID: 0000-0001-5204-2358.

accurate understanding of these anatomical structures can enable reductions in the warm ischemic time (WIT), positive surgical margins, and range of resection, which will subsequently help to spare renal function.

Some studies have reported the development and use of three-dimensional (3D) printed models for RAPN (1-6). Although these models are useful for patient education, preoperative planning, and training, limited reports have discussed the effects of their use on clinical outcomes. In a report using 3D-printed soft-tissue physical models as preoperative simulation in 7 cases, it was also reported that bleeding was reduced (3). In this study, we describe the creation of a novel, simple, and inexpensive 3D-printed model of the kidney that contains the minimal anatomical information required for RAPN (e.g., the tumor, artery, vein, and urinary tract) (7). We aimed to determine the usefulness of this model during initial experience with RAPN and whether its use would contribute to the achievement of TRIFECTA, defined as the absence of perioperative complications, positive surgical margins, and a WIT of <25 min.

We present the following article in accordance with the STROBE reporting checklist (available at <http://dx.doi.org/10.21037/tau-20-927>) (8,9).

## Methods

### Patients

This retrospective study included all cases of RAPN performed by a single surgeon (TT) at Jichi Medical University Hospital between March 2016 and April 2019. During this period, all RAPN procedures were performed to treat patients with diagnosed clinical T1a renal cell carcinoma (RCC). The following data were collected from medical records of the patients: age, sex, body mass index (BMI), tumor side, tumor size, and R.E.N.A.L. nephrometry scores (10). All patients who were diagnosed with clinical T1a RCC were included in this study, and there were no exclusion criteria. There were 2 cases with a single kidney after nephrectomy. Chronic kidney disease, defined as an estimated glomerular filtration rate (eGFR) <60 mL/min/1.73 m<sup>2</sup>, was seen in 24.0% of cases.

Fifty cases before the surgeon started the second-generation surgical instruction were set as initial cases and analyzed.

The study was conducted in accordance with the Declaration of Helsinki (as revised in 2013) and the

Harmonized Tripartite Guideline for Good Clinical Practice from the International Conference on Harmonization. This study was reviewed and approved by the Institutional Research Review Boards of Jichi Medical University with an opt-out system (No. A19-097). Written informed consent was obtained from all patients.

### Three-dimensional model

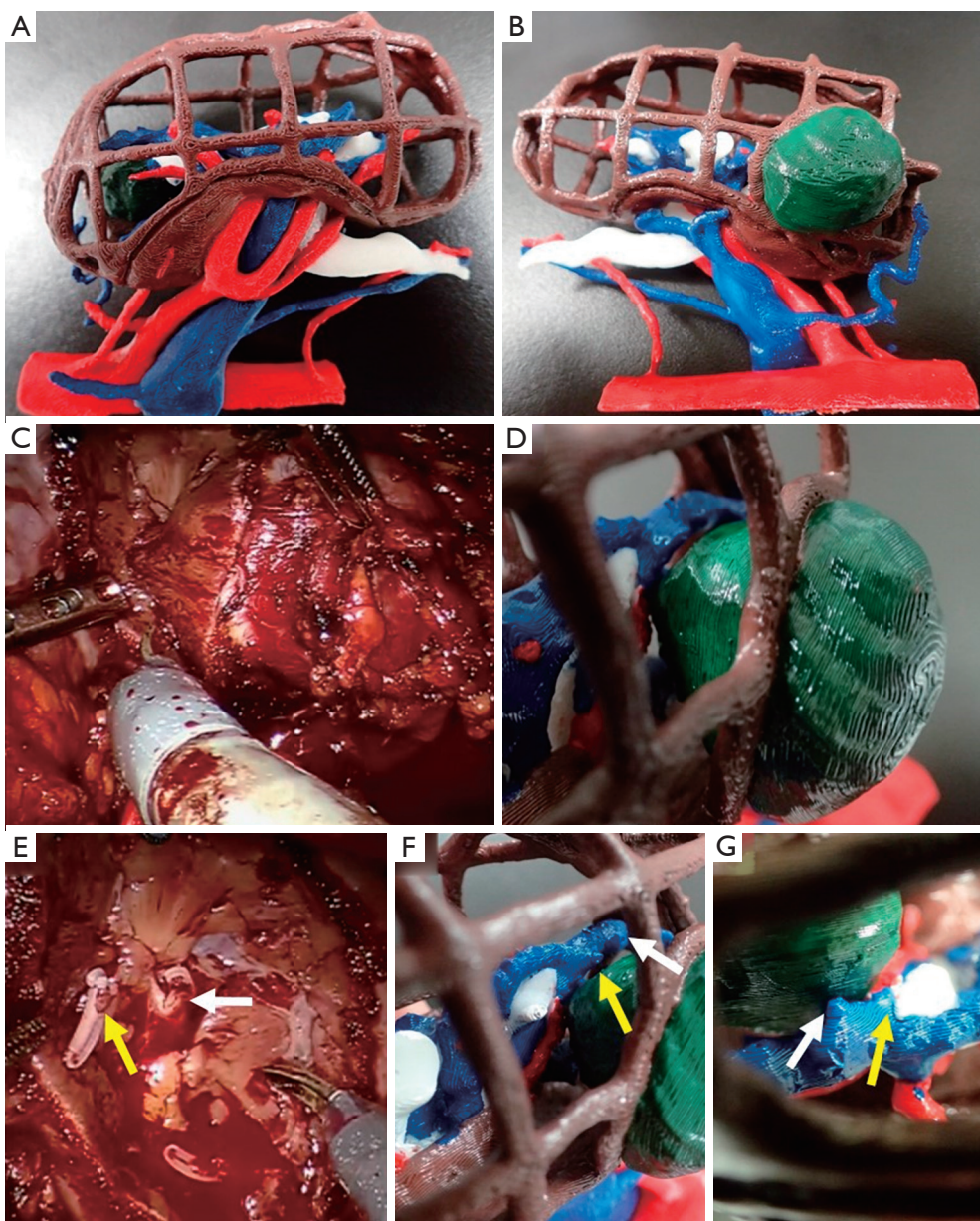
According to a previous article (7), each final printed model was actual size and had a square-block structure so that the inside could be seen (see *Figure 1* for representative images). In the model, arteriovenous arterioles could be reproduced up to the tertiary branches and the branching of the quadratic branches. For each model, the average weight was 115 g, printing time was 22±4.9 h, and creation time was 13±7.7 h. The average total cost of production was US \$10.

### Surgical technique and follow-up

All RAPN procedures were performed by a single surgeon with experience in more than 50 open partial nephrectomy and 60 robot-assisted radical prostatectomy procedures. RAPN was performed using the da Vinci Si<sup>®</sup> surgical system (Intuitive Surgical; Sunnyvale, CA) via the transperitoneal approach, except in cases with a posteriorly located tumor, which were treated via the retroperitoneal approach. The extra device arm was used for all patients, except for those with a small physique. Intraoperative ultrasound examinations were conducted using an ARIETTA 70 probe (Hitachi; Tokyo, Japan). Ultrasound images were observed as picture-on-picture images on the console screen using the TilePRO features of the da Vinci surgical system.

The 3D model was placed next to the console box, and the operator took the model off the console and examined it when needed. During surgery, the 3D model was used mainly to secure the renal artery and mark the tumor resection line by examining it from various angles in his hands. In particular, it was used to identify the location of the main trunk of the renal artery from the viewpoint of the renal vein and to confirm whether the secured renal artery was the main trunk. For entirely entophytic tumors, the tumor position was confirmed based on the 3D model, and the resection line was determined while confirming the positions of the renal calyx and inflowing blood vessels.

Complete arterial clamping was performed using a bulldog clip (Braun-Aesculap AG; Tuttlingen, Germany)



**Figure 1** A three-dimensional (3D)-square model. (A, B) Green, brown, red, blue, and white color indicate the renal tumor, kidney, artery, vein, and correcting system, respectively. (C, D) Determining the direction to cut with reference to the 3D model. (E, F) After tumor resection, two clips on the vein (yellow arrow and or white arrow). By using the 3D model, small vessels flowing into the tumor were recognized preoperatively. (G) Due to a grid shape 3D model, blood vessels and the tumor could be confirmed from the opposite side.

in all cases. No selective or renal vein clamping was performed. Renorrhaphy was performed in two layers (11): the first layer was sutured using a barbed suture (15-cm 3-0 V-Loc 180 with a half-circular 17-mm needle; Covidien, New Haven, CT) to achieve hemostasis and repair the collecting system, and the second layer was sutured using

a barbed suture (30-cm 2-0 V-Loc 180 with half-circular 37-mm needle; Covidien) to ensure capsular reconstruction. This procedure involved the early unclamp technique, in which the arterial clamp was removed after the first-layer suture was placed (12,13).

Enhanced computed tomography (CT) was performed



**Table 1** Clinical characteristics of the study sample and perioperative and oncological outcomes

Variable	Median (range)
Age (years)	61 (22–79)
Male/female	31/19
BMI (kg/m <sup>2</sup> )	24.5 (16.6–46.1)
Right-/left-sided	24/26
Tumor size (cm)	2.5 (0.9–3.8)
R.E.N.A.L. nephrometry score	
Low risk	22
Intermediate risk	24
High risk	4
Operative time (min)	212 (140–345)
Console time (min)	142 (64–285)
Warm ischemic time (min)	15.6 (7–39)
Blood loss (mL)	50 (5–300)
Tumor volume (g)	11.3 (1.0–44.5)
Transfusion	0
Conversion to radical nephrectomy	0
Histopathology	
Clear cell RCC	39
Papillary RCC	5
AML	3
Oncocytoma	2
Adrenocortical adenoma	1
Positive surgical margin	0
Complication	
Pseudoaneurysm	1
TRIFECTA	86.0%

Total patient sample: n=50; BMI, body mass index; RCC, renal cell carcinoma; AML, angiomyolipoma; TRIFECTA, absence of perioperative complications, positive surgical margins, and warm ischemia time of <25 min.

6–7 days after surgery in all patients except in those with renal dysfunction for screening of postoperative complications, such as pseudoaneurysm, hematoma, and urine leakage. Patients with pseudoaneurysms measuring <20 mm were followed up, and enhanced CT was performed 1 month later. Patients with pseudoaneurysms

≥20 mm underwent embolization if requested by the patient, and they were followed up 1 month later.

### Outcomes

Peri- and postoperative outcomes, including console time, WIT, blood loss, tumor volume, transfusion, and complications, were determined for each case. Postoperative complications were graded using the Clavien-Dindo classification (14). Renal function was assessed preoperatively and at 1, 3, 6, and 12 months postoperatively (POM1, 3, 6, and 12, respectively). Renal function was measured using eGFR, calculated using the current equation established for the Japanese population (15). TRIFECTA was defined as described previously (16).

After surgery, the surgeon examined the subjective benefit of the 3D model with a self-assessment form using a scoring system based on a 5-point scale (1= not beneficial; 5= highly beneficial).

### Statistical analysis

Fisher's exact test was used to assess categorical data. The Wilcoxon rank-sum test and Kruskal-Wallis test were used for non-parametric testing between groups. Repeated-measures analysis of variance was used to evaluate renal function. All statistical tests were two-sided, with a significance level of  $P < 0.05$ . The statistical analyses were performed using JMP v.14.0 software (SAS Institute; Cary, NC).

### Results

Characteristics of the 50 patients in the study sample, including age, sex, tumor side, BMI, tumor size, and R.E.N.A.L nephrometry scores, are presented in *Table 1*. The sample included 31 males and 19 females with a median age of 61 years (range, 22–79 years) and median BMI of 24.5 kg/m<sup>2</sup> (range, 16.6–46.1 kg/m<sup>2</sup>). Twenty-four and twenty-six cases involved right- and left-sided tumors, respectively. The median R.E.N.A.L nephrometry score was 7 (range, 4–10), and 22, 24, and 4 patients had low, intermediate- and high-risk scores, respectively. The retroperitoneal approach was performed in 12 cases (24%). The mean observation period was 20.5 months (range, 3–47 months).

*Table 1* summarizes the perioperative and oncological

**Table 2** Clinical characteristics and perioperative outcomes

	R.E.N.A.L nephrometry score			Surgeon's experience level		
	Low (n=22)	Intermediate/High (n=28)	P value	Early (cases 1–25)	Advanced (cases 26–50)	P value
Age (years)	65	60	0.8756	62	65	0.5090
Male/female	15/7	16/12	0.5595	15/10	16/9	1.0000
Right-/left-sided	6/16	18/10	0.0119	11/14	13/12	0.7775
BMI (kg/m <sup>2</sup> )	23.7	25.7	0.2570	24.1	25.2	0.6908
Tumor size (cm)	2.2	2.9	0.0670	2.2	2.8	0.1221
Tumor volume (g)	7.5	15.2	0.1348	7.6	15.0	0.0456
Warm ischemic time (min)	14.3	16.0	0.2294	15.6	14.9	0.9923
Console time (min)	146	138	0.2569	144	142	0.7051
Blood loss (mL)	50	50	0.6982	50	35	0.2689
TRIFECTA (%)	86.3	85.7	0.7181	84.0	88.0	1.000

BMI, body mass index; TRIFECTA, absence of perioperative complications, positive surgical margins, and warm ischemia time of <25 min.

outcomes of the 50 enrolled patients. The median WIT and console time were 15.6 min (range, 7–39 min) and 142 min (range, 64–285 min), respectively. The median blood loss was 50 mL (range, 5–300 mL). The median resected tumor mass was 11.3 g (range, 1.0–44.5 g). No cases required transfusion or conversion to radical nephrectomy.

Overall, 44 of the 50 patients were diagnosed with malignancies, including 39 with clear cell RCCs and 5 with papillary RCCs, and the remaining 6 patients were diagnosed with benign or other lesion types, including 3 with angiomyolipomas (AMLs), 2 with oncocytomas, and 1 with adrenocortical adenoma. No patients had positive surgical margins. Postoperative contrast-enhanced CT was evaluated in 47 cases except in 1 case of iodine allergy and 2 cases of renal dysfunction. Only one Clavien-Dindo grade >3 complication was reported—a pseudoaneurysm requiring embolism. Accordingly, the TRIFECTA achievement rate was 86.0%.

The surgeon's evaluation of the effectiveness of the 3D model in RAPN showed an average of 3.48 in all cases. The model was evaluated based on the surgeon's experience and R.E.N.A.L. nephrometry scores; there were no significant differences among the scores for the items "E", "N", "A", or "L".

Renal function was evaluated in 46 patients in whom renal function was confirmed at POM12. The median eGFR rates (mL/min/1.73 m<sup>2</sup>) at the preoperative, POM3, POM6, and POM12 timepoints were 74.5, 69.5, 69.5, and 66.5, respectively. The median percent changes in eGFR

at POM3, POM6, and POM12 relative to the preoperative value were –5.8%, –6.2%, and –5.9%, respectively. There were no significant differences in eGFR between the preoperative, POM3, POM6, and POM12 timepoints.

Table 2 compared clinical characteristics and perioperative outcomes according to R.E.N.A.L nephrometry scores and the surgeon's level of experience. Notably, the only significant difference involved blood loss volumes between the low- and intermediate-/high-risk R.E.N.A.L nephrometry score groups. There were no significant differences in clinical characteristics or perioperative results depending on the approach (transperitoneal or retroperitoneal).

## Discussion

As noted above, few reports have discussed the impacts of 3D-printed renal tumor models on the clinical outcomes of patients. In this study, therefore, we investigated the effects of such models on peri- and postoperative outcomes of RAPN. During a 2-year period, we created 3D models for 50 patients with T1a kidney tumors and achieved a TRIFECTA rate of 86.0%. Our 3D model can be created inexpensively using a commercially available 3D printer and contains the minimum information required for performing RAPN (7).

Surgeons may require experience with as many as 20 cases of robotic surgery before approaching an optimized console time, whereas more than 30 cases may be needed

**Table 3** TRIFECTA achievement rates in series of approximately 100 cases

	Buffi <i>et al.</i> (18) <sup>a</sup>	Veeratterapillay <i>et al.</i> (19)	Beauval <i>et al.</i> (20)	Castellucci <i>et al.</i> (21)	Bianchi <i>et al.</i> (22) <sup>a</sup>	Present study
Number	99	100	110	85	83	50
T1a (%)	N/A	N/A	74.5	0	78.3	100
T1b (%)	N/A	N/A	25.5	100	21.7	0
BMI (kg/m <sup>2</sup> )	N/A	27.3	26	26.6	26	24.5
Size (mm)	N/A	30.6	30	N/A	26	25
R.E.N.A.L. nephrometry score	N/A	6	6	N/A	N/A	7
WIT (min)	N/A	19.5	20	N/A	14	15.6
Complications (%)	10	15	24.5	17.6	22.9	2
Positive surgical margin (%)	7	11	10	11.8	3.6	0
TRIFECTA (%)	75.8	66	52.7	72.9	69.9	86.0

BMI, body mass index; WIT, warm ischemic time; TRIFECTA, absence of perioperative complications, positive surgical margins, and warm ischemia time of <25 min (<sup>a</sup><20 min).

to achieve a decrease in WIT (17). In a previous report of 99 cases by Buffi *et al.* (18), the TRIFECTA achievement rate improved to 66.7% during the initial 33 cases and to 87.9% in the latter 33 cases, suggesting an effect of surgical experience. In contrast, we observed no significant difference in the achievement of TRIFECTA when we compared the initial and latter 25 cases in our study, as shown in *Table 2*. We suggest that preoperatively, the 3D model can be taken many times to stereoscopically image tumor dissection as described above, hemostasis of blood vessels flowing to the dissection surface, and repair of the opened urinary tract. This prior realistic image training can compensate for a relative lack of surgical experience.

We further note that all cases in our sample had negative surgical margins and experienced minimal postoperative reductions in renal function. We attribute these good outcomes to the ability to set an appropriate resection line in each case according to the grid shape in this model while avoiding resection of the normal surplus renal parenchyma. Moreover, we did not observe any significant difference in the achievement of TRIFECTA when we stratified cases by R.E.N.A.L. nephrometry scores. Given the small number (n=4) of cases with high-risk R.E.N.A.L. nephrometry scores, we combined these together with the moderate-risk score cases. However, we note that TRIFECTA was achieved in all four high-risk cases. This result suggests that the 3D model enables the achievement of TRIFECTA even when a highly complex tumor is treated by a less-experienced surgeon.

In *Table 3*, we present the TRIFECTA achievement rates reported for previous series of approximately 100 cases (18–22). Previously, the hospital and surgeon volumes were identified as factors that strongly influenced the achievement of TRIFECTA during RAPN (23). However, we achieved comparable results with a surgeon without prior experience at a lower-volume institution. Our findings suggest that this 3D model is useful for institutions with a smaller number of cases and less-experienced surgeons.

The present study had several limitations. First, this was a retrospective study conducted at a single institution. Further large-scale prospective studies will be needed to confirm our outcomes. Second, the study featured a single-arm design and thus lacked a control arm without a 3D model. Third, urologists and radiological technologists were involved in the creation of the models used in this study. However, generalization would require a system that can be used by all technicians.

In conclusion, the present study demonstrated that the use of a simple and inexpensive 3D square-block-type kidney model during RAPN led to a high TRIFECTA achievement rate, regardless of the surgeon's experience level. Future studies involving larger numbers of cases and surgeons are warranted.

## Acknowledgments

*Funding:* None.

## Footnote

*Reporting Checklist:* The authors have completed the STROBE reporting checklist. Available at <http://dx.doi.org/10.21037/tau-20-927>

*Data Sharing Statement:* Available at <http://dx.doi.org/10.21037/tau-20-927>

*Peer Review File:* Available at <http://dx.doi.org/10.21037/tau-20-927>

*Conflicts of Interest:* All authors have completed the ICMJE uniform disclosure form (available at <http://dx.doi.org/10.21037/tau-20-927>). The authors have no conflicts of interest to declare.

*Ethical Statement:* The authors are accountable for all aspects of the work in ensuring that questions related to the accuracy or integrity of any part of the work are appropriately investigated and resolved. The study was conducted in accordance with the Declaration of Helsinki (as revised in 2013) and the Harmonized Tripartite Guideline for Good Clinical Practice from the International Conference on Harmonization. This study was reviewed and approved by the Institutional Research Review Boards of Jichi Medical University with an opt-out system (No. A19-097). Written informed consent was obtained from all patients.

*Open Access Statement:* This is an Open Access article distributed in accordance with the Creative Commons Attribution-NonCommercial-NoDerivs 4.0 International License (CC BY-NC-ND 4.0), which permits the non-commercial replication and distribution of the article with the strict proviso that no changes or edits are made and the original work is properly cited (including links to both the formal publication through the relevant DOI and the license). See: <https://creativecommons.org/licenses/by-nc-nd/4.0/>.

## References

- Lee H, Nguyen NH, Hwang SI, et al. Personalized 3D kidney model produced by rapid prototyping method and its usefulness in clinical applications. *Int Braz J Urol* 2018;44:952-7.
- Porpiglia F, Bertolo R, Checcucci E, et al. Development and validation of 3D printed virtual models for robot-assisted radical prostatectomy and partial nephrectomy: urologists' and patients' perception. *World J Urol* 2018;36:201-7.
- Maddox MM, Feibus A, Liu J, et al. 3D-printed soft-tissue physical models of renal malignancies for individualized surgical simulation: a feasibility study. *J Robot Surg* 2018;12:27-33.
- von Rundstedt FC, Scovell JM, Agrawal S, et al. Utility of patient-specific silicone renal models for planning and rehearsal of complex tumour resections prior to robot-assisted laparoscopic partial nephrectomy. *BJU Int* 2017;119:598-604.
- Bernhard JC, Isotani S, Matsugasumi T, et al. Personalized 3D printed model of kidney and tumor anatomy: a useful tool for patient education. *World J Urol* 2016;34:337-45.
- Ghazi AE, Teplitz BA. Role of 3D printing in surgical education for robotic urology procedures. *Transl Androl Urol* 2020;9:931-41.
- Yamazaki M, Takayama T, Fujisaki A, et al. Robot-assisted partial nephrectomy of initial cases using a 3D square-block type kidney model. *Translational Andrology and Urology* 2020;9:494-500.
- von Elm E, Altman DG, Egger M, et al. The Strengthening the Reporting of Observational Studies in Epidemiology (STROBE) statement: guidelines for reporting observational studies. *PLoS Med* 2007;4:e296.
- Vandenbroucke JP, von Elm E, Altman DG, et al. Strengthening the Reporting of Observational Studies in Epidemiology (STROBE): explanation and elaboration. *PLoS Med* 2007;4:e297.
- Kutikov A, Uzzo RG. The R.E.N.A.L. nephrometry score: a comprehensive standardized system for quantitating renal tumor size, location and depth. *J Urol* 2009;182:844-53.
- Kondo T, Takagi T, Morita S, et al. Early unclamping might reduce the risk of renal artery pseudoaneurysm after robot-assisted laparoscopic partial nephrectomy. *Int J Urol* 2015;22:1096-102.
- Baumert H, Ballaro A, Shah N, et al. Reducing warm ischaemia time during laparoscopic partial nephrectomy: a prospective comparison of two renal closure techniques. *Eur Urol* 2007;52:1164-9.
- Peyronnet B, Baumert H, Mathieu R, et al. Early unclamping technique during robot-assisted laparoscopic partial nephrectomy can minimise warm ischaemia without increasing morbidity. *BJU Int* 2014;114:741-7.
- Dindo D, Demartines N, Clavien PA. Classification of surgical complications: a new proposal with evaluation in

- a cohort of 6336 patients and results of a survey. *Ann Surg* 2004;240:205-13.
15. Matsuo S, Imai E, Horio M, et al. Revised equations for estimated GFR from serum creatinine in Japan. *Am J Kidney Dis* 2009;53:982-92.
  16. Hung AJ, Cai J, Simmons MN, et al. "Trifecta" in partial nephrectomy. *J Urol* 2013;189:36-42.
  17. Mottrie A, De Naeyer G, Schatteman P, et al. Impact of the learning curve on perioperative outcomes in patients who underwent robotic partial nephrectomy for parenchymal renal tumours. *Eur Urol* 2010;58:127-32.
  18. Buffi N, Lista G, Larcher A, et al. Margin, ischemia, and complications (MIC) score in partial nephrectomy: a new system for evaluating achievement of optimal outcomes in nephron-sparing surgery. *Eur Urol* 2012;62:617-8.
  19. Veeratterapillay R, Addla SK, Jelley C, et al. Early surgical outcomes and oncological results of robot-assisted partial nephrectomy: a multicentre study. *BJU Int* 2017;120:550-5.
  20. Beauval JB, Peyronnet B, Benoit T, et al. Long-term oncological outcomes after robotic partial nephrectomy for renal cell carcinoma: a prospective multicentre study. *World J Urol* 2018;36:897-904.
  21. Castellucci R, Primiceri G, Castellan P, et al. Trifecta and Pentafecta Rates After Robotic Assisted Partial Nephrectomy: Comparative Study of Patients with Renal Masses <4 and >/=4 cm. *J Laparoendosc Adv Surg Tech A* 2018;28:799-803.
  22. Bianchi L, Schiavina R, Borghesi M, et al. Which patients with clinical localized renal mass would achieve the trifecta after partial nephrectomy? The impact of surgical technique. *Minerva Urol Nefrol* 2020;72:339-49.
  23. Peyronnet B, Tondut L, Bernhard JC, et al. Impact of hospital volume and surgeon volume on robot-assisted partial nephrectomy outcomes: a multicentre study. *BJU Int* 2018;121:916-22.

**Cite this article as:** Fujisaki A, Takayama T, Yamazaki M, Kamimura T, Katano S, Komatsubara M, Kamei J, Sugihara T, Ando S, Fujimura T. Utilization of a three-dimensional printed kidney model for favorable TRIFECTA achievement in early experience of robot-assisted partial nephrectomy. *Transl Androl Urol* 2020;9(6):2697-2704. doi: 10.21037/tau-20-927