

## Case Report

# Managing a grossly comminuted and infected mandibular fracture using a maxillary extra-oral distractor as stabilizing agent: A clinical case report

Ding Ming Chao<sup>a</sup>, Shi Jin<sup>a</sup>, Kalu Singh Khatri<sup>b</sup>, Zhao Jin Long<sup>a</sup>, Tian Lei<sup>a</sup>, He Lisheng<sup>a,\*</sup>

<sup>a</sup> Department of Oral and Maxillofacial Reconstruction, Fourth Military Medical University, China

<sup>b</sup> Department of Oral and Maxillofacial Reconstruction, Jiamusi University, China

## ARTICLE INFO

*Article history:*

Accepted 2 January 2017

Available online 18 March 2017

*Keywords:*

Mandibular fracture  
Maxillary distractor  
Infection

## ABSTRACT

Facial fracture management dates as early as Hippocratic era. Comminuted mandibular fractures are one of the challenging clinical condition requiring high surgical expertise to achieve a good functional and esthetic outcome. In presence of infection and other facial fractures managing comminuted mandibular fracture becomes more challenging.

Here we present a case of grossly comminuted and infected mandibular fracture with delayed presentation managed by using maxillary distractor as stabilizing agent. Using a maxillary distractor for managing a fractured mandible has been seldom reported in literature. Current case report gives idea to practicing clinician about the possibility of treatment beyond the established principles.

© 2017 Published by Elsevier Ltd. This is an open access article under the CC BY-NC-ND license (<http://creativecommons.org/licenses/by-nc-nd/4.0/>).

## Introduction

History of facial fracture treatments date back to Hippocratic era [1,2]. Comminuted mandibular fractures are distinct clinical entity requiring higher surgical expertise and knowledge for better treatment outcomes [3,4]. Generally long standing fractures with infection and multiple fractures are difficult to manage. Here we present a case of grossly infected comminuted mandibular fracture with a delayed presentation to oral and maxillofacial department. (See [Figs. 1 and 2.](#))

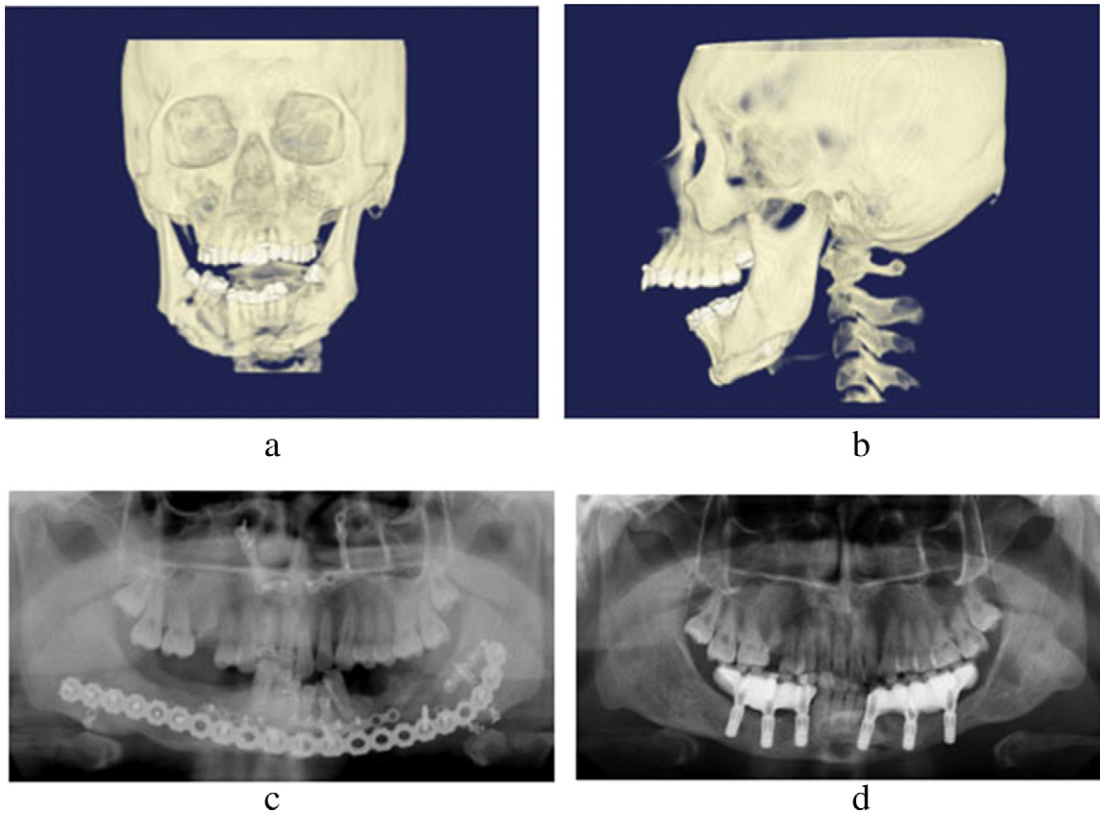
## Case report

17 years old female patient reported to our unit with history of one month old fall injury in October 2011. Patient had jumped from 5 story building as suicidal attempt sustaining multiple injuries and was treated at emergency department of affiliated hospital of Technology University of Henan. She had undergone multiple orthopedic surgeries for fractured limbs and routine debridement of facial injuries at above mentioned institution. Previous hospital records showed that she had not sustained significant cranial injuries but had suffered multiple facial fractures and was not treated for the facial fractures. She had reported to our department seeking treatment for facial fractures.

On clinical examination facial asymmetry with swollen right cheek and intraoral open wound with necrotic bone piece and foul smell were found. All posterior mandibular teeth were lost. Cervical lymph nodes were palpable and tender. CT scan revealed multiple fractures in mandible and maxilla with gross swelling around submandibular and submental region. Clinical and

\* Corresponding author.

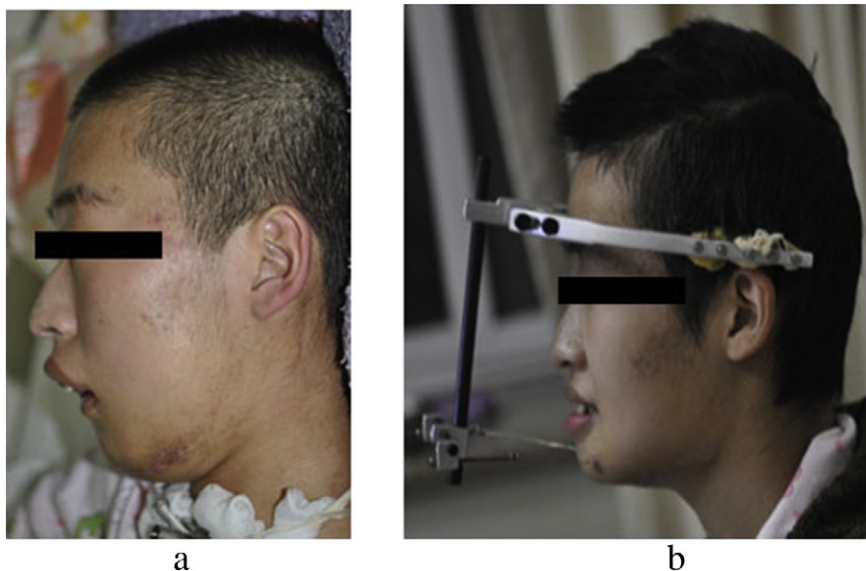
E-mail address: [lishengh@fmmu.edu.cn](mailto:lishengh@fmmu.edu.cn) (H. Lisheng).



**Fig. 1.** Pre-operative 3 dimensional CT scan revealing multiple fractures with complete loss of anatomy. (a) Anterior view and (b) lateral view. Post-operative OPG x-rays showing patient occlusion. (c) Immediately after distractor removal shows a satisfactory fracture reduction and good healing. (d) After complete prosthetic rehabilitation shows a good occlusal and anatomic integrity.

radiological examination showed that there was complete loss of anatomical integrity of mandibular bone with multiple fracture lines crossing each other and with preserved condyles bilaterally.

Surgical debridement of wound and open reduction of fractured bones under general anesthesia were planned. We easily reduced the fractured bone but stability of reduced bone was not achievable due to multiple fractures and possibility of IMF was



**Fig. 2.** Pre-operative facial profile view of the patient (a) and post-operative profile view with distractor after one and a half month of surgery (b).

ruled out due to multiple fractures along mandibular alveolar process and maxilla and loss of mandibular posterior teeth. Finally maxillary distractor was used to stabilize reduced mandibular fracture. After one and half month maxillary distractor was removed under local anesthesia. 9 months after the first surgery, second surgery under general anesthesia was done for plate removal but we could not remove one of the mini plates due to non-union at one fractured site. Non-healed fractured line was debrided and reduced and fixed with mini plate again. 7 months after second surgery, third surgery was done for remaining plate removal. Surgical exploration of fractured site revealed well healed fracture with acceptable anatomical contour and occlusal relationships. 4 months after removal of all plates fourth surgery was done for implant placement at 33, 35, 37, 43, 45 and 47. Implants were loaded after 6 months. Patient's facial profile, functional ability of mandible and occlusal relationships are satisfactory till 2 years of follow up in December 2015.

## Discussions

Open reduction and internal fixation of fractured facial bones is well established treatment modality indicated for fractures non-reducible by closed reduction techniques. Comminuted mandibular fractures are best treated by ORIF with load bearing osteosynthesis [4,5].

Similar treatment protocol was followed in current case too. Fractures were reduced after surgical exploration via intra-oral buccal sulcus incision. Intra-oral buccal sulcus incision is the most cosmetic surgical approach to mandible [6,7]. But immobilizing the reduced fracture segment was highly challenging due to complete loss of mandibular anatomy and multiple fractures in maxilla too. Exact anatomic reduction of fractures cannot yield satisfactory outcome if the reduced segment is not immobilized during the healing period. Conventionally various methods of immobilization have been used in management of mandibular fractures. Most of the conventional method employ immobilization techniques by attaching fractured mandible with stable cranial structure like maxilla, zygoma and others [1,8,9]. In current case intraoral immobilization techniques were ruled out due to multiple fractures in mandible and maxilla, so extra-oral immobilization technique was used. This case was particularly challenging because of need of extra-oral immobilization device which could counter the downward and inward pull of mandibular segments by the action of suprahyoid muscles. Owing to huge force generated by suprahyoid muscles we decided to use extra-oral maxillary distractor as stabilizing agent for the reduced fractured segment.

Maxillary distractor is an extra-oral equipment employed in distraction osteogenesis of Maxilla and mid face in cases of maxillary and/or mid face retrusion due to varieties of clinico-pathologic conditions [10–12]. While reviewing scientific literatures we seldom came across any literature stating use of maxillary distractor in management of fractured mandible. It is probably first reported case of Mandibular fracture treated by Maxillary distractor. In distraction osteogenesis maxillary distractor maintains the position of maxilla during consolidation phase without exerting further force on fractured segment [11]. We utilized the same principle and used maxillary distractor at neutral position to maintain the reduced position mandible. We stabilized the reduced mandible in its position with distractor for 45 days.

We had to repeat ORIF at one of the fractured sites due to non-union after 9 months when patient was undergoing plate removal. It is not uncommon to see non-union or mal-union in cases of comminuted fractures. Finally we achieved complete healing of the fractured sites after second surgery and all plates were removed during third surgery. Removal of plates is not necessary without any specific indication and here in this case it was necessary to remove all plates to make space for implant placement for prosthetic rehabilitation of the patient. Patient had highly encouraging esthetic and functional outcome at completion of treatment and till two years follow up in December 2015.

## Conclusions

Surgical treatment of comminuted mandibular fracture is highly challenging as demand of functional and esthetic stability is very high. Using maxillary distractor at mandibular fractured site can provide sufficient extra-oral immobilization.

## References

- [1] J.P. Hamill, et al., The treatment of fractures of the mandible, *Calif. Med.* 101 (1964) 184–187.
- [2] R. Mukerji, G. Mukerji, M. McGurk, Mandibular fractures: historical perspective, *Br. J. Oral Maxillofac. Surg.* 44 (2006) 222–228.
- [3] L.H. Hollier Jr., et al., Facial trauma: general principles of management, *J. Craniofac. Surg.* 21 (2010) 1051–1053.
- [4] J.S. Schenkel, et al., Outcome of comminuted mandibular fracture repair using an intraoral approach for osteosynthesis, *J. Craniofac. Surg.* 25 (2014) 2033–2037.
- [5] B.R. Chrcanovic, Open versus closed reduction: comminuted mandibular fractures, *Oral Maxillofac. Surg.* 17 (2013) 95–104.
- [6] D.H. Stacey, et al., Management of mandible fractures, *Plast. Reconstr. Surg.* 117 (2006) 48e–60e.
- [7] J.C. Klein, Intraoral open reduction, *Arch. Otolaryngol.* 103 (1977) 645–647.
- [8] R.H. Goodday, Management of fractures of the mandibular body and symphysis, *Oral Maxillofac. Surg. Clin. North Am.* 25 (2013) 601–616.
- [9] H.G. Luhr, Management of concomitant fractures in facial injuries, *Langenbecks Arch. Chir.* 372 (1987) 687–695.
- [10] A.A. Efunkeya, et al., Maxillomandibular distraction osteogenesis, *J. Craniomaxillofac. Surg.* 25 (2014) 1787–1792.
- [11] S.S. Natu, et al., The biology of distraction osteogenesis for correction of mandibular and craniomaxillofacial defects: a review, *Dent. Res. J. (Isfahan)* 11 (2014) 16–26.
- [12] G. Swennen, et al., Craniofacial distraction osteogenesis: a review of the literature: part 1: clinical studies, *Int. J. Oral Maxillofac. Surg.* 30 (2001) 89–103.