

## Original Article

# The arcade of Struthers: An anatomical study with potential neurosurgical significance

R. Shane Tubbs, Aman Deep, Mohammadali M. Shoja<sup>1</sup>, Martin M. Mortazavi, Marios Loukas<sup>2</sup>, Aaron A. Cohen-Gadol<sup>3</sup>

Section of Pediatric Neurosurgery, Children's Hospital, Birmingham, AL, <sup>1</sup>Neuroscience Research Center, Tabriz University of Medical Sciences, Tabriz, Iran, <sup>2</sup>Department of Anatomical Sciences, St. George's University, Grenada, <sup>3</sup>Goodman Campbell Brain and Spine, Indiana University Department of Neurological Surgery, Indianapolis, IN

E-mail: R. Shane Tubbs - [Shane.Tubbs@chsys.org](mailto:Shane.Tubbs@chsys.org); Aman Deep - [Aman.Deep@chsys.org](mailto:Aman.Deep@chsys.org); Mohammadali M. Shoja - [shoja.m@gmail.com](mailto:shoja.m@gmail.com); Martin M. Mortazavi - [Martin.Mortazavi@chsys.org](mailto:Martin.Mortazavi@chsys.org); Marios Loukas - [cdsg2000@yahoo.com](mailto:cdsg2000@yahoo.com); \*Aaron A. Cohen-Gadol - [acohenmd@gmail.com](mailto:acohenmd@gmail.com)  
\*Corresponding author

Received: 5 October 11

Accepted: 23 November 11

Published: 26 December 11

**This article may be cited as:**

Tubbs RS, Deep A, Shoja MM, Mortazavi MM, Loukas M, Cohen-Gadol AA. The arcade of Struthers: An anatomical study with potential neurosurgical significance. *Surg Neurol Int* 2011;2:184.

Available FREE in open access from: <http://www.surgicalneurologyint.com/text.asp?2011/2/1/184/91139>

Copyright: © 2011 Tubbs RS. This is an open-access article distributed under the terms of the Creative Commons Attribution License, which permits unrestricted use, distribution, and reproduction in any medium, provided the original author and source are credited.

## Abstract

**Background:** Significant controversy exists regarding the existence of the so-called arcade of Struthers and whether this structure is involved in some cases of proximal ulnar nerve entrapment. Therefore, the aim of the present study was to further elucidate this anatomy.

**Methods:** Fifteen cadavers (30 sides) underwent dissection of the medial arm with special attention to the course of the ulnar nerve and its relationships to the soft tissues of this region.

**Results:** We identified a thickening in the inferior medial arm that crosses the ulnar nerve and is consistent with the so-called arcade of Struthers in 86.7% of sides. On 57.7% of the sides, the arcade was found to be due to a thickening of the brachial fascia and was classified as a type I arcade. On 19.2% of the sides, the arcade was due to the internal brachial ligament and these were classified as type II arcades. On 23.1% of the sides, the arcade was due to a thickened medial intermuscular septum and these were classified as type III arcades. The mean length of the arcade was 4.3 cm and the distal end of the arcade was, on average, 6.8 cm above the medial epicondyle. Although the presence of an arcade of Struthers was slightly more common in female specimens, this did not reach statistical significance. However, arcades were found more often on right side ( $P < 0.001$ ).

**Conclusions:** Based on our findings, the arcade of Struthers is an anatomical band of connective tissue in the medial distal arm that crosses the ulnar nerve. This structure was found in the majority of our specimens and may need to be evaluated in proximal ulnar neuropathies. We believe that past studies that have not observed the arcade and past studies with varied findings are due to the various definitions used for this anatomical structure. Using the classification system as demonstrated in the present study may make future communications regarding the arcade of Struthers more exact.

**Key Words:** Anatomy, entrapment, neurosurgery, peripheral nerve, ulnar nerve

**Access this article online**

Website:  
[www.surgicalneurologyint.com](http://www.surgicalneurologyint.com)

DOI:  
10.4103/2152-7806.91139

Quick Response Code:



## INTRODUCTION

Ulnar nerve entrapment constitutes the second most common nerve entrapment in the upper limb after median nerve entrapment in the carpal tunnel. The ulnar nerve originates from the medial cord of the brachial plexus and transmits fibers from C8 and T1 and sometimes C7 roots.<sup>[4]</sup> Along its pathway, the ulnar nerve may become entrapped at various sites,<sup>[8]</sup> including: 1) at the arcade of Struthers, 2) just proximal to the medial epicondyle, 3) in the groove between the olecranon process and medial epicondyle, 4) in the tunnel between the humeral and the ulnar heads of the flexor carpi ulnaris muscle described as the cubital tunnel,<sup>[9]</sup> 5) at its exit from the flexor carpi ulnaris in the forearm, and 6) at the wrist, where it can be compressed during its course through Guyon's canal.<sup>[13]</sup> Classically, patients with entrapment of the ulnar nerve will present with intermittent paresthesia and numbness of the fifth and medial half of the fourth digits and, depending on the site of compression, weakness of the flexor carpi ulnaris and ulnar half of the flexor digitorum profundus. During its passage from the anterior to posterior muscle compartments of the arm, the ulnar nerve may be associated with the so-called arcade of Struthers, although the presence of this structure is debatable.<sup>[6]</sup> Some have described this arcade as having a roof that faces medially and formed by a thickening of deep investing fascia of the arm, by superficial muscle fibers of the medial head of triceps and by the attachment of the medial intermuscular septum (MIS).<sup>[17]</sup> The MIS forms the anterior border and the humerus covered by deep fibers of the medial head of the triceps brachii muscle forms the lateral border of the arcade.<sup>[21]</sup>

With such controversy in the literature regarding the anatomy and even the presence of the arcade of Struthers, the aim of the present study was to further elucidate this morphology and its potential role in compression neuropathies of the ulnar nerve.

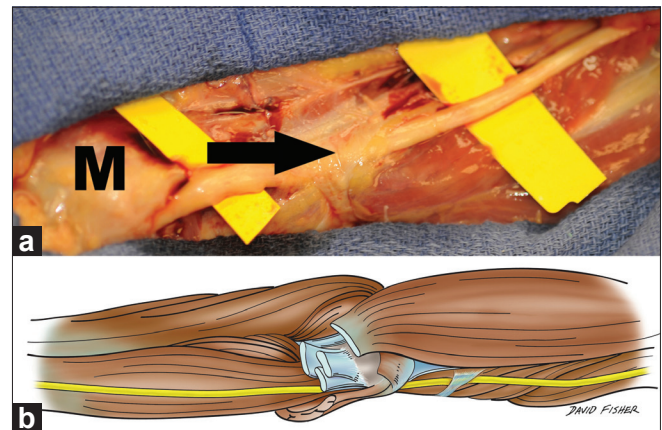
## MATERIALS AND METHODS

Fifteen adult cadavers (30 sides) underwent dissection of the medial arm with special attention given to the course of the ulnar nerve and its relationships to the soft tissues of this region. Nine specimens were from females and six were from males, with an age range at death of 39–85 years (mean 70 years). Ten specimens were formalin fixed and five specimens were unembalmed. With the cadavers in the supine position, forearms supinated, and the upper limbs abducted to 90°, the whole of the overlying skin of the medial arm was removed. The deeper fasciae were carefully dissected, observing for the relationship between these tissues and the ulnar nerve. If the so-called arcade of Struthers was observed, measurements and

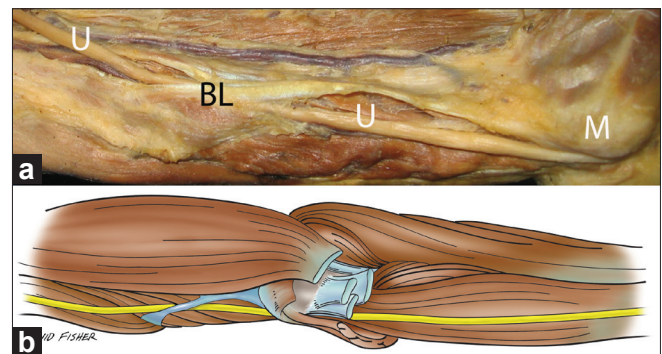
relationships of its anatomy were documented. Statistical analysis between sides and genders was performed using Statistica for Windows, with significance set at  $P < 0.05$ .

## RESULTS

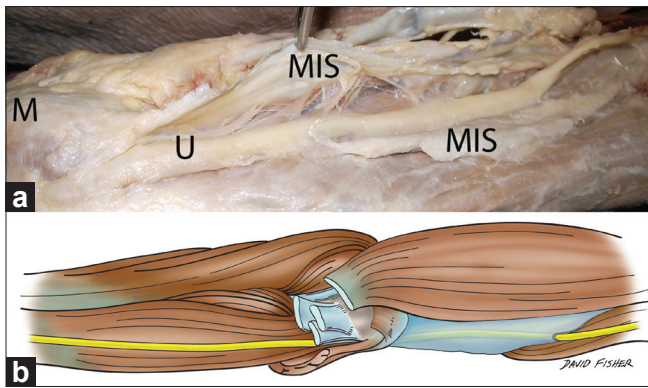
We identified a thickening in the inferior medial arm that crossed the ulnar nerve and was consistent with the so-called arcade of Struthers in 86.7% (26 of 30) of sides. For the remaining sides (13.3%), the ulnar nerve coursed through a non-thickened MIS. On 15 sides (57.7%), the arcade was found to be due to a thickening of the brachial fascia, and we classified these as type I arcades [Figure 1a and b]. On five sides (19.2%), the arcade was due to the internal brachial ligament (BL), and these were classified as type II arcades [Figure 2a and b]. On six sides (23.1%), the arcade was due to a thickened MIS, and these were classified as type III arcades [Figure 3a and b]. The length (from the ulnar nerve entrance to the ulnar nerve exit) of the arcade ranged from 3 to 5.5 cm [mean 4.3 cm, standard deviation (SD) 2.6], and the



**Figure 1: (a) Right upper limb showing the ulnar nerve (traveling over yellow cards) traversing a thickening of brachial fascia. This represents a type I arcade. Note the medial epicondyle (M). (b) Schematic drawing of the type I arcade of the right upper limb**



**Figure 2: (a) Left-sided specimen noting the ulnar nerve (U) traveling through the internal brachial ligament (BL). Note the medial epicondyle (M). This represents a type II arcade. (b) Schematic drawing of the type II arcade of the left upper limb**



**Figure 3: (a) Right-sided specimen noting the ulnar nerve (U) traveling through the medial intermuscular septum (MIS) that has been opened. For reference, note the medial epicondyle (M). This represents a type III arcade. (b) Schematic drawing of the type III arcade of the right upper limb**

distal end of the arcade was, on average, 6.8 cm (range 4.8–10.5 cm, SD 1.95) above the medial epicondyle of the humerus. No pathology or past surgical incisions were noted in the areas dissected and no specimen had a known ulnar nerve neuropathy. Although the presence of an arcade of Struthers was slightly more common in specimens from females, this did not reach statistical significance. However, arcades were found more often on the right side (right side in 17 and left side in 9; 65.4% and 34.6%, respectively) and this did reach statistical significance ( $P < 0.001$ ).

## DISCUSSION

The arcade of Struthers should not be confused with the ligament of Struthers first described by Sir John Struthers in 1854 as a fibrous band that extends from an anomalous supracondylar spur to the medial epicondyle of the humerus and that may compress the median nerve.<sup>[22,23]</sup> Interestingly, Struthers never mentioned an “arcade” in his writings,<sup>[16]</sup> and such a structure was only later attributed to him in 1973 by Kane *et al.*,<sup>[14]</sup> who identified this structure in 70% of their cadaveric dissections, and these were located 8 cm proximal to the medial epicondyle of the humerus. In 1986, Amadio<sup>[2]</sup> identified an arcade of Struthers in 100% of 20 cadaveric arm dissections and localized this structure 6–10 cm proximal to the medial epicondyle. Al-Qattan and Murray<sup>[1]</sup> in their anatomical studies reported the existence of an arcade of Struthers in 68% of cadaveric specimens (17 of 25 specimens), which is similar to the 70% incidence reported by Kane *et al.*<sup>[14]</sup> and the 67% incidence reported by Gonzalez *et al.*<sup>[12]</sup> Siqueira *et al.*<sup>[20]</sup> reported the presence of this structure in 13.5% of dissected cadavers (8 of 60 specimens) and von Schroeder and Scheker<sup>[24]</sup> identified this arcade in all of their 11 specimens.

However, Dellon<sup>[7]</sup> did not encounter an arcade of Struthers in an evaluation of 300 cubital tunnel surgeries and postulated, “In the present anatomical study, a band that might be interpreted as an ‘arcade of Struthers’ was not identified except as might be construed as the fascial condensations from the medial head of the triceps to the medial intermuscular septum.” In support of the findings of Dellon,<sup>[7]</sup> Bartels *et al.*<sup>[3]</sup> did not identify an arcade of Struthers in cadaveric dissections of 10 specimens and favored abandoning this term. Recently, Won *et al.*,<sup>[26]</sup> in a cadaveric study, found that in up to 43% of their specimens, the ulnar nerve did not pierce the MIS in its pathway from the proximal arm to the medial epicondyle.

The history of operative treatment for ulnar nerve entrapment caused by the arcade of Struthers dates back to the description by Kane *et al.*,<sup>[14]</sup> who suggested the release of this structure during anterior transposition of the ulnar nerve. In 1976, Spinner and Kaplan<sup>[21]</sup> wrote that following anterior transposition of the nerve at the elbow, the arcade of Struthers can cause ulnar neuropathy due to surgically induced entrapment because the nerve can remain tethered proximally. They concluded that the arcade should be transected during anterior transposition of the ulnar nerve to prevent recurrent traumatic neuritis. Al-Qattan and Murray<sup>[1]</sup> suggested:

“If the roof of the arcade has multiple ligaments, simple release of the arcade may not be enough. It is recommended that the ligaments, which pass deep to the ulnar nerve, including the internal brachial ligament, should be released at their insertions. This can be done without extending the skin incision, since the insertion of such ligaments is located at the same level as the arcade. If the ulnar nerve is found buried in the medial head of the triceps, the overlying muscular roof should be incised. Proximal extension of the skin incision may be needed to mobilize the ulnar nerve fully from the deep groove in the muscle.”

Regarding the internal BL, arcade of Struthers and MIS, Won *et al.*<sup>[26]</sup> stated, “The anterior border of the slit (site that the ulnar nerve pierces the septum) was the tendon connecting the medial intermuscular septum to the anterior portion of the medial head of the triceps brachii muscle, and its posterior border was the internal brachial ligament. The anterior border of the slit differed from the arcade of Struthers, which is a tendinous structure connecting the medial head of the triceps brachii muscle to the medial intermuscular septum, because the former was anterior to the ulnar nerve while the latter was posterior to the nerve.”

The arcade was described as a fibrous canal with an average length of 5.7 cm.<sup>[1]</sup> The structural components of the canal consisted of the fibrous tissue of the intermuscular septum, the internal BL, and the deep fascia and epimysium of the triceps brachii muscle.<sup>[1]</sup> In

1992, Ochiai *et al.*<sup>[18,19]</sup> reported ulnar nerve entrapment neuropathy by an arcade of Struthers, and in 2000, these authors reported an additional two cases verified electrophysiologically. Kim *et al.*<sup>[15]</sup> more recently reported two cases of an entrapped ulnar nerve at the arcade of Struthers that were successfully treated.

Some authors have also implicated the arcade of Struthers in cases of failed cubital tunnel surgery.<sup>[5,10,11]</sup> Additionally, reports have found severe kinking of the ulnar nerve at the arcade of Struthers following decompression of the cubital tunnel.<sup>[10]</sup> In this regard, some authors have advocated a more proximal incision for cubital tunnel release so that tethering at the arcade of Struthers is evaluated.<sup>[1,25]</sup>

Regarding the classical description of the arcade of Struthers,<sup>[21]</sup> our type II most coincides with this anatomy, which is consistent with the so-called internal BL and was found in 19.2% of sides.

## CONCLUSIONS

We believe that an arcade of Struthers as described by multiple authors does exist, and based on our study, it exists in the majority of individuals. However, why some individuals become symptomatic and others do not is yet to be elucidated. As the ulnar nerve traverses this structure, this area may necessitate surgical evaluation for proximal ulnar neuropathies. This later notion is supported by case reports of patients with ulnar nerve palsy that improved following transection of this connective tissue. On the majority of sides, the arcade was found to be due to a thickening of the brachial fascia. Other arcades were formed by the internal BL and MIS. Each of these structures could be easily evaluated with a more proximal skin incision and exploration for routine decompressive procedures of the ulnar nerve at the medial epicondyle. Based on our study, this could be up to almost 20 cm proximal to the medial epicondyle. Therefore, in order to better localize the site of compression, adjuncts to surgical decompression could include electrophysiology and ultrasound.

## REFERENCES

1. Al-Qattan MM, Murray KA. The arcade of Struthers: An anatomical study. *J Hand Surg Br* 1991;16:311-4.
2. Amadio PC. Anatomical basis for a technique of ulnar nerve transposition.

3. Surg Radiol Anat 1986;8:155-61.
3. Bartels RH, Grotenhuis JA, Kaver JM. The arcade of Struthers: An anatomical study. *Acta Neurochir (Wien)* 2003;145:295-300.
4. Bozentka DJ. Cubital tunnel syndrome pathophysiology. *Clin Orthop* 1998;351:90-4.
5. Caputo AE, Watson HK. Subcutaneous anterior transposition of the ulnar nerve for failed decompression of cubital tunnel syndrome. *J Hand Surg* 2000;25:544-51.
6. De Jesus R, Dellon AL. Historic origin of the "Arcade of Struthers." *J Hand Surg Am* 2003;28:528-31.
7. Dellon A. Musculotendinous variations about the medial humeral epicondyle. *J Hand Surg Br* 1986;11:175-81.
8. Dinh PT, Gupta R. Subtotal medial epicondylectomy as a surgical option for treatment of cubital tunnel syndrome. *Tech Hand Up Extrem Surg* 2005;9:52-9.
9. Feindel W, Stratford J. The role of the cubital tunnel in tardy ulnar palsy. *Can J Surg* 1958;1:287-300.
10. Filippi R, Charalampaki P, Reisch R, Koch D, Grunert P. Recurrent cubital tunnel syndrome: Etiology and treatment. *Minim Invasive Neurosurg* 2001;44:197-201.
11. Gabel GT, Amadio PC. Reoperation for failed decompression of the ulnar nerve in the region of the elbow. *J Bone Joint Surg* 1990;72:213-9.
12. Gonzalez MH, Lotfi P, Bendre A, Mandelbroyt Y, Lieska N. The ulnar nerve at the elbow and its local branching: An anatomic study. *J Hand Surg* 2001;26:142-4.
13. Jose RM, Bragg T, Srivastava S. Ulnar nerve compression in Guyon's canal in the presence of a tortuous ulnar artery. *J Hand Surg Br* 2006;31:200-2.
14. Kane E, Kaplan EB, Spinner M. Observations of the course of the ulnar nerve in the arm. *Ann Chir* 1973;27:487-96.
15. Kim PT, Jeon IH, Min WK, Kim JS. High ulnar nerve palsy by the arcade of Struthers in the elbow: Report of 2 cases. *J Korean Orthop Assoc* 2005;40:372-5.
16. Loukas M, Pennell C, Tubbs RS, Cohen-Gadol AA. Sir John Struthers (1823-1899) and his ligament and arcade. *Neurosurgery* 2010;66:1170-3.
17. Nakajima M, Ono N, Kojima T, Kusunose K. Ulnar entrapment neuropathy along the medial intermuscular septum in the midarm. *Muscle Nerve* 2009;39:707-10.
18. Ochiai N, Hayashi T, Ninomiya S. High ulnar nerve palsy caused by the arcade of Struthers. *J Hand Surg Br* 1992;17:629-31.
19. Ochiai N, Honmo J, Tsujino A, Nisiura Y. Electrodiagnosis in entrapment neuropathy by the arcade of Struthers. *Clin Orthop Relat Res* 2000;378:129-35.
20. Siqueira MG, Martins RS. The controversial arcade of Struthers. *Surg Neurol* 2005;64:474.
21. Spinner M, Kaplan EB. The relationship of the ulnar nerve to the medial intermuscular septum in the arm and its clinical significance. *Hand* 1976;8:239-42.
22. Struthers J. On some points in the abnormal anatomy of the arm. *Br Foreign Med Chir Rev* 1854;14:170-9.
23. Struthers J. On a peculiarity of the humerus and humeral artery. *Mon J Med Sci* 1848;8:264-7.
24. Von Schroeder HP, Scheker LR. Redefining the "arcade of Struthers." *J Hand Surg Am* 2003;28:1018-21.
25. Wehrli L, Oberlin C. The internal brachial ligament versus the arcade of Struthers: An anatomical study. *Plast Reconstr Surg* 2005;115:471-7.
26. Won HS, Han SH, Oh CS, Chung IH, Kim SM, Lim SY. Topographic relationship between the medial intermuscular septum and the ulnar nerve in the upper arm. *J Neurosurg* 2001;114:1534-7.